

Three Simple Rules in Pectoral Muscle's Trigger Point Treatment, Which May Be a Cause of Chest Pain: Position, Palpation, and Perpendicular Needling

To the Editor: Chest pain is a cause for a large proportion of admissions to the hospital.¹ Almost half of the applications to primary health care institutions with chest pain originate from the musculoskeletal system.² Myofascial pain syndrome is an overlooked diagnosis in the etiology of chest pain. The literature reports that myofascial pain syndrome of the pectoral muscles, serratus anterior, and scalene muscles may be the cause of chest pain.³ The spread pattern of pain described by the patient may help in the diagnosis. It is also necessary to consider that these pathologies can occur at the same time in a patient. Myofascial pain syndrome of the pectoral muscles exhibits a pain pattern that radiates in the anterior shoulder and the ulnar nerve trace, as well as the chest.⁴ In scalene muscles, it displays a spreading pattern along the lateral and posterior shoulder region and the radial nerve trace.⁵ In the serratus anterior muscle, the pain can be detected along the midaxillary region and the ulnar nerve trace, in addition to the chest.³ Common treatment methods include invasive approaches such as dry needling, lidocaine injection, and nerve block.

In our outpatient practice, 3 simple rules are mentioned in the dry-needling approach to the pectoralis major muscle that we practice frequently. Pectoral muscles are described in the literature as “pseudoangina muscle.” The first rule is palpation, the second rule is position (Figure 1A), and the third rule is perpendicular approach (Figure 1B).⁴

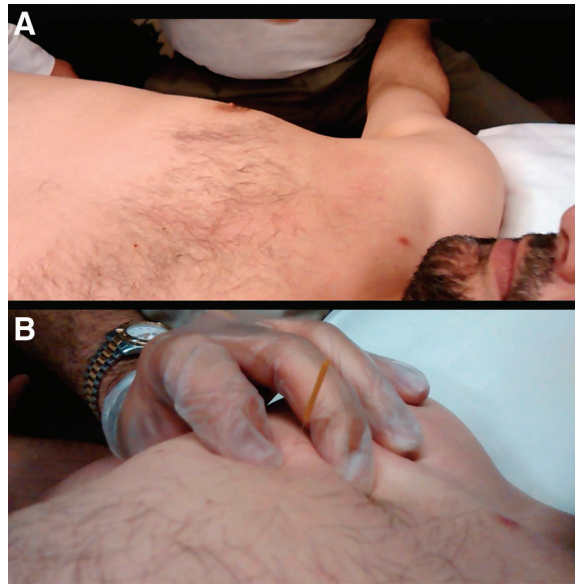
Rule 1. Palpation should be performed according to the trigger point maps. Although it is frequently performed in these regions, it is beneficial to scan the entire muscle.⁴

Rule 2. It should be remembered that needling could be performed in different positions for each muscle. For the pectoralis major muscle, it is applied in the supine position and the shoulder in slight abduction.⁴

Rule 3. After detecting the trigger point, it is placed between the fingers using the first 3 fingers. During the application of dry needling, care should be taken to ensure that the needle does not cross the finger at the most basal. To avoid getting into the lungs, the lower fingers are considered as a border.⁴

In this manner, a treatment algorithm provides maximum protection from possible complications. In fact, complications such as pneumothorax have been reported in the thoracic region due to dry needling treatment.⁵ This situation can cause anxiety in physicians, due to which they may hesitate to apply this treatment. Therefore, it should be remembered that as long as we practice the technique of dry needling in this region, we must attempt to minimize the complications.

Figure 1. A, The shoulder of the patient is positioned in a slight abduction. B, Dry needling application technique should be done with pincer palpation method



Fatih Bagcier, MD

Department of Physical Medicine and Rehabilitation,
Biruni University Faculty of Medicine, Istanbul, Turkey

bagcier_42@hotmail.com

Ozan Volkan Yurdakul, MD

Erkan Ozduran, MD

To see this article online, please go to: <http://jabfm.org/content/33/6/1032.full>.

References

1. Hagberg SM, Woitalla F, Crawford P. 2002 ACC/AHA guideline versus clinician judgment as diagnostic tests for chest pain. *J Am Board Fam Med* 2008;21:101–7.
2. Stochkendahl MJ, Christensen HW. Chest pain in focal musculoskeletal disorders. *Med Clin North Am* 2010; 94:259–73.
3. Choi YJ, Choi SU, Shin HW, Lee HW, Lim HJ, Chang SH. Chest pain caused by the trigger points in the scalenus muscle: a case report. *Korean J Anesthesiol* 2007;53:680–2.
4. Simons DG, Travell JG, Simons LS. Travell & Simons' myofascial pain and dysfunction: upper half of body. Vol. 1. Philadelphia, PA: Lippincott Williams & Wilkins; 1999.
5. Uzar T, Turkmen I, Menekse EB, Dirican A, Ekaterina P, Ozkaya S. A case with iatrogenic pneumothorax due to deep dry needling. *Radiol Case Rep* 2018;13:1246–8.

doi: 10.3122/jabfm.2020.06.200342