Reproductive BioMedicine Online (2015) 31, 404–410

www.sciencedirect.com
www.rbmonline.com

ARTICLE

# Protective effect of resveratrol against oxidative damage to ovarian reserve in female Sprague–Dawley rats

Pınar Özcan [a,*], Cem Fıçıcıoğlu [a], Özge Kızılkale Yıldırım [a], Ferda Özkan [b], Hatice Akkaya [c], İsmail Aslan [d]

[a] *Department of Obstetrics and Gynecology, Faculty of Medicine, Yeditepe University, İstanbul, Turkey;* [b] *Department of Pathology, Faculty of Medicine, Yeditepe University, İstanbul, Turkey;* [c] *Experimental Research Center (YUDETAM), Faculty of Medicine, Yeditepe University, Istanbul, Turkey;* [d] *Faculty of Pharmacy, Department of Pharmaceutical Technology, Yeditepe University, Atasehir, Istanbul, Turkey*

* Corresponding author. *E-mail address:* drpinarozcan@hotmail.com (P Özcan).

Dr Pınar Ozcan attended medical school at Faculty of Medicine, Gazi University, Ankara,Turkey. She completed an obstetrics and gynaecology residency programme at the Department of Obstetrics and Gynaecology, Ankara Gazi University Hospital, Ankara, Turkey in 2009, after which she received IVF certification training, and worked as an obstetrics and gynaecology specialist at Yeditepe University Hospital. She has been working as specialist at the Department of Obstetrics and Gynaecology, Bezmialem University Hospital, since 2014. She is especially interested in reproductive medicine and infertility.

**Abstract** An increased accumulation of intracellular levels of reactive oxygen species with time may play an important role in the process of ageing. The antioxidant properties of resveratrol are dependent upon the up-regulation of endogenous cellular antioxidant systems. We evaluated whether resveratrol has protective antioxidant effects on ovarian damage related to oxidative stress in a rat model. Twenty-four female rats were randomly divided into three groups and were given saline (group 1: control); intraperitoneal cisplatin, 4.5 mg/kg, two weekly doses in total (group 2); or cisplatin, 4.5 mg/kg plus intraperitoneal resveratrol 10 mg/kg/day, 24 h before the administration of cisplatin (group 3). Serum anti-Müllerian hormone (AMH) concentrations were significantly lower in group 2 than in group 3 ($P < 0.01$ and $P = 0.04$, respectively). The evaluation of the atretic and antral follicle counts revealed statistically significant differences between the groups ($P = 0.04$ and $P < 0.01$, respectively). A statistically significant difference was observed in the follicle count positive for AMH between the groups ($P = 0.01$). Oxidative stress plays an important role in the process of ovarian ageing. Because of its natural antioxidant properties, resveratrol may be an effective option in protecting ovarian tissue against oxidative damage.

© 2015 Reproductive Healthcare Ltd. Published by Elsevier Ltd. All rights reserved.

**KEYWORDS:** AMH, ovarian reserve, oxidative damage, resveratrol

http://dx.doi.org/10.1016/j.rbmo.2015.06.007
1472-6483/© 2015 Reproductive Healthcare Ltd. Published by Elsevier Ltd. All rights reserved.

## Introduction

No one single theory can explain all the mechanisms of ageing (Baynes, 2001). It is clear, however, that oxidative stress spontaneously developing in a cell is one of these mechanisms. Reactive oxygen species (ROS) generated during biological events in a cell are normally handled by non-enzymatic and enzymatic antioxidant systems. Oxidative stress occurs as a result of an imbalance between the production of ROS and the antioxidant systems of a cell in cases in which the effectiveness of antioxidant systems decreases or the production of ROS increases.

Oxidative stress triggers cellular injuries by damaging important cell components, such as nucleic acids; this finally leads to chromosomal damage, development of mutant cells, the modulation of cell growth, or both (Wilson et al., 2003). Therefore, the most commonly accepted theory explaining the process of ageing is the increased production of intracellular ROS through time. With ageing, the imbalance between the levels of ROS in cells and the antioxidant capacity of cells arises owing to a possible rise in ROS production and a decrease in the non-enzymatic antioxidant defenses. As a result, the extent of oxidative damage increases.

Ovarian ageing is also connected to increased levels of ROS caused by the deterioration in the balance between ROS production and non-enzymatic antioxidant defences; however, the role of oxidative stress in female infertility remains unclear (Agarwal et al., 2005; Tarin, 1996). Oxidative stress plays a role in most stages of human reproduction, including oocyte maturation, steroidogenesis, fertilization and embryo development (Agarwal et al., 2005). It has been found that the administration of oral antioxidants is effective in counteracting ovarian ageing associated with oxidative stress by lessening oxidative stress in ovarian tissue (Tarin et al., 2002).

Cisplatin is a platinum derivative chemotherapeutic agent used for the treatment of solid tumours and an intermediately gonadotoxic agent (Tangir et al., 2003). Chemotherapeutic agents cause the toxic effects on ovarian function. These negative effects, however, depend on the agent administered, the doses received and the patient's age at the time of treatment. Although permanent infertility could be caused by a single dose of chemotherapy of cisplatin in women, the possibility of gonadal recovery improves with the length of time off chemotherapy. At doses lower than 400 mg/m$^2$, long-term effects on endocrine-gonadal function are unlikely to occur. Higher doses would be expected to cause long-term endocrine-gonadal dysfunction. Although the mechanism of cisplatin toxicity on ovaries has not been clearly explained to date, it is thought to increase ROS production and decrease antioxidant capacity because of cisplatin-induced oxidative stress similar to cisplatin toxicity on the kidney and internal ear (Chirino and Pedraza-Chaverri, 2009; Tangir et al., 2003; Weijl et al., 1998; Yucebilgin et al., 2004). Therefore, in the present study, cisplatin was used to create oxidative stress in ovarian tissue.

Resveratrol is a secondary plant metabolite isolated from the roots and fruits of many plants and it protects these plants from fungal and bacterial infections (Langcake et al., 1979). Many studies have focused on identifying the physiological functions and biological activities of resveratrol for human therapeutic purposes. Resveratrol has a wide variety of biological properties, including anti-inflammatory, antioxidant, antiproliferative, proapoptotic and anticancer effects (Carter et al., 2014; Langcake et al., 1979; Pervaiz and Holme, 2009). Resveratrol has antioxidant properties that can strengthen endogenous cellular antioxidant systems and have direct ROS-scavenging properties (Bradamante et al., 2004). The heavy follicular atresia in the ovaries brought about by apoptosis resulting from ROS-induced damage contributes to ovarian ageing (Broekmans et al., 2007). Antioxidants reduce follicular atresia associated with apoptosis and ROS-induced damage. Information on the effects of resveratrol on oxidative stress related to ovarian damage caused by ageing is, however, limited.

The aim of this study was to evaluate whether resveratrol has protective antioxidant effects on ovarian damage related to oxidative stress by measuring primordial, antral and atretic follicle counts, serum anti-Müllerian hormone (AMH) levels and AMH-positive granulosa cells. Tissue levels of the oxidant malondialdehyde (MDA), the stable end product of lipid peroxidation and antioxidant superoxide dismutase (SOD), one of the most important antioxidant enzymes was also evaluated.

## Materials and methods

### Animals

Twenty-four adult female Sprague–Dawley rats (weight 200–250 g; age 65–75 days) provided by the Yeditepe University Animal Reproduction Center and housed in the Animal Laboratory of Yeditepe University (Istanbul, Turkey), were used for the study.

The rats were maintained under standard housing conditions with a 12-h light–dark cycle with ad-libitum access to food and water. The experimental protocol was approved by the Institutional Animal Care and Use Committee of Yeditepe University on 6 September 2013. All procedures were carried out in accordance with the National Academy of Science's Guide for Care and Use of Laboratory Animals (1996).

### Experimental design

The rats were randomly divided into three groups (eight rats per group), and they were given saline (group 1, control); cisplatin, 4.5 mg/kg (group 2, cisplatin group); or cisplatin, 4.5 mg/kg plus resveratrol 10 mg/kg/day (group 3, cisplatin-resveratrol group).

### Drug administration

Resveratrol (Interpharma Praha, Czech Republic) and cisplatin (Hospira, UK) were diluted in normal saline immediately before use, and two injections were administered with an interval of 7 days. Resveratrol injections were given 24 h before the administration of cisplatin. The lethal dose (LD50) of cisplatin on rats was 7.4 mg/kg (Dale et al., 2000). The drug doses were chosen on the basis of previously published studies that evaluated the protective effects of resveratrol on oxidative stress in rats (Ara et al., 2005; Li et al., 2013).

## Sample collection

Five days after the second injections, all the rats were anaesthetized by an intramuscular administration of 50 mg/kg ketamine hydrochloric acid (Ketalar; Eczacibasi Warner-Lambert Ilac Sanayi, Levent, Istanbul, Turkey) and 7 mg/kg xylazine hydrochloric acid (Rompun, Bayer Sisli, Istanbul, Turkey). They were immobilized on a standard rat surgery board. The aseptic technique was used to make a ventral midline incision to expose the reproductive organs. The ovaries were removed. To evaluate the oxidant–antioxidant balance, one ovary of each rat was immediately stored at −80°C for an oxidative stress assay, and the other ovary was fixed in 10% neutral buffered formaldehyde solution for histopathological examination. The fixed specimens were embedded in paraffin blocks, sectioned at 5-mm thickness, and stained with haematoxylin and eosin. Histopathologic examination was carried out by a pathologist unaware of the treatment allocation. Additionally, blood samples were collected to measure the serum AMH level.

## Oxidative stress and antioxidation assay

### Malondialdehyde

Malondialdehyde (MDA) was measured using the thiobarbituric acid test to determine the concentrations of ovarian tissue lipid peroxidation (nmol/g tissue) (Placer et al., 1996). One volume of the test sample and two volumes of stock reagent (trichloroacetic acid and thiobarbituric acid) were mixed in a centrifuge tube. The solution was incubated in boiling water for 20 min. After cooling, the solution was centrifuged at 810 g for 5 min to remove the precipitate and then the absorbance of the supernatant was spectrophotometrically measured at 532 nm against a blank containing all the reagents except the test sample on a spectrophotometer. The results were expressed as nmol/g tissue.

### Superoxide dismutases analysis

Total Superoxide dismutases (SOD) activity was measured by the method described by Sun et al. (1998). One volume of the test sample and one volume of a chloroform and ethanol mixture (3/5 v/v) were mixed in a centrifuge tube. The solution was centrifuged at 1580*g* for 45 min to remove the precipitate. The assay solution consisting of a sodium carbonate buffer (400 mM), 0.3 mM xanthine, 150 μmol/l nitro blue tetrazolium (NBT), 0.6 mmol/l Na2EDTA, 1 g/l bovine serum albumin, xanthine oxidase 167 U/l and sample was mixed in a cuvette. The activity was measured by using xanthine and xanthine oxidase to generate superoxide radicals that react with NBT. One SOD unit was defined as the amount of protein that inhibits the rate of NBT reduction by 50%; SOD activities were expressed as U/mg protein. Protein content was determined according to Lowry et al. (1951) using bovine serum albumin.

### Serum AMH concentrations

Serum AMH levels were measured by USCN Life Science enzyme-linked immunosorbent assays (ELISA). The assay range was 0.31–20 ng/ml, and the minimum detectable dose of this assay was less than 0.078 ng/ml. The technician was unaware of the treatment allocation.

## Immunohistochemistry

Histopathologic examination was carried out by a pathologist blinded to the treatment allocation. Formalin-fixed ovarian tissues were embedded in paraffin blocks and sectioned at 5-mm thickness (four sections per sample), and then stained with haematoxylin and eosin. Three sections were randomly selected from one ovary for immunohistochemistry examination. The immunohistochemistry procedure was as follows: paraffin sections were deparaffinized with xylene and rehydrated through a graded series of ethyl alcohol (70–100%) for 5 min each. For antigen visualization, the sections were heated under high pressure with a citrate buffer (pH 6.0) and incubated with $H_2O_2$ to block non-specific antibody binding. The mouse monoclonal antibody to AMH (AMH(5/6) GTX42794 GeneTex Irvine, CA 92606 USA) as a primary antibody was diluted to a concentration of 1:100 for incubation overnight at 4°C. After being washed three times for 5 min with phosphate buffered saline (PBS), the specimens were incubated with the secondary antibody and treated with diaminobenzidine. Then the sections were stained with Mayer haematoxylin and covered.

The analysis of the AMH-positive follicles was based on two factors: the intensity and the distribution of staining (Yeh et al., 2008). The intensity for each follicle in an ovarian section was graded from 0 to 3 as follows: 0, no staining; 1, weak staining; 2, moderate staining; and 3, strong staining. The distribution was graded as 1 or 2 (1, ≤ 50% of the structure staining and 2, ≥50% of the structure staining). The total score was obtained by multiplying the intensity by the distribution. A score of ≥2 was considered positive for AMH. Two independent observers evaluated each slide. Immunohistochemical staining was scored in a semi-quantitative manner to determine differences between the control group and the experimental groups. The numbers of positively stained follicles were recorded as follows: absence, 0 (–); few, 1 (±); a few, 2 (+); medium, 3 (++); high, 4 (+++); and very high, 5 (++++). This analysis was carried out in serial sections of each animal at ×400 magnification.

## Histopathological evaluation

The histopathologic examination was carried out by a pathologist blinded to the groups. Formalin-fixed ovarian tissues were embedded in paraffin blocks, sectioned at 5-mm thickness (four sections per sample), stained with haematoxylin and eosin and examined under a light microscope. Atretic follicles, antral follicles and primordial follicles were evaluated (1987). The techniques described by Sadrkhanloo et al. (1987), Andreu et al. (1998) and Goto et al. (1999) were used.

## Statistical analysis

The results were analysed using the Statistical Package for the Social Sciences version 21.0 (SPSS, Chicago, IL, USA). Data

were reported as mean ± SD. Differences in measured parameters between the three groups were analysed by Kruskal–Wallis with post-hoc correction. After post-hoc correction, $P < 0.016$ was considered statistically significant. Dual comparisons between groups with significant values were analysed by a Mann–Whitney U test. $P < 0.05$ was considered statistically significant.

## Results

The tissue levels of MDA and SOD of all groups are presented in **Table 1**. No significant differences were observed in these parameters between the groups. In the cisplatin group, the mean level of MDA in the ovarian tissues was the highest and the mean level of SOD was the lowest. A trend toward an increase in the mean level of SOD in the ovarian tissues was observed (0.22 ± 0.19 in the cisplatin group versus 0.41 ± 0.28 in the cisplatin plus resveratrol group) and a decrease in the mean level of MDA in the ovarian tissues (4.49 ± 3.02 in the cisplatin group versus 3.62 ± 1.52 in the cisplatin + resveratrol group) in the cisplatin plus resveratrol group.

The mean serum AMH concentrations were 1.17 ± 0.37, 0.17 ± 0.03 and 1.07 ± 0.59 ng/ml in groups 1, 2 and 3 respectively ($P < 0.01$) (**Table 1**). Serum AMH concentrations were significantly lower in the cisplatin group compared with those of the control and cisplatin plus resveratrol groups ($P < 0.01$ and $P = 0.04$ respectively). No significant difference was observed in mean serum AMH concentrations between the control and cisplatim plus resveratrol groups.

The primordial, antral and atretic follicle counts of all groups are shown in **Table 2**. No significant difference was found in the primordial follicle counts between the three groups. The evaluation of the atretic and antral follicle counts revealed statistically significant differences between the groups ($P = 0.04$ and $P < 0.01$, respectively). The cisplatin group has the lowest antral and the highest atretic follicle count. The atretic follicle count was significantly lower in the cisplatin plus resveratrol group compared with the cisplatin group ($P = 0.04$). The proportions of atretic and antral follicles in the ovaries of all groups are presented in **Figure 1**.

The immunohistochemical analysis for AMH-positive follicles in all groups is presented in **Figure 1**. A statistically significant difference was found in the AMH-positive follicle count between the groups ($P = 0.01$) (**Table 1**). The AMH-positive follicles were significantly fewer in the cisplatin group compared with those of the control group ($P = 0.01$). No significant difference was found between the control and the cisplatin plus resveratrol group in terms of the quantitative analysis of AMH-positive follicles.

## Discussion

Some histomorphological and biochemical methods have been described to demonstrate ovarian function and ovarian damage, such as antral and atretic follicle counts and serum hormone concentrations (Anderson and Cameron, 2011; Broekmans et al., 2006). In the present study, hormonal, histopathological and immunohistochemical methods were used to detect the protective effect of resveratrol on the reduction of fertility with oxidative stress-related ovarian damage in rats. Upon the use of resveratrol in combination with cisplatin, the serum AMH level and AMH-positive

**Table 1** The evaluation of ovarian malondialdehyde (MDA) and superoxide dismutases (SOD) levels, serum concentrations of anti-Müllerian hormone (AMH) and number of AMH-positive follicles.

| | *Group 1: control (n = 8)* | *Group 2: cisplatine (n = 8)* | *Group 3: cisplatine plus resveratrol (n = 8)* | *P-value* |
|---|---|---|---|---|
| Serum concentrations of AMH (ng/ml) | 1.17 ± 0.37 | 0.17 ± 0.03 | 1.07 ± 0.59 | <0.01[a] |
| Ovarian MDA level (nmol/g tissue) | 3.20 ± 0.75 | 4.49 ± 3.02 | 3.62 ± 1.52 | 0.86 |
| Ovarian SOD level (U/mg protein) | 0.33 ± 0.07 | 0.22 ± 0.19 | 0.41 ± 0.28 | 0.16 |
| Number of AMH-positive follicles | 9.87 ± 3.97 | 3.75 ± 2.81 | 8.25 ± 3.32 | 0.01[a] |

All values are expressed as mean ± SD.
[a]$P < 0.05$, significant difference.

**Table 2** Comparision of the primordial, antral and atretic follicles counts of all groups.

| | *Group 1: control (n = 8)* | *Group 2: cisplatine (n = 8)* | *Group 3: cisplatine plus resveratrol (n = 8)* | *P-value* |
|---|---|---|---|---|
| Primordial follicles counts | 6.25 ± 2.25 | 5.13 ± 55 | 6.63 ± 3.88 | 0.68 |
| Antral follicles counts | 2.88 ± 1.12 | 1.00 ± 0.92 | 1.5 ± 0.92 | <0.01[a] |
| Atretic follicles counts | 1.00 ± 0.0 | 1.29 ± 0.48 | 0.50 ± 0.53 | 0.04[a] |

All values are expressed as mean ± SD.
[a]$P < 0.05$, significant difference.

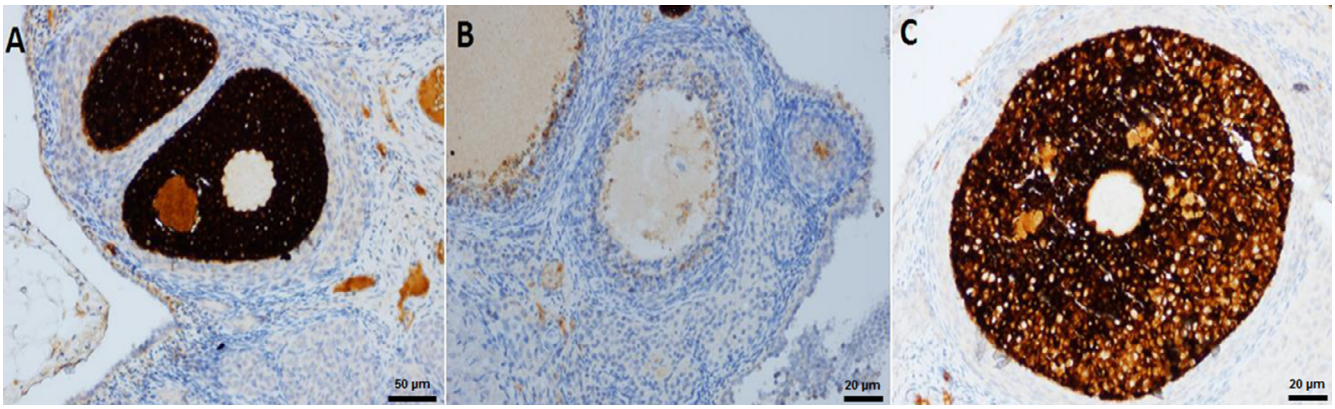


**Figure 1** The immunohistochemical detection of intensity of staining of the follicles positive for anti-Müllerian hormone. (A) group 1 (control, saline), very high, 5 (++++).; (B) group 2 (cisplatin group, 4.5 mg/kg cisplatin), a few, 2 (+); (C) group 3 (cisplatin-resveratrol group, 4.5 mg/kg + resveratrol 10 mg/kg/day), high, 4 (+++). Panel A bar = 50 µm and panels B and C bar = 20 µm.

follicles dramatically increased, whereas the atretic follicle count significantly decreased. These outcomes suggest that resveratrol could protect against the reduction of fertility owing to oxidative stress-related ovarian damage. The data were obtained using a rat model and may therefore not predict accurate results on human reproduction; furthermore, the dose, schedule and effect of resveratrol should be investigated on human ovaries.

Fertility significantly decreases with age, and the reduction of fertility is particularly noticeable after the age of 30 years; therefore, woman's age is one of the most important factors in determining fertility and ovarian reserve. As ovarian reserve physiologically decreases with age, the ovarian reserve according to the physiological age is lower than expected because of individual variability; this is known as diminished ovarian reserve (DOR) (Barad et al., 2007; Broekmans et al., 2009; te Velde and Pearson, 2002). The quality of oocyte also diminishes as a result of many factors during the lifetime, and leads to an increasing rate of aneuploidy. Oxidative stress, however, is associated with ageing, known as the free radical theory of ageing, and physiological programmed ageing are the most commonly accepted theories to explain ovarian ageing. According to the free radical theory of ageing, ageing happens because of an imbalance between ROS production and antioxidant systems (Harman, 1956). Although the role of ROS is well documented in the development of some pathological conditions,such as carcinogenesis and ageing, the potential protective effects of antioxidants against tissue damage related to oxidative stress is unclear (Luo et al., 2011). It has been demonstrated that some pathologies causing subfertility or infertility in both males and females result from oxidative stress because of the potentially adverse effects of oxidative stress in most stages of human reproduction. Although some recent studies have addressed this point, the role of oxidative stress in female infertility remains unclear (Agarwal et al., 2005). The increased production of intracellular ROS and depletion of antioxidant defenses, which is the most important deficiency in ageing cells, induces glucocorticoid apoptosis and reduces glucocorticoid proliferation because of ROS damage to lipids, proteins, telomerase activity, telomeres, DNA and mitochondria (Meldrum, 2013). The age-related dysfunction of the granulosa cells surrounding the oocyte causes damage to oocytes, and a strong relationship exists between increased glucocorticoid apoptosis and reduced oocyte–embryo quality and failed embryo implantation.

On the other hand, mitochondria play several important functional roles in the reproductive process, fertilization and embryonic development. According to a mitochondrial basis for ovarian ageing, age-related changes in mitochondrial function and mitochondrial genes influence the quality of oocytes owing to their roles in physiological processes, including energy metabolism, homeostasis, spindle formation, abnormal chromosomal alignment and the death of cell (Tatone et al., 2008). Mitochondria are the major source of ROS in the cell and they are eliminated by antioxidative enzymes (Nickel et al., 2014). The balance between the production of ROS in mitochondria and the antioxidant capacity, also known as the mitochondrial redox state, alters under different physiological and pathological conditions. Ageing cells produce more ROS in the mitochondria and antioxidant defenses are reduced in these cells compared with younger ones. Moreover, a causative relationship exists between mitochondrial DNA mutations and ageing. Especially in older women, luteinizing granulosa cells contain higher levels of mtDNA deletion and produce more ROS in mitochondria, whereas antioxidant enzymes are markedly reduce in the damage mitochondria and they facilitate the activation of the apoptosis in oocytes (Li et al., 2012). Telomerase activity, however, is important to maintain genomic stability, survival and proliferation of germ cells because the telomere length is a marker for cellular ageing. The long-time exposure to ROS may affects granulosa cell apoptosis, follicular atresia, oocyte ageing and fertility because of telomerase deficiency and the telomere shortening (Li et al., 2012). A recent review indicated that granulosa cell dysfunction, mitochondrial defects and oocyte telomere shortening contribute to reproductive ageing, and the correction of these abnormalities can improve fertility (Meldrum, 2013). Several studies have recently focused on improving these abnormalities in ageing oocytes using antioxidant (Bentov and Casper, 2013; Kalmbach et al., 2013).

It has been shown that resveratrol enhances endogenous cellular antioxidant systems such as SOD and catalasem

and that it inhibits the expression and activity of nicotinamide adenine dinucleotide phosphate oxidase located in mitochondria (de la Lastra and Villegas, 2007; Xia et al., 2010).

Rubiolo et al. (2008) used primary rat hepatocyte cultures to show that resveratrol prevents oxidative damage in these cells by increasing the activity of antioxidant enzymes. The induction of antioxidative enzymes by resveratrol has also been reported in vascular tissues (Li et al., 2006; Rubiolo et al., 2008). On the other hand, the protective effects of resveratrol on ovarian function is still unclear because studies evaluating this effect are limited, whereas data indicated that resveratrol exerts predominantly estrogenic effects (Henry and Witt, 2006). An experimental rat study that evaluated the effect of resveratrol on ovaries in different age groups found that resveratrol significantly increased the total number of oocytes, significantly decreased the atretic follicles and inhibit both the primordial-to-developing-follicle transition and apoptosis (Kong et al., 2011).

A recent study investigated the effect of resveratrol on age-associated infertility in a mouse and revealed that resveratrol protects fertility against ageing-related changes and it provides improvement of healthy follicle numbers, oocyte quantity and quality (Liu et al., 2013). These effects of resveratrol seem more likely to be associated with increasing telomere length and telomerase activity and reduction of germ cell dysfunction. Mukherjee et al. (2014) showed that the supplementation of resveratrol at optimum concentrations during IVM improves the microenvironment within oocytes by increasing the intracellular GSH and decreasing the ROS level, thus stimulating embryonic development, and regulating gene expression (Mukherjee et al., 2014). Several studies have evaluated the effect of resveratrol as a novel treatment modality for polycystic ovary syndrome. They show that resveratrol promotes apoptosis of the ovarian theca-interstitial cell, inhibits the growth of the ovarian theca-interstitial cell and reduces androgen production (Ortega et al., 2012a; Wong et al., 2010). Furthermore, Ortega et al. (2012b) also showed that resveratrol stimulate proliferation of rat granulosa cells as exhibiting pro-apoptotic actions on theca-interstitial cells. In their study on mice, Cabello et al. (2015) showed that resveratrol may counteract the loss of ovarian follicles in conditions associated with obesity and enhance the ovarian response to ovarian stimulation in normal-weight females (Cabello et al., 2015) because obesity and excessive caloric intake promote oxidative stress due to releasing more ROS from mitochondria. As mentioned above, our study confirmed that resveratrol can potentially protect ovarian functions from oxidative damage as an antioxidant as shown by the significant increase in antral follicle number and significant decrease atretic follicles number.

In conclusion, our study may provide evidence that resveratrol could protect the ovaries against oxidative damage-related changes and it could lead to decreased follicular atresia and improved antral follicle numbers. Other experimental studies ought to be designed to determine the optimum dosage and duration of resveratrol treatment to enhance its protective effects. Moreover, the data obtained using a rat model may not predict human reproduction directly, and future studies are needed to investigate the effect of resveratrol on human ovaries.

## References


Agarwal, A., Gupta, S., Sharma, R.K., 2005. Role of oxidative stress in female reproduction. Reprod. Biol. Endocrinol. 3, 28.

Anderson, R.A., Cameron, D.A., 2011. Pretreatment serum anti-mullerian hormone predicts long-term ovarian function and bone mass after chemotherapy for early breast cancer. J. Clin. Endocrinol. Metab. 96, 1336–1343.

Andreu, C., Parborell, F., Vanzulli, S., Chemes, H., Tesone, M., 1998. Regulation of follicular luteinization by a gonadotropin-releasing hormone agonist: relationship between steroidogenesis and apoptosis. Mol. Reprod. Dev. 51, 287–294.

Ara, C., Kirimlioglu, H., Karabulut, A.B., Coban, S., Ay, S., Harputluoglu, M., Kirimlioglu, V., Yilmaz, S., 2005. Protective effect of resveratrol against oxidative stress in cholestasis. J. Surg. Res. 127, 112–117.

Barad, D.H., Weghofer, A., Gleicher, N., 2007. Age-specific levels of basal follicle stimulating hormone assessment of ovarian function. Obstet. Gynecol. 109, 1404–1410.

Baynes, J.W., 2001. The role of AGEs in aging: causation or correlation. Exp. Gerontol. 36, 1527–1537.

Bentov, Y., Casper, R.F., 2013. The aging oocyte–can mitochondrial function be improved? Fertil. Steril. 99, 18–22.

Bradamante, S., Barenghi, L., Villa, A., 2004. Cardiovascular protective effects of resveratrol. Cardiovasc. Drug Rev. 22, 169–188.

Broekmans, F.J., Kwee, J., Hendriks, D.J., Mol, B.W., Lambalk, C.B., 2006. A systematic review of tests predicting ovarian reserve and IVF outcome. Hum. Reprod. Update 12, 685–718.

Broekmans, F.J., Knauff, E.A., te Velde, E.R., Macklon, N.S., Fauser, B.C., 2007. Female reproductive ageing: current knowledge and future trends. Trends Endocrinol. Metab. 18, 58–65.

Broekmans, F.J., Soules, M.R., Fauser, B.C., 2009. Ovarian aging: mechanisms and clinical consequences. Endocr. Rev. 30, 465–493.

Cabello, E., Garrido, P., Morán, J., González del Rey, C., Llaneza, P., Llaneza-Suárez, D., Alonso, A., González, C., 2015. Effects of resveratrol on ovarian response to controlled ovarian hyperstimulation in ob/ob mice. Fertil. Steril. 103, 570–579.

Carter, L.G., D'Orazio, J.A., Pearson, K.J., 2014. Resveratrol and cancer: focus on in vivo evidence. Endocr. Relat. Cancer 21, 209–225.

Chirino, Y.I., Pedraza-Chaverri, J., 2009. Role of oxidative and nitrosative stress in cisplatininduced nephrotoxicity. Exp. Toxicol. Pathol. 61, 223–242.

de la Lastra, C.A., Villegas, I., 2007. Resveratrol as an antioxidant and pro-oxidant agent: mechanisms and clinical implications. Biochem. Soc. Trans. 35, 1156–1160.

Dale, O., Mortensen, B., Thommesen, L., Hagen, B., 2000. Cisplatin toxicity in the rat may be influenced by anaesthetic agents. Acta Anaesthesiol. Scand. 44, 770.

Goto, T., Endo, T., Henmi, H., 1999. Gonadotropin-releasing hormone agonist has the ability to induce increased matrix metalloproteinase (MMP)-2 and membrane type 1-MMP expression in corpora lutea, and structural luteolysis in rats. J. Endocrinol. 161, 393–402.

Harman, D., 1956. Aging: a theory based on free radical and radiation chemistry. J. Gerontol. 11, 298–300.

Henry, L.A., Witt, D.M., 2006. Effects of neonatal resveratrol exposure on adult male and female reproductive physiology and behavior. Dev. Neurosci. 28, 186–195.

Kalmbach, K.H., Antunes, D.M.F., Dracxler, R.C., Knier, T.W., Seth-Smith, M.L., Wang, F., Liu, L., Keefe, D.L., 2013. Telomeres and human reproduction. Fertil. Steril. 99, 23–29.

Kong, X.X., Fu, Y.C., Xu, J.J., Zhuang, X.L., Chen, Z.G., Luo, L.L., 2011. Resveratrol, an effective regulator of ovarian development and oocyte apoptosis. J. Endocrinol. Invest. 34, 374–381.

Langcake, P., Cornford, C., Pryce, R., 1979. Identification of pterostilbene as a phytoalexin from Vitis vinifera leaves. Phytochemistry 18, 1025–1027.
Li, Q., Geng, X., Zheng, W., Tang, J., Xu, B., Shi, Q., 2012. Current understanding of ovarian aging. Sci. China Life Sci. 55, 659–669.
Li, X., Yang, S., Lv, X., Sun, H., Weng, J., Liang, Y., Zhou, D., 2013. The mechanism of mesna in protection from cisplatin-induced ovarian damage in female rats. J. Gynecol. Oncol. 24, 177–185.
Li, Y., Cao, Z., Zhu, H., 2006. Upregulation of endogenous antioxidants and phase 2 enzymes by the red wine polyphenol, resveratrol in cultured aortic smooth muscle cells leads to cytoprotection against oxidative and electrophilic stress. Pharmacol. Res. 53, 6–15.
Liu, M., Yin, Y., Ye, X., Zeng, M., Zhao, Q., Keefe, D.L., Liu, L., 2013. Resveratrol protects against age-associated infertility in mice. Hum. Reprod. 28, 707–717.
Lowry, O.H., Rosebrough, N.J., Farr, A.L., Randall, R.J., 1951. Protein measurement with folin phenol reagent. J. Biol. Chem. 193, 265–275.
Luo, C., Urgard, E., Vooder, T., Metspalu, A., 2011. The role of COX-2 and Nrf2/ARE in antiinflammation and antioxidative stress: aging and anti-aging. Med. Hypotheses 77, 174–178.
Meldrum, D.R., 2013. Aging gonads, glands, and gametes: immutable or partially reversible changes? Fertil. Steril. 99, 1–4.
Mukherjee, A., Malik, H., Saha, A.P., Dubey, A., Singhal, D.K., Boateng, S., Saugandhika, S., Kumar, S., De, S., Guha, S.K., Malakar, D., 2014. Resveratrol treatment during goat oocytes maturation enhances developmental competence of parthenogenetic and hand-made cloned blastocysts by modulating intracellular glutathione level and embryonic gene expression. J. Assist. Reprod. Genet. 31, 229–239.
Nickel, A., Kohlhaas, M., Maack, C., 2014. Mitochondrial reactive oxygen species production and elimination. J. Mol. Cell. Cardiol. 73, 26–33.
Ortega, I., Villanueva, J.A., Wong, D.H., Cress, A.B., Sokalska, A., Stanley, S.D., Duleba, A.J., 2012a. Resveratrol reduces steroidogenesis in rat ovarian theca-interstitial cells: the role of inhibition of Akt/PKB signaling pathway. Endocrinology 153, 4019–4029.
Ortega, I., Wong, D.H., Villanueva, J.A., Cress, A.B., Sokalska, A., Stanley, S.D., Duleba, A.J., 2012b. Effects of resveratrol on growth and function of rat ovarian granulosa cells. Fertil. Steril. 98, 1563–1573.
Pervaiz, S., Holme, A.L., 2009. Resveratrol: its biologic targets and functional activity. Antioxid. Redox Signal. 11, 2851–2897.
Placer, Z.A., Cushman, L., Johnson, B.C., 1996. Estimation of products of lipid peroxidation in biological fluids. Anal. Biochem. 16, 359–364.
Rubiolo, J.A., Mithieux, G., Vega, F.V., 2008. Resveratrol protects primary rat hepatocytes against oxidative stress damage: activation of the Nrf2 transcription factor and augmented activities of antioxidant enzymes. Eur. J. Pharmacol. 591, 66–72.
Sadrkhanloo, R., Hofeditz, C., Erickson, G.F., 1987. Evidence for widespread atresia in the hypophysectomized estrogen-treated rat. Endocrinology 120, 146–155.
Sun, Y., Oberley, L.W., Li, Y., 1998. A simple method for clinical assay of superoxide dismutase. Clin. Chem. 34, 497–500.
Tangir, J., Zelterman, D., Ma, W., Schwartz, P.E., 2003. Reproductive function after conservative surgery and chemotherapy for malignant germ cell tumors of the ovary. Obstet. Gynecol. 101, 251–257.
Tarin, J.J., 1996. Potential effects of age-associated oxidative stress on mammalian oocytes/embryos. Mol. Hum. Reprod. 2, 717–724.
Tarin, J.J., Perez-Albala, S., Cano, A., 2002. Oral antioxidants counteract the negative effects of female aging on oocyte quantity and quality in the mouse. Mol. Reprod. Dev. 61, 385–397.
Tatone, C., Amicarelli, F., Carbone, M.C., Monteleone, P., Caserta, D., Marci, R., Artini, P.G., Piomboni, P., Focarelli, R., 2008. Cellular and molecular aspects of ovarian follicle ageing. Hum. Reprod. Update 14, 131–142.
te Velde, E.R., Pearson, P.L., 2002. The variability of female reproductive aging. Hum. Reprod. Update 8, 141–154.
Weijl, N.I., Wipkink-Bakker, A., Lentjes, E.G.W.M., Berger, H.M., Cleton, F.J., Osanto, S., 1998. Cisplatin combination chemotherapy induces a fall in plasma antioxidants of cancer patients. Ann. Oncol. 9, 1331–1337.
Wilson, D.M., Sofinowski, T.M., McNeill, D.R., 2003. Repair mechanisms for oxidative DNA damage. Front. Biosci. 1, 963–981.
Wong, D.H., Villanueva, J.A., Cress, A.B., Duleba, A.J., 2010. Effects of resveratrol on proliferation and apoptosis in rat ovarian theca-interstitial cells. Mol. Hum. Reprod. 16, 251–259.
Xia, N., Daiber, A., Habermeier, A., Closs, E.I., Thum, T., Spanier, G., Lu, Q., Oelze, M., Torzewski, M., Lackner, K.J., Münzel, T., Förstermann, U., Li, H., 2010. Resveratrol reverses endothelial nitric-oxide synthase uncoupling in apolipoprotein E knockout mice. J. Pharmacol. Exp. Ther. 335, 149–154.
Yeh, J., Kim, B.S., Peresie, J., 2008. Protection against cisplatin-induced ovarian damage by the antioxidant sodium 2-mercaptoethanesulfonate (mesna) in female rats. Am. J. Obstet. Gynecol. 198, 463.e1-7.
Yucebilgin, M.S., Terek, M.C., Ozsaran, A., Akercan, F., Zekioglu, O., Isik, E., Erhan, Y., 2004. Effect of chemotherapy on primordial follicular reserve of rat: an animal model of premature ovarian failure and infertility. Aust. N. Z. J. Obstet. Gynaecol. 44, 6–9.

*Declaration: The authors report no financial or commercial conflicts of interest.*

Received 30 January 2015; refereed 25 May 2015; accepted 3 June 2015.