

Muscle Abscess due to Salmonella Enterica

Yasemin Akkoyunlu¹, Bahadır Ceylan^{1,*}, Meryem Iraz¹, Nuh Mehmet Elmadag², Turan Aslan¹

¹Bezmialem Vakıf University, Department of Infectious Diseases and Clinical Microbiology, Istanbul, Turkey

²Bezmialem Vakıf University, Department of Orthopaedics and Traumatology, Istanbul, Turkey

*Corresponding author: Bahadır Ceylan, Bezmialem Vakıf University, Department of Infectious Diseases and Clinical Microbiology, Istanbul, Turkey. Tel: +90-5301436555, Fax: +90-2124531700, E-mail: yaseminakkoyunlu@gmail.com.

Received: June 18, 2012; Revised: January 26, 2013; Accepted: May 21, 2013

Non typhoidal Salmonellae spp. causes clinical symptoms especially in neonates, infants, aged and immunocompromised patients. Hematogenous dissemination may occur in complicated cases whereas the formation of abscess is rare. A 61-year old woman presented to our hospital with pain and a mass in her left arm, without fever and leukocytosis. She was using methotrexate, corticosteroids and quinine for rheumatoid arthritis. She had a history of cervix cancer and was given radiotherapy and chemotherapy 3 years ago. Upon physical examination and magnetic resonance imaging, the mass was considered as an abscess and was surgically drained. Salmonella enterica spp. enterica was yielded in the culture of the drainage material. Ceftriaxone 2g/day was started intramuscularly and continued for 4 weeks. Salmonellosis is usually a self-limited disease, generally restricted to gastrointestinal tract and acquired following food poisoning. Management of Salmonella abscess requires a combination of antibiotherapy, surgical drainage and eradication of primary foci.

Keywords: Salmonellosis Infections; Abscess; Arthritis, Rheumatoid

1. Introduction

Non-typhoidal Salmonellae spp. generally causes a self-limiting enterocolitis in immunocompetent individuals. Up to 5% of these patients develop secondary bacteremia. This microorganism can persist in the gastrointestinal tract after diarrheal illness [1]. So-called primary non-typhoidal Salmonellae bacteremia, without associated diarrhea, occurs mainly in at risk groups such as neonates, infants, aged and immunocompromised patients due to malignancy, steroid use, HIV infection, chronic renal and liver diseases, diabetes or inherited immunodeficiencies. Hematogenous dissemination may occur in complicated cases whereas the formation of abscess is rare [1, 2].

2. Case Presentation

A 61-year old woman presented to our hospital with pain and a mass in her left arm. The patient's medical history revealed that the mass appeared approximately 6 months ago, and reached the size of a grapefruit in the past two months. She had a history of cervix cancer and was given radiotherapy and chemotherapy 3 years ago, and she was using methotrexate 10 mg/week, prednisolon 5 mg/day and hydroxychloroquine 200 mg/day for rheumatoid arthritis for the past 8 years. She had no history of trauma, fever or gastrointestinal infection. Her physical examina-

tion was normal except for the mass about 10x12 cm in the middle left arm. Upon admission, the patient did not have fever, and her axillary body temperature was 36.8 °C. Laboratory analyses revealed white blood cell count of 7.000/mm³ (82% polymorphonuclear leukocytes), hemoglobin level of 10.8 g/dL, erythrocyte sedimentation rate (ESR) of 37 mm/hour, and C-reactive protein (CRP) level of 4.2 mg/dL. Her ESR was 28 mm/h and CRP level was 1.3 mg/dL during control visit for rheumatoid arthritis approximately three months before. Since the patient had a positive malignancy history, magnetic resonance imaging of the left arm was performed and the mass was considered as an abscess that was then surgically drained (Figure 1).

Salmonella enterica spp. enterica was yielded in the culture of the abscess drainage material. Automated system VITEK2 (bioMérieux, Marcy l'Etoile, France) - GN-N91 card was used for the identification of the microorganism and antibiogram testing. Isolates were found to be susceptible to ampicillin, ceftriaxone, and trimethoprim-sulfamethoxazole; and resistant to cefuroxime and ciprofloxacin. Gruber Widal test was positive at 1/20 titer for Salmonella paratyphi BO. According to antibiotic susceptibility test results, parenteral (intramuscular) ceftriaxone at a dose of 2 g/day was initiated. At the end of 2 weeks, it was switched to oral cefixime treatment that lasted an additional 2 weeks completing a total of

Implication for health policy/practice/research/medical education:

Salmonella infections can be seen in a variety of clinical symptoms. Muscle abscess is a rare form of these clinics which must be remembered in endemic regions.

Copyright © 2013, Iranian Red Crescent Medical Journal; Licensee Kowsar Ltd. This is an Open Access article distributed under the terms of the Creative Commons Attribution License (<http://creativecommons.org/licenses/by/3.0>), which permits unrestricted use, distribution, and reproduction in any medium, provided the original work is properly cited.

4 weeks of antibiotic therapy. At the end of the therapy, no clinical, laboratory and radiological pathology was detected.

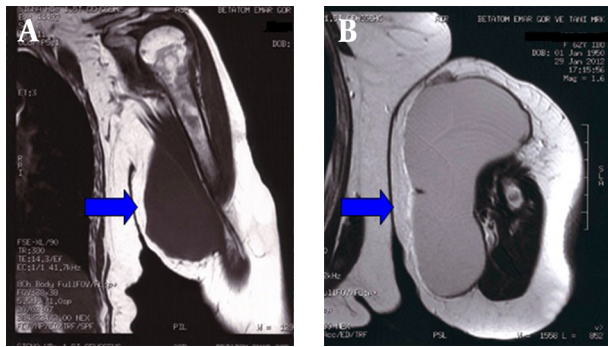


Figure 1. The Images of Left Arm Abscess in Coronal (a) and Axial Planes (b)

3. Conclusions

Pyomyositis is the pyogenic infection of the skeletal muscles usually involving the lower, enteric fever, bacteremia, and chronic carriers (3, 4). In addition, Salmonellosis frequently causes infection limited to the gastrointestinal system after extremities, and rapidly progresses to develop an abscess. It usually presents with high fever and muscle pain (5). The most common cause of pyomyositis is *Staphylococcus aureus* (66-90 %), and *Salmonella* spp. is among the pathogens for reported only in cases series (6). Salmonellosis remains a major health problem especially in developing countries. *Salmonella* consists of approximately 1700 serotypes, and each serotype may cause gastroenteritis food poisonings, and generally is a self-limiting disease. Bacteremia occurs in 5-45% of the patients (7). It was reported that spread of microorganisms with bacteremia may lead to complications such as meningitis, brain abscess, septic arthritis, liver abscess, parotid abscess and muscle abscess (3, 4, 7). Focal or metastatic salmonellosis represents 6% of non-typhi *Salmonella* infections and occurs in risk groups and patients with structural abnormalities, such as valvular disease, aneurysms or atherosclerosis, biliary or urinary tract abnormalities, bone abnormalities or prostheses (1, 6).

Soft tissue infections are rarely seen and consists 6-12 % of focal *Salmonella* infections. Management of *Salmonella* abscess requires a combination of antibiotherapy, surgical drainage and eradication of the primary foci (6). Suppression of the immune system is a risk factor for extraintestinal Salmonellosis. Sick cell anemia, diabetes mellitus, atherosclerosis, human immunodeficiency virus (HIV) infection, malignancy, chemotherapy, systemic lupus erythematosus and long term high dose steroid use are reported risk factors for invasive salmonellosis and bone-joint involvement (8-10). *Salmonella* is a well-

known cause of endovascular infections such as mycotic aortic aneurysm in different anatomical regions. Atherosclerotic plaques containing a variety of phagocytic cells are assumed to be preferable for *Salmonella*, having ability to live and reproduce in macrophages (10). It is considered in our patient that this muscle abscess occurred as a result of infection in the atherosclerotic plaque during transient bacteremia.

In our patient, because of the underlying diseases, the antibiotic treatment was completed to 4 weeks with consecutive 3rd generation cephalosporins in order to prevent recurrence despite surgical drainage of the abscess. Reports of *Salmonella* isolates resistant to 3rd generation cephalosporins directed to new treatment options and quinolones were started to be preferred. However, as seen in our patient, the occurrence of ciprofloxacin resistance, suggests alternative antibiotics such as carbapenems might come into prominence in the next years. Increasing antimicrobial resistance to fluoroquinolones and extended spectrum cephalosporins among clinical *Salmonella* isolates is becoming a serious problem, especially in Asia. The majority of antibiotics that demonstrate in vitro antimicrobial activity cannot cure *Salmonella* infections due to their limited intracellular penetration. Novel drugs with good both intracellular and extracellular antibacterial activity are urgently needed (10). Tigecycline has been shown to achieve high intracellular concentrations and exhibits a promising survival outcome compared with traditional ceftriaxone therapy in an animal model (11). In another animal study, ertapenem also was shown to be at least as effective as ceftriaxone (10). In the presence of conditions which suppress the immune system, low titers of positive serological tests may be seen and efforts should be made to the isolation of the agent. *Salmonella* infections should be considered in the differential diagnosis in endemic areas due to delayed or inappropriate treatments leading to serious complications.

Acknowledgements

None declared.

Authors' Contribution

Akkoyunlu Y, Ceylan B, Iraz M, Elmadag N M, Aslan T. Muscle Abscess due to *Salmonella* Enterica. Iran Red Cres Med J. 2013; 15(12): in press. DOI: 10.5812/ircmj.6852

Financial Disclosure

None declared.

Funding Support

None declared.

References

1. Feasey NA, Dougan G, Kingsley RA, Heyderman RS, Gordon MA. Invasive non-typhoidal salmonella disease: an emerging and neglected tropical disease in Africa. *Lancet*. 2012;**379**(9835):2489-99.
2. Moraitou E, Karydis I, Nikita D, Falagas ME. Case report: parotid abscess due to *Salmonella enterica* serovar Enteritidis in an immunocompetent adult. *Int J Med Microbiol*. 2007;**297**(2):123-6.
3. Olut AI, Avci M, Ozgenc O, Altay T, Coskuner SA, Ozsu Caymaz S, et al. [Septic arthritis of hip due to *Salmonella* Typhi in a patient with multiple sclerosis]. *Mikrobiyol Bul*. 2012;**46**(1):113-6.
4. Gomceli I, Gurer A, Ozdogan M, Ozlem N, Aydin R. *Salmonella* typhi abscess as a late complication of simple cyst of the liver: a case report. *Turk J Gastroenterol*. 2006;**17**(2):151-2.
5. Wong VK, Lissack ME, Turmezei TD, Maitland JA. *Salmonella* pyomyositis complicating sickle cell anemia: a case report. *J Med Case Rep*. 2010;**4**:198.
6. Collazos J, Mayo J, Martinez E, Blanco MS. Muscle infections caused by *Salmonella* species: case report and review. *Clin Infect Dis*. 1999;**29**(3):673-7.
7. Kuruvath S, Basu S, Elwitigala JP, Yaneza A, Namnyak SS, Aspoas AR. *Salmonella enteritidis* brain abscess in a sickle cell disease patient: case report and review of the literature. *Int J Infect Dis*. 2008;**12**(3):298-302.
8. Metan G, Alp E, Esel D, Aygen B, Sumerkan B. [*Salmonella enteritidis*: an unusual meningitis agent in an adult patient]. *Mikrobiyol Bul*. 2005;**39**(4):509-12.
9. Ortiz-Neu C, Marr JS, Cherubin CE, Neu HC. Bone and joint infections due to *Salmonella*. *J Infect Dis*. 1978;**138**(6):820-8.
10. Bjorkman P, Nilsson A, Riesbeck K. A pilot with pain in his leg: thigh abscess caused by *Salmonella enterica* serotype Brandenburg. *J Clin Microbiol*. 2002;**40**(9):3530-1.
11. Tang HJ, Ko WC, Chen CC, Chen PL, Toh HS, Weng TC, et al. In vitro and in vivo intracellular killing effects of tigecycline against clinical nontyphoid *Salmonella* isolates using ceftriaxone as a comparator. *Antimicrob Agents Chemother*. 2011;**55**(6):2755-9.