

## CASE REPORT

**Delirium as the first clinical presentation of the coronavirus disease 2019 in an older adult**Pinar SOYSAL <sup>1</sup> and Osman KARA<sup>2</sup><sup>1</sup>Department of Geriatric Medicine, Bezmialem Vakif University and<sup>2</sup>Department of Hematology, Bahcesehir University Medical Park Goztepe Hospital, Istanbul, Turkey**INTRODUCTION**

The coronavirus disease 2019 (COVID-19) outbreak, which started in China in December 2019 and spread all over the world, affects people from all age groups, but it is more fatal in the elderly. The most common clinical presentations of COVID-19 in the elderly are fever, dry cough, and chest distress, with a frequency of 94.5%, 69.1%, and 63.9%, respectively.<sup>1</sup> However, many hospitals screened for COVID-19 based on the presence of only fever and cough. Therefore, elderly patients with these symptoms did not necessarily meet the criteria for screening, although it is well known in geriatric practice that older people do not always have a fever response to infectious diseases. In elderly patients, common infections, such as pneumonia and urinary tract infections, sometimes present only as acute mental state changes such as latergia and confusion.<sup>2</sup> As with other infections, it is quite possible that COVID-19 can have this type of atypical presentation, but there is not yet any relevant information in the literature. In published studies that have investigated the clinical findings of elderly patients with COVID-19, atypical presentations have not been addressed. Here, we present a case of an elderly male patient with COVID-19 who had atypical presentation.

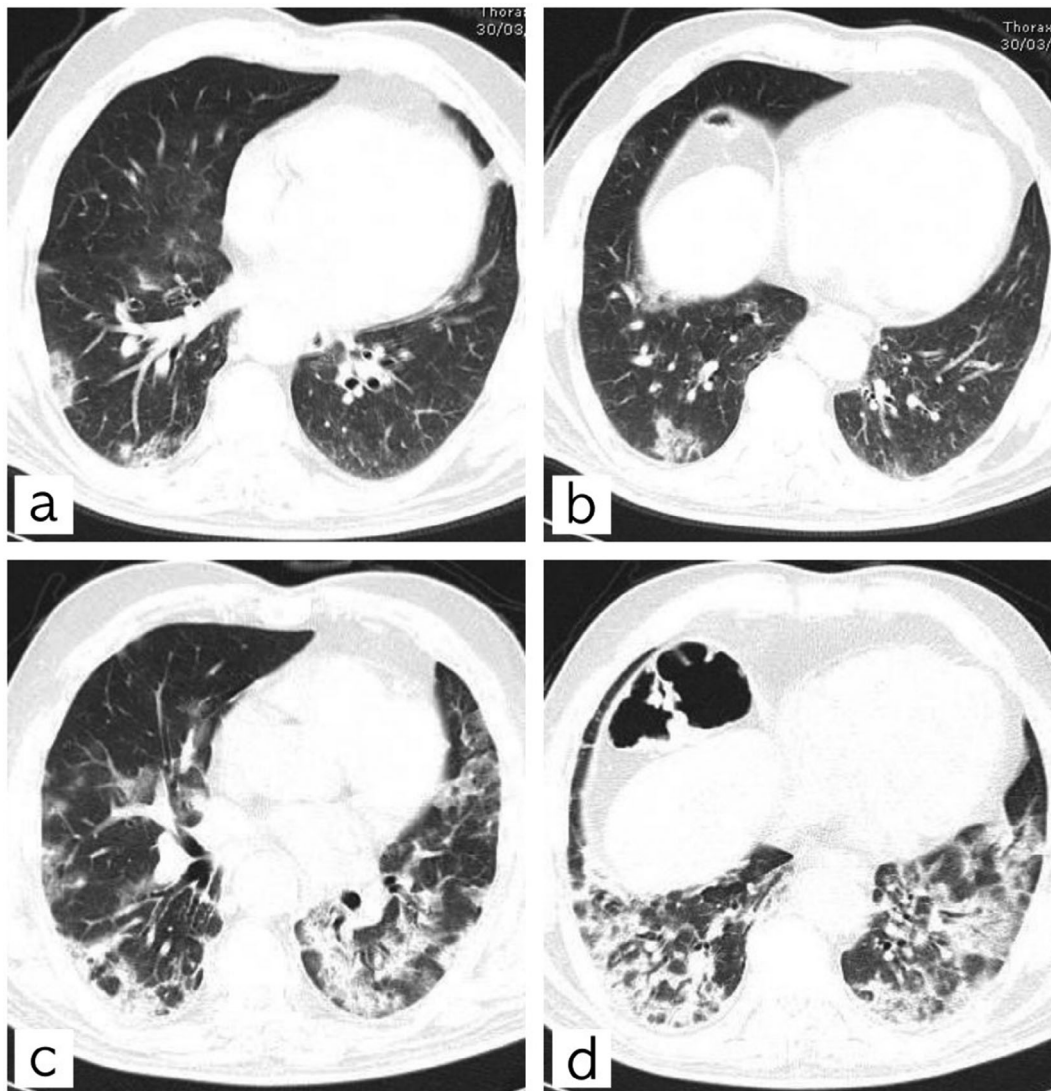
**CASE PRESENTATION**

The patient was a 70-year-old man who the patient presented with delirium out any complaints. However, the previous day, his 61-year-old wife had had a fever of 38.5°C, the findings of chest computed tomography (CT) were consistent with COVID-19, and a polymerase chain reaction (PCR) test was positive for COVID-19. The patient had been in close contact with his wife and was called for screening.

Although he had no complaints such as fever, cough, or weakness, his wife said that for 3 days he had been distracted and experiencing forgetfulness, had had difficulties using the phone and television remote control, and had described events as if they had happened in the past. Because these conditions did occur consistently and they feared exposure to COVID-19, he did go the hospital for testing. He had no known cognitive deficiency or comorbid disease did not take any medication regularly.

Physical examination showed a heart rate of 81 beats per minute, a respiration rate of 17 breaths per minute, and a body temperature of 36.9°C. All systemic examinations were normal. Assessment of mental condition revealed cognitive and perception problems, with disturbances in memory and orientation. He gave short answers to questions during the interview. Like his wife, the patient underwent chest CT and PCR testing, and the findings—specifically, areas of localized ground glass density in the right lower lung on CT (Fig. 1a,b)—and test results indicated that the patient had COVID-19. The patient was then hospitalized.

Brain CT excluded cranial pathology due to acute mental alteration. Based on these clinical findings and symptoms, the newly developed clinical picture was thought to be delirium. The patient's pulse oximeter oxygen saturation was 97% at rest. He had a sinus rhythm electrocardiogram with no pathological characteristics. Biochemistry showed normal liver, thyroid, and kidney functions. Haemogram indicated that white blood cell count was 1000/uL, lymphocyte 900/uL, and platelets 73 000. D-dimer was 349.61 ng/mL (normal: 0–500 ng/mL), C-reactive protein was 7.74 mg/L (normal: 0.1–8.2 mg/L), and ferritin level was 4.63–204 ng/mL. Hydroxychloroquine, azithromycin, and Enfluvir were initiated in the patient.



**Figure 1** Chest computed tomography findings of the patient. (a, b) CT findings on the day the patient first admitted to the hospital. (c, d) CT findings on 12th day of hospitalization.

On the fifth day of hospitalization, the patient's fever and oxygen saturation decreased, and blood and urine cultures were taken. The cultures were negative, and procalcitonin level was within the normal range; subsequently, favipiravir and then tocilizumab, prednisolone, and enoxaparin were administered. On the 12th day of hospitalization, because of increased dyspnoea, the patient underwent chest CT, and progression of COVID-19 pneumonia was observed in all lobes of the lungs, with the effects being most prominent in the bilateral lower lobes (Fig. 1c,d). During this period, the patient's lymphocyte count dropped to 300/uL; his D-dimer, C-reactive protein and ferritin

levels increased; and he continued to receive treatment in the delirium clinic. With tocilizumab treatment, the patient, who had a fever only once during hospitalization, had a dramatic improvement in all symptoms and laboratory parameters, including impaired mental status. He was discharged with enoxaparin prophylaxis after 14 days in hospital.

## DISCUSSION

Although diseases are much more common in the elderly, classic presentation symptoms may not always occur. Therefore, diagnosis and appropriate

treatment may be delayed, and the severity of the disease can be masked. For example, massive pulmonary embolism does not cause dyspnoea or other respiratory symptoms, and it can cause only hypoactive delirium.<sup>3</sup> With age-related changes in immunity, the febrile response may be absent in infected older adults; it is well known that the absence of fever in a disease known to cause fever is the most common atypical presentation.<sup>2</sup> Beyond this, it is important to recognize that elderly patients with serious infections, such as sepsis and COVID-19 pneumonia, can present with only non-specific and atypical symptoms such as altered mental state, weight loss, fatigue, falls, dizziness, and functional decline.<sup>4</sup>

In the present case, the patient deteriorated to the point that intubation was almost necessary; however, fever was detected only once, and the first symptom of the disease was a change in mental state. If it had not been known that this patient had been in close contact with someone with COVID-19 (i.e. his wife), neither chest CT nor PCR would have been performed because his symptoms did not meet national criteria for COVID-19 testing (i.e. fever and cough). However, studies have reported that older patients with atypical presentations have worse clinical outcomes, which often require longer hospital stays.<sup>4</sup> This was true in the present case: the patient, who

developed delirium, had a long and difficult recovery, whereas his wife, who presented with a high fever, ultimately had mild symptoms compared to her husband.

To prevent delaying the diagnosis of COVID-19 in older adults, a more complex and detailed evaluation is needed than that used by the classic medical model. For elderly patients, a revised model may offer more sustainable and successful disease management generally and specifically in cases of COVID-19.

## REFERENCES

- 1 Chen T, Dai Z, Mo P *et al*. Clinical characteristics and outcomes of older patients with coronavirus disease 2019 (COVID-19) in Wuhan, China (2019): a single-centered, retrospective study. *J Gerontol A Biol Sci Med Sci* 2020. <https://doi.org/10.1093/gerona/glaa089>.
- 2 Limpawattana P, Phungoen P, Mitsungnern T, Laosuankoon W, Tansangworn N. Atypical presentations of older adults at the emergency department and associated factors. *Arch Gerontol Geriatr* 2016; **62**: 97–102. <https://doi.org/10.1016/j.archger.2015.08.016>.
- 3 Soysal P, Isik AT. Hypoactive delirium caused by pulmonary embolus in an elderly adult. *J Am Geriatr Soc* 2014; **62**: 586–587. <https://doi.org/10.1111/jgs.12720>.
- 4 Hofman MR, van den Hanenberg F, Sierevelt IN, Tulner CR. Elderly patients with an atypical presentation of illness in the emergency department. *Neth J Med* 2017; **75**: 241–246.