



Multifocal, Non-Human Papillomavirus Inflammatory Papillary Hyperplasia: A Rare Case Report

Multifokal, HPV Olmayan Enflamatuvar Papiller Hiperplazi: Nadir Bir Olgu Sunumu

Özge DOĞANAY¹, Taha AKTAŞ¹, Doğan DOLANMAZ¹, Tuğçe KIRAN²

¹Bezmiâlem Vakıf University Faculty of Dentistry, Department of Oral, Dental and Maxillofacial Surgery, İstanbul, Turkey

²Bezmiâlem Vakıf University Faculty of Dentistry, Department of Medical Pathology, İstanbul, Turkey

ABSTRACT

Oral papillary lesions include a variety of reactive, developmental, and neoplastic conditions. Inflammatory papillary lesions almost involve the hard palate and are usually associated with the use of ill-fitting dentures and poor oral hygiene. Contrarily, perioral involvement of papillomatosis can also be found in neoplastic or syndromic conditions. This case report aimed to present a 44-year-old male patient with rarely encountered multifocal non-human papillomavirus (HPV) inflammatory papillary hyperplasia and evaluate the differential diagnosis that represents similar clinical and histopathological conditions. Multifocal papillary lesions on the lips, tongue, alveolar crest, and oral mucosa were surgically removed via scalpel and laser application. The histopathologic examination confirmed the diagnosis of non-HPV inflammatory papillary hyperplasia. Complete recovery was achieved and the patient was rehabilitated with a new removable prosthesis. Surgical removal of the papillary lesions seems to be a reliable treatment option. In addition to HPV-induced lesions and poor oral hygiene, other etiologic factors should be eliminated with clinicopathologic consultation and genetic investigations.

Keywords: Inflammatory papillary hyperplasia, human papillomavirus, multifocal, surgical removal, laser, the non-denture wearer

ÖZ

Oral papiller lezyonlar çeşitli reaktif, gelişimsel ve neoplastik durumlardan oluşur. Enflamatuvar papiller lezyonlar neredeyse tamamen sert damağı tutar ve genellikle uygun olmayan protezlerin kullanımı ve kötü ağız hijyeni ile ilişkilidir. Diğer tarafta, papillomatozun perioral tutulumu neoplastik veya sendromik durumlarda da bulunabilir. Olgu raporunun amacı, nadiren karşılaşılan multifokal non-human papillomavirüs (HPV) enflamatuvar papiller hiperplazili 44 yaşında bir hasta hastayı sunmak ve benzer klinik ve histopatolojik durumları temsil eden farklı tanıları değerlendirmektir. Ağız mukozası, dudak, dil ve alveol kretlerde tespit edilen multifokal papiller lezyonlar cerrahi olarak bistüri ve lazer uygulaması ile çıkarıldı. Histopatolojik inceleme HPV olmayan enflamatuvar papiller hiperplazi tanısını doğruladı. Tam iyileşme sağlandı ve hasta yeni bir hareketli protez ile rehabilite edildi. Papiller lezyonların cerrahi olarak çıkarılması güvenilir bir tedavi seçeneğı gibi görünmektedir. HPV'ye bağılı lezyon ve kötü ağız hijyeninin yanı sıra diğeri etiyojik faktörler klinikopatolojik konsültasyon ve genetik arařtırmalarla elimine edilmelidir.

Anahtar Sözcükler: Enflamatuvar papiller hiperplazi, human papilloma virüs, multifokal, cerrahi eksizyon, lazer, hareketli protez kullanımı

Address for Correspondence: Taha AKTAŞ, Bezmiâlem Vakıf University Faculty of Dentistry, Department of Oral, Dental and Maxillofacial Surgery, İstanbul, Turkey

E-mail: taitaha.aktas@hotmail.com **ORCID ID:** orcid.org/0000-0001-9378-020X

Cite this article as: Doğanay Ö, Aktaş T, Dolanmaz D, Kiran T. Multifocal, Non-Human Papillomavirus Inflammatory Papillary Hyperplasia: A Rare Case Report. Bezmiâlem Science 2022;10(1):106-10

©Copyright 2022 by the Bezmiâlem Vakıf University

Bezmiâlem Science published by Galenos Publishing House.

Received: 06.12.2020

Accepted: 02.08.2021

Introduction

Oral papillary hyperplasia (OPH) is a benign lesion of the oral mucosa that is characterized by the presence of numerous wart-like, red nodular growths of the affected mucosa. Papillary lesions include a variety of reactive, developmental, and neoplastic conditions and are histopathologically described as papillary projections that are covered by stratified squamous epithelium with or without chronic inflammation. The clinical features of this lesion are well-established. The histologic samples of the lesion are currently believed to have a predominantly inflammatory nature, although fewer pathologists are familiar with its malignancy potential (1).

The etiopathogenesis is unclear; however, OPH is associated with the long-term use of removable dentures, poor oral hygiene, age, human papillomavirus (HPV), and systemic disorders but can also be found in patients with dentures without a history of removable prostheses (2). OPH is also associated with *Candida* colonization due to poor oral hygiene, but *Candida* is solely not a factor for the onset of symptoms. The lesion almost exclusively involves the hard palate, as well as the upper and lower lips, alveolar crest, gingiva, and tongue in rare circumstances. The lesion is generally asymptomatic (3).

This report aimed to present a case of a rarely encountered multifocal non-HPV inflammatory papillary hyperplasia and discuss other differential diagnoses, which represent similar clinical and histopathological conditions.

Case Report

A 44-year-old male patient was referred to the Department of Oral and Maxillofacial Surgery, at the faculty of dentistry, Bezmalem Vakif University with a chief complaint of papillary lesions on the lips and tongue. The medical history of the patient revealed that wart-like lesions on the lips and hands were first diagnosed 15 years ago and were treated with cryotherapy. The patient had

two heart attacks at intervals of 3 months in 2015 and underwent stent operations after the coronary angiography. The pre-prandial blood glucose level of the patient was recorded as 130 mg/dL. The patient receives metformin hydrochloride of 1,000 mg per day for diabetes mellitus treatment and acetylsalicylic acid of 100 mg per day for stent thrombosis prophylaxis.

The patient mainly complained about esthetic and function. Clinical examination revealed no history of wearing a removable prosthesis and multifocal papillary projections on the lips, tongue, and alveolar mucosa. Radiological examination revealed no bony involvement of nearby lesions. Multifocal lesions were asymptomatic. Clinical manifestations of the lesion are presented in Figure 1.

Histopathologic Examination

The biopsy specimen with the provisional diagnosis of HPV-induced OPH was obtained and sent for histopathologic examination. The microscopic features of the inflammatory papillary hyperplasia were verified. The lesion showed numerous papillary growths of the oral mucosa that were covered by parakeratotic stratified squamous epithelium. The connective tissue forms the cores of the papillary growths presented edema, vascular proliferation, and low-grade chronic inflammatory cell infiltration (Figure 2). *Candida* colonization was investigated using Grocott-Gomori's Methenamine Silver Staining (Figure 3), which identified no signs of *Candida* infection. The diagnosis of HPV-induced lesion was also eliminated by in situ hybridization (Figure 4).

The patient has undergone excisional biopsy and then, laser therapy was applied to the base of the lesion for stable and healthy mucosa for the prosthetic rehabilitation of the jaws. The hyperemic and papillary formations were resolved within a month (Figure 5). Removable prosthetic rehabilitation of the upper and lower jaw was achieved after a 2-month healing period.

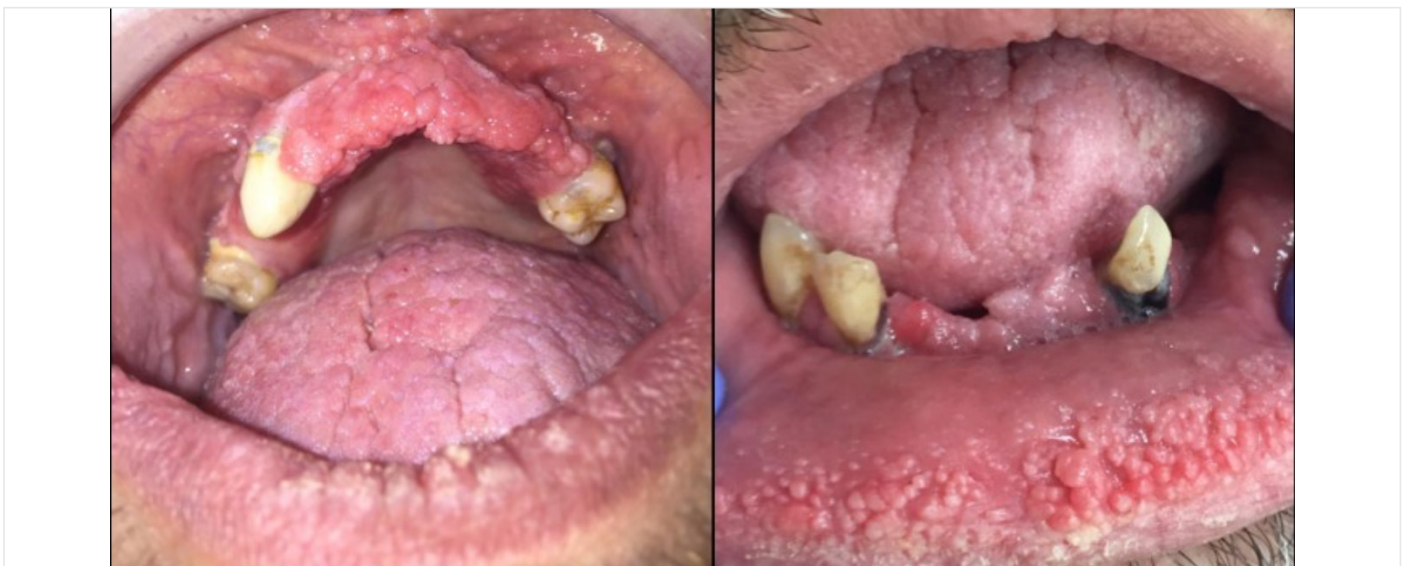

Figure 1. Clinical manifestations of the multifocal epithelial hyperplasia on the upper and lower jaws, lips, and tongue

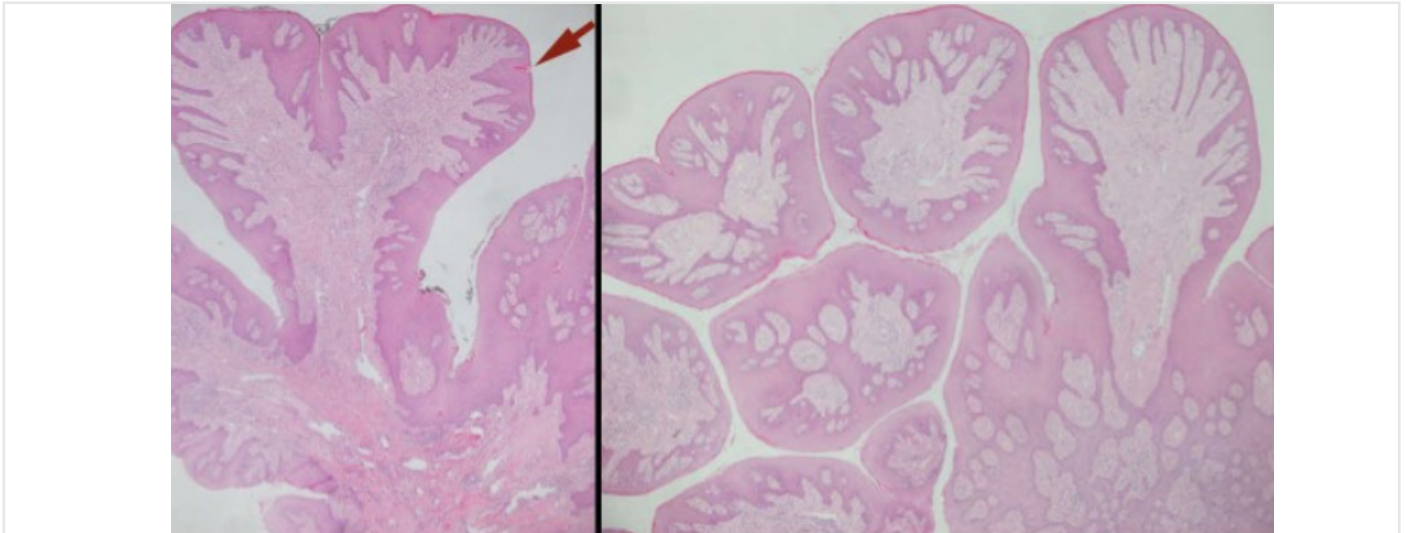


Figure 2. Numerous papillary growths (red arrow) of the oral mucosa that were covered by parakeratotic stratified squamous epithelium and edema, vascular proliferation, and low-grade chronic inflammatory cell infiltration in the connective tissue



Figure 3. Grocott-Gomori's Methenamine Silver Staining to identify *Candida* colonization

Discussion

The treatment type for OPH is associated with clinical manifestation and histopathological verification. A concern arises regarding the malignancy potential of OPH; however, the treatment modalities mostly include denture removal as conservative therapy, as well as electrocauterization, cryotherapy, surgical removal of the lesion, or complete excision. The denture removal can eliminate the edema and hyperemia; however, the connective tissue cannot be removed with conservative treatment (4). Non-invasive and superficial lesions can be treated with mouth rinse or denture removal. Clinicians have recommended that aggressive and

extensive papillary lesions can be treated with excision, laser, electrosurgery, or cryotherapy (4,5).

The etiologic factors revealed several causes that are associated with OPH. Night-time use of ill-fitting dentures and poor oral hygiene has been reported as frequent causes, but OPH has also been found in patients with no history of wearing a removable denture (6). Some authors have reported HPV-driven infections of the oral mucosa, which represent a similar clinical appearance with OPH (7).

In addition to HPV-induced and removable denture-related lesions, oral papillary lesions also include a variety of developmental and neoplastic origins. Differential diagnoses are made with verruciform xanthoma, Costello syndrome, and paraneoplastic conditions as malignant acanthosis nigricans (8). The histological features of verruciform xanthoma are similar to OPH. A papillary proliferation of stratified squamous epithelium that is associated with hyperparakeratosis is usually encountered. The outstanding characteristic feature of these lesions includes the presence of xanthoma-like cells (foamy lipid-laden histiocytes) and the biopsy specimen shows cytoplasmic immunopositivity (CD69, CD63, and CD163) (9,10).

Hyperemic papillary growths usually begin on the palatal surface, and then extend to the entire hard palatal mucosa. However, perioral involvement of papillary lesions can be found in neoplastic or syndromic conditions. Acanthosis nigricans, which is a variety of paraneoplastic conditions associated with gastrointestinal malignancy, shows a characteristic of florid papillomatosis of the lips, labial commissures, or oral mucosa. Perioral papillomatosis was also reported in patients with Costello syndrome (8).

Multifocal inflammatory papillary hyperplasia is a rare condition and its pathogenesis remains unclear. Multifocal localization of papillary lesions in non-denture wearers can be a challenging issue

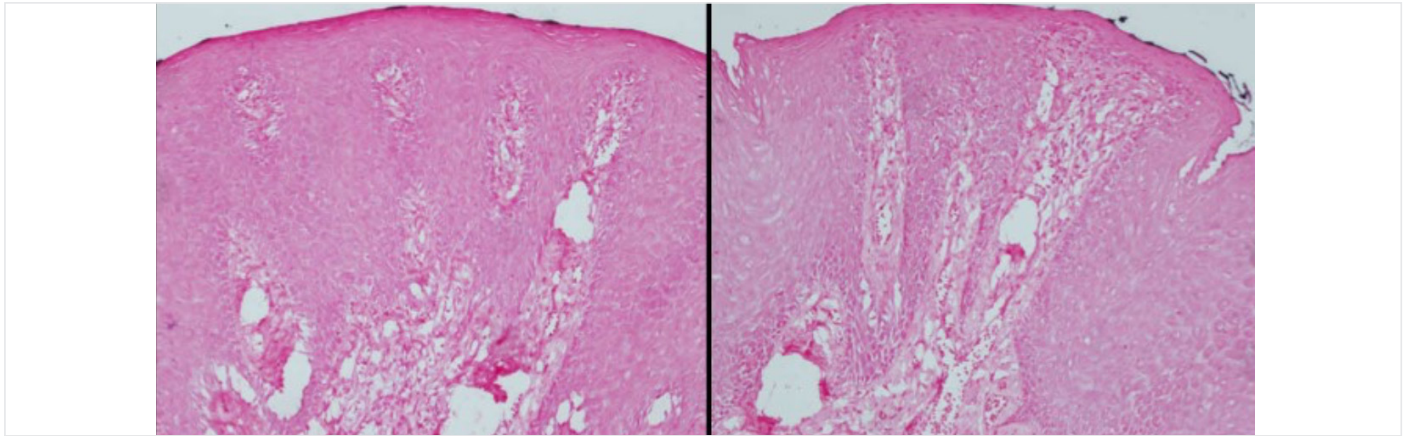


Figure 4. In situ hybridization to identify HPV

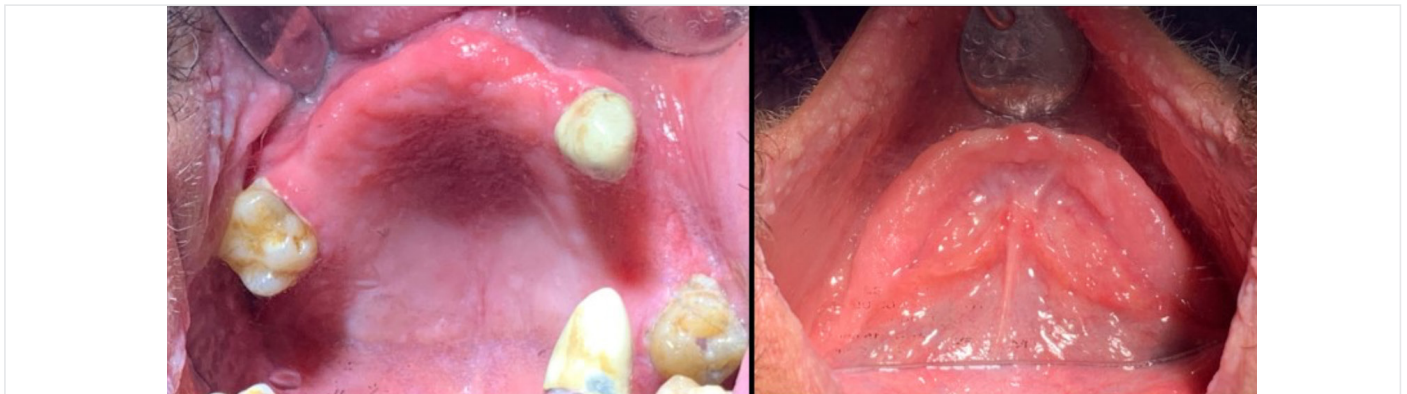

Figure 5. Clinical manifestations of a healthy oral mucosa after a 2-month healing period

in disease diagnosis and patient management. Clinicopathologic correlation and collaboration can prevent diagnostic pitfalls. Differential diagnosis should be rendered by the pathologist and clinicians based on the histopathologic and clinical presentations of the lesion. In this patient, malignant conditions and HPV-induced lesions were excluded via histopathologic and immunohistochemical analysis. The patient will undergo further genetic investigations.

Ethics

Informed Consent: Obtained.

Peer-review: Externally peer reviewed.

Authorship Contributions

Surgical and Medical Practices: Ö.D., T.K., D.D., Concept: Ö.D., Design: D.D., Data Collection or Processing: T.A., Analysis or Interpretation: Ö.D., D.D., Literature Search: Ö.D., Writing: Ö.D.

Conflict of Interest: No conflict of interest was declared by the authors.

Financial Disclosure: The authors declared that this study received no financial support.

References

1. Madani FM, Kuperstein AS. Normal variations of oral anatomy and common oral soft tissue lesions: evaluation and management. *Med Clin N Am* 2014;98:1281-98.
2. Orenstein NP, Taylor TA. Nonsurgical approach to treating aggressive inflammatory papillary hyperplasia: Clinical report. *J Prosthet Dent* 2014;111:264-8.
3. Stoopler ET, Ojeda D, Elmuradi S, Sollecito TP. Lymphoid hyperplasia of the tongue. *J Emerg Med* 2016;50:155-6.
4. Gual-Vaques P, Jane-Salas E, Egido-Moreno S, Ayuso-Montero R, Mari-Roig A, Lopez-Lopez J. Inflammatory papillary hyperplasia: a systematic review. *Med Oral Patol Oral Cir Bucal* 2017;22:36-42.
5. Infante-Cossio P, Martinez-de-Fuentes R, Torres-Carranza E, Gutierrez-Perez JL. Inflammatory papillary hyperplasia of the palate: treatment with carbon dioxide laser, followed by restoration with an implant-supported prosthesis. *Br J Oral Maxillofac Surg* 2007;45:658-60.
6. Gual-Vaques P, Jane-Salas E, Mari-Roig A, Lopez-Lopez J. Inflammatory papillary hyperplasia in a non-denture-wearing patient: a case history report. *Int J Prosthodont.* 2017;30:80-2.
7. Rohwedder A, Murphy M, Carlson JA. HPV in verruciform xanthoma-sensitivity and specificity of detection methods and multiplicity of HPV types affect results. *J Cutan Pathol* 2003;30:219-20.

8. Mainville GN. Non-HPV Papillary Lesions of the Oral Mucosa: Clinical and Histopathologic Features of Reactive and Neoplastic Conditions, *Head Neck Pathol* 2019;13:71-9.
9. Andrade BA, de Andrade BA, Agostini M, Pires FR, Rumayor A, Carlos R, de Almeida OP, et al. Oral verruciform xanthoma: a clinicopathologic and immunohistochemical study of 20 cases. *J Cutan Pathol* 2015;42:489-95.
10. Zak A, Zeman M, Slaby A, Vecka M. Xanthomas: Clinical and pathophysiological relations. *Biomedical papers of the Medical Faculty of the University Palacky. Olomouc Czechoslov* 2014;158:181-8.