

Received: 2017.12.16
Accepted: 2018.02.01
Published: 2018.02.25

Comparison of Cytotoxic Effects of Intra-Articular Use of Tranexamic Acid versus Epinephrine on Rat Cartilage

Authors' Contribution:
Study Design A
Data Collection B
Statistical Analysis C
Data Interpretation D
Manuscript Preparation E
Literature Search F
Funds Collection G

CDEF 1 Erhan Sukur
AB 2 Fatih Kucukdurmaz

1 Department of Orthopedics and Traumatology, Sakarya Research and Training Hospital, Sakarya, Turkey
2 Department of Orthopedics and Traumatology, Bezmialem Vakif University, Istanbul, Turkey

Corresponding Author: Erhan Sukur, e-mail: erhan_sukur@hotmail.com
Source of support: Bezmialem Vakif University Institutional Research Fund

Background: Adequate visualization is known to be essential to perform arthroscopic procedures effectively and efficiently. We hypothesized that tranexamic acid may be considered as an alternative agent to reduce intra-articular bleeding during arthroscopic procedures, after comparing its potential chondrotoxicity with that of epinephrine.

Material/Methods: Seventy-two rats were randomized into 3 groups with 24 rats each. The injections were performed in the right knees, as follows: Group 1: 0.25 mL of tranexamic acid solution, Group 2: 0.25 mL of epinephrine solution, and Group 3: 0.25 mL of 0.9% saline, serving as control. One week after the injections, the animals were euthanized. Samples were evaluated histologically based on the Osteoarthritis Research Society International (OARSI) Histopathology Grading and Staging System and the "live/dead" staining technique to determine chondrocyte viability.

Results: Comparison of epinephrine and tranexamic acid revealed significantly higher OARSI scores in the epinephrine group (epinephrine: 3.42 ± 1.31 , TA: 0.92 ± 0.90 ; $P < 0.001$). The most significant difference between the 2 groups was in the number of joints diagnosed with OARSI grade III. The percentage of viability was significantly higher in the tranexamic acid group when compared with the epinephrine group (tranexamic acid: 79.74 ± 3.343 ; epinephrine: 63.81 ± 1.914 ; $P < 0.05$).

Conclusions: Based on the histologic parameters and chondrocyte viability, tranexamic acid is less cytotoxic than epinephrine in rat chondrocytes at the doses typically used in irrigation fluid, and may be a good alternative to epinephrine in arthroscopic surgery.

MeSH Keywords: Arthroscopy • Chondrocytes • Epinephrine • Tranexamic Acid

Full-text PDF: <https://www.medscimonit.com/abstract/index/idArt/908560>



1767



2



2



29



Background

The role of arthroscopic procedures in the diagnosis and treatment of a wide variety of joint disorders is evolving. Among the many factors that determine the success of surgery and patient outcomes, adequate visualization is known to be essential to perform these procedures effectively and efficiently [1,2]. Numerous devices and surgical techniques have been developed for this purpose [2,3]. Epinephrine is a potent vasoconstrictor, frequently added to the irrigation fluid to reduce intra-articular bleeding, and thereby maintaining adequate visualization during the operation [4,5]. Recently, systemic complications, including pulmonary edema and cardiopulmonary arrest, have been reported, and they are attributed to the epinephrine in the irrigation fluid [6,7]. Moreover, there is an increasing number of *in vitro* studies showing the cytotoxic effects of epinephrine on chondrocytes, and focusing attention on the potential chondrolysis [8–10]. Thus, the presence of epinephrine in the irrigation fluid has been questioned [4,8]. Tranexamic acid (TA) is both an inhibitor of fibrinolysis and an activator of plasminogen. It is known to be effective and safe in reducing the amount of bleeding during various orthopedic interventions when administered intravenously [11,12]. Intravenous administration of TA is considered safe; however, some studies have associated intravenous TA with postoperative seizures and increased thromboembolic events [13]. Hence, the intra-articular administration of TA has been increasing over the past several years [14,15], with the benefits of higher concentration at the operative site while reducing the risk of systemic adverse effects, reduced cost, and giving more control to the surgeon [16]. However, there are few studies available on the intra-articular administration of TA, and these focus on the clinical outcomes only [17,18]. In this experimental study, we focused on investigating the effects of TA on the articular cartilage, and comparing them with the effects of epinephrine on the articular cartilage. We hypothesized that TA may be considered as an alternative agent to reduce intra-articular bleeding during arthroscopic procedures, after comparing its potential chondrotoxicity with that of epinephrine.

Material and Methods

Animals

A total of 72 adult female Sprague-Dawley rats were used, with a mean age of 12-months and weighing 250–350 g. Animals were housed under standard management conditions (5 rats/cage). The room temperature and humidity were maintained at 20–24°C and 50–60%, respectively. The light cycle was fixed at 12 hours. They were fed a standard rat diet with water *ad libitum*. All animal experiment protocols were approved by the Animal Research Committee at Istanbul Bezmialem

University Research and Training Hospital (date: 07/02/2012, id: 2012/309).

Study groups

Seventy-two rats were randomized into 3 groups with 24 rats in each. The injections were performed in the right knees, as follows: Group 1: 0.25 mL of TA solution (1 g of TA is diluted in 50 mL of saline). Group 2: 0.25 mL of epinephrine solution (50 mL of epinephrine diluted to 1: 200 000). Group 3: 0.25 mL of 0.9% saline, serving as control. One week after the injections, the animals were euthanized with high doses of intraperitoneal thiopental (200 mg/kg). Twelve specimens from each group were separated for the histological analysis and the chondrocyte viability evaluation.

Tissue preparation and histological analysis

Tibiofemoral joints of the rats were excised immediately after the rats were euthanized. Femoral condyles and tibia samples were fixed in 10% buffered formalin and decalcified in 8% formic acid. Then, the tissues were rinsed with tap water, and routine tissue processing was performed using a Shandon™ Excelsior™ tissue processor. Slices of 0.4- μ m thickness were prepared from the paraffin-embedded tissue. The slides were stained with hematoxylin and eosin and toluidine blue. Samples were evaluated histologically for the presence of inflammation and osteoarthritis grade (OARSI grades 0–6), osteoarthritis stage (OA stages 04), and osteoarthritis scoring (OA scoring: [OARSI grade] \times [OA stage]), according to the recommendation of the International Cartilage Repair Society's osteoarthritis and cartilage histopathology grading and staging system [19]. Hematoxylin and eosin stains were used to evaluate the structure, the chondrocytes, and inflammation. Loss of proteoglycan staining intensity was assessed by toluidine blue staining. The samples were examined and assessed independently by 2 blinded investigators.

Chondrocyte viability analysis

The “live/dead” or “red/green” staining technique was used, relying on cell membrane integrity and intracellular esterase activity to produce products that can be visualized on confocal microscopy [20]. Full-thickness cartilage was removed from subchondral bone and sectioned into approximately 0.5-mm-thick coronal slices. Tissues were stained with calcein-AM (Cal-AM) and ethidium homodimer (Et-HD) for 35 to 45 minutes in a nutrient medium. After staining, the tissues were rinsed 3 times with the nutrient medium, for 2 minutes each. The stained tissues were examined under a confocal microscope (Zeiss LSM 780). Three coronal slices were imaged at 3 random locations within each of the superficial, middle, and deep chondrocyte regions, for a total of 9 images per specimen. The

Table 1. Comparison of the groups according to the OARSI scores.

	Group			P
	Epinephrine	Saline	TA	
MD	3.42	0.33	0.92	<0.001
SD	1.31	0.65	0.90	
Median	3	0	1	
Percentiles	25	3	0	
	50	3	0	
	75	3.75	0.75	

OARSI – Osteoarthritis Research Society International; TA – tranexamic acid.

Table 2. Histological findings of OARSI assessment.

OARSI scores	Group						P	
	Epinephrine		Saline		TA			
	n	%	n	%	n	%		
Grade	0	0	0.0	9	75.0	4	33.3	<0.001
	1	0	0.0	3	25.0	6	50.0	
	2	3	25.0	0	0.0	1	8.3	
	3	9	75.0	0	0.0	1	8.3	
Stage	0	0	0.0	9	75.0	4	33.3	<0.001
	1	9	75.0	2	16.7	8	66.7	
	2	3	25.0	1	8.3	0	0.0	
Score	0	0	0.0	9	75.0	4	33.3	<0.001
	1	0	0.0	2	16.7	6	50.0	
	2	2	16.7	1	8.3	1	8.3	
	3	7	58.3	0	0.0	1	8.3	
	4	1	8.3	0	0.0	0	0.0	
	6	2	16.7	0	0.0	0	0.0	

Cal-AM and Et-HD stained cells were counted separately and the percentage of viability was calculated.

Statistical analysis

Inter-observer reliability was evaluated using a two-way random absolute agreement method. Data were evaluated using the SPSS for Windows 15.0 (SPSS Inc., Chicago, IL, USA) software. The independence between the groups was analyzed using the Pearson's chi-square test. In the absence of the conditions provided, Monte Carlo simulation was performed. Ordinal variables between 2 independent groups were compared by the Mann-Whitney U test. The Kruskal-Wallis and Dunn tests were used for comparing the parameters. An alpha level of 0.05 was chosen to assess statistical significance. *P*-values <0.05 were regarded as significant.

Results

Comparison of epinephrine and TA revealed significantly higher OARSI scores in the epinephrine group (epinephrine: 3.42 ± 1.31 , TA: 0.92 ± 0.90 ; $P < 0.001$), (Table 1). The most significant difference between the 2 groups was in the number of joints diagnosed with OARSI grade III. In the epinephrine group, 9 specimens showed grade III changes, whereas only 1 specimen showed grade III changes in the TA group (Table 2). Representative histological lesions assessed as grade III were: extension of matrix cracks into the mid-zone to form vertical clefts, slightly irregular surface layer, cluster of cells focally, as well as hypocellularity, chondrocyte deaths, loss of stainable proteoglycan matrix, and moderate toluidine blue staining. No specimens were determined as grade V or VI where the subchondral bone was involved. According to the calcein-AM

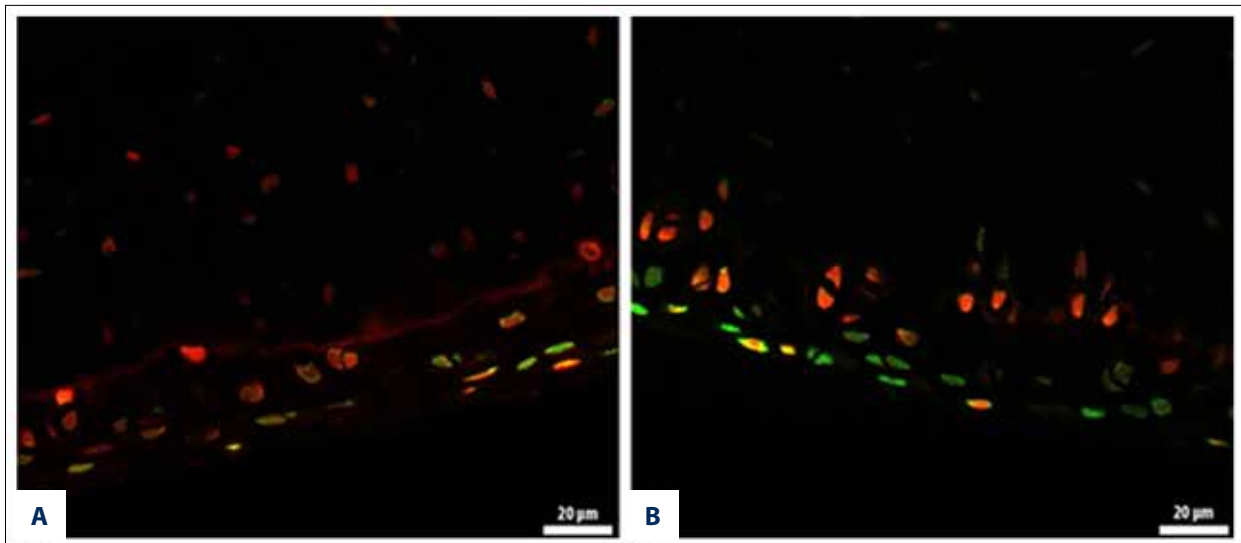


Figure 1. Calcein-AM and ethidium homodimer-1 staining of chondrocytes. The live cells are stained green, and the dead cells are stained red (A: Epinephrine group) (B: TA group).

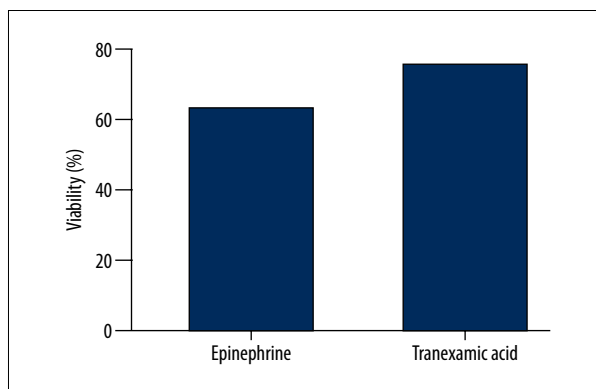


Figure 2. Viability stains in cartilage.

and ethidium homodimer-1 staining of chondrocytes, the live cells were stained green and the dead cells were stained red (Figure 1). The percentage of viability was significantly higher in the TA group compared with the epinephrine group (TA: 79.74 ± 3.343 ; epinephrine: 63.81 ± 1.914 ; $P < 0.05$) (Figure 2).

Discussion

Based on the histologic parameters and chondrocyte viability, the principal finding of this study is that TA is less cytotoxic than epinephrine in rat chondrocytes at the doses typically used in irrigation fluid, and may be a good alternative to epinephrine in arthroscopic surgery. Moreover, this study is the first to compare the cytotoxic effects of TA and epinephrine. Intra-operative bleeding during arthroscopic procedures is a challenging problem for orthopedic surgeons. Epinephrine is a potent vasoconstrictor, frequently added to the arthroscopic irrigation fluid to reduce intra-articular bleeding and thereby maintain adequate

visualization [1,4,5,21]. However, recent experimental studies have shown that epinephrine is cytotoxic to the chondrocytes and may cause chondrolysis [22]. Rao et al. demonstrated that epinephrine is toxic to chondrocytes, even at concentrations as low as 1: 1000 mL, and its addition to irrigation fluid may not be advisable [23]. Alan et al. compared the effects of low-dose (1: 3 000 000) versus high-dose (1: 300 000) epinephrine on chondrocyte viability, reporting a significant decrease in chondrocyte survivability at the doses typically used in arthroscopic irrigation fluids. They also emphasized that high-dose epinephrine results in a significant increase in chondrocyte death over a very brief period (1 hour) [24]. In this *in vitro* study, the OARSI grades were significantly higher in all epinephrine subgroups (1-hour, 24-hour, and 1-week subgroups) when compared with the control groups: a finding similar to the previous reports.

Tranexamic acid is a well-known agent that effectively suppresses bleeding in various orthopedic surgical interventions, and may be administered intravenously or topically [18,25]. Only a few studies have evaluated the outcomes of intra-articular application, and only 1 has investigated the effect of TA on the cartilage and synovial tissues [11,26,27]. Tuttle et al. conducted a study to understand the *in vitro* effects of TA on bovine cartilage and murine chondrocytes. They studied TA at 3 doses (25, 50, and 100 mg/mL), reporting that 50-mg/mL and 100-mg/mL doses of TA have a cytotoxic effect on the chondrocytes and damaged the cartilage. However, 25 mg/mL may be an effective and safe dose for intra-articular use of TA in native joints [27]. Intra-articular use of TA is a simple procedure, with the inherent advantage of inducing partial microvascular hemostasis in the area by preventing fibrin clot dissolution [28]. When injected intra-articularly, TA is rapidly absorbed in the joint fluid, with an average biological half-life of 3 hours. Thus, a high concentration inside the joint

for maximum effect can be achieved with limited systemic adverse effects [18,29]. In this experimental study, we determined the cytotoxicity by using histological parameters according to the OARSI grading-scoring system and chondrocyte viability percentage. OARSI system is a conventional histologic analysis showing changes in cartilage and synovial membrane. According to the OARSI system (in 1-week subgroups), the epinephrine group had significantly higher OARSI grades compared with the TA group. The most important cause of this significant difference in the 1-week subgroup is the greater number of chondrocyte deaths and cellular abnormalities in the epinephrine group vs. the TA group. Additionally, complex chondrins containing multiple and disoriented chondrocytes are seen as being more prominent in the epinephrine group, as described by Pritzker et al. [29]. The “live/dead” or “red/green” staining technique relies on the cell membrane integrity and provides a direct assessment of cell viability at the time of tissue harvest. This technique has been

used to determine chondrocyte viability [20]. The percentage of viability at the time of tissue harvest was significantly higher in the TA group (only in the 1-week subgroup), and corresponded well to histologic findings, when compared with the epinephrine group. This study was designed as a safety study in regards to the cartilage viability, and the efficacy of TA in used doses was not within the scope of this study. The efficacy of intra-articular TA in these doses should be assessed in future studies.

Conclusions

In conclusion, TA is less cytotoxic to rat chondrocytes than epinephrine at the doses typically used in irrigation fluid. Hence, TA may be considered as a good alternative to epinephrine for reducing intra-articular bleeding during arthroscopic procedures, and can be safely used in partial arthroplasty cases.

References:

- Jensen KH, Werther K, Stryger V et al: Arthroscopic shoulder surgery with epinephrine saline irrigation. *Arthroscopy*, 2001; 17: 578–81
- Hsiao MS, Kusnezov N, Sieg RN et al: Use of an irrigation pump system in arthroscopic procedures. *Orthopedics*, 39(3): e474–78
- Morrison DS, Schaefer RK, Friedman RL: The relationship between subacromial space pressure, blood pressure, and visual clarity during arthroscopic subacromial decompression. *Arthroscopy*, 1995; 11: 557–60
- Avery DM, Gibson BW, Carolan GF: Surgeon-rated visualization in shoulder arthroscopy: A randomized blinded controlled trial comparing irrigation fluid with and without epinephrine. *Arthroscopy*, 31(1): 12–18
- Van Montfoort DO, van Kampen PM, Huijsmans PE: Epinephrine diluted saline-irrigation fluid in arthroscopic shoulder surgery: A significant improvement of clarity of visual field and shortening of total operation time. A randomized controlled trial. *Arthroscopy*, 2015; 32(3): 436–44
- Karns JL: Epinephrine-induced potentially lethal arrhythmia during arthroscopic shoulder surgery: A case report. *AANA J*, 1999; 67(5): 419–21
- Mazzocca AD, Meneghini RM, Chhablani R et al: Epinephrine-induced pulmonary edema during arthroscopic knee surgery. A case report. *J Bone Joint Surg Am*, 2003; 85-A(5): 913–15
- Buchko JZ, Gurney-Dunlop T, Shin JJ: Knee chondrolysis by infusion of bupivacaine with epinephrine through an intra-articular pain pump catheter after arthroscopic ACL reconstruction. *Am J Sports Med*, 2015; 43(2): 337–44
- Dragoo JL, Korotkova T, Kim HJ, Jagadish A: Chondrotoxicity of low pH, epinephrine, and preservatives found in local anesthetics containing epinephrine. *Am J Sports Med*, 2010; 38(6): 1154–59
- Dragoo JL, Braun HJ, Kim HJ et al: The *in vitro* chondrotoxicity of single-dose local anesthetics. *Am J Sports Med*, 2012; 40(4): 794–99
- Konig G, Hamlin BR, Waters JH: Topical tranexamic acid reduces blood loss and transfusion rates in total hip and total knee arthroplasty. *J Arthroplasty*, 2013; 28(9): 1473–76
- Karaaslan F, Karaoğlu S, Mermerkaya MU, Baktir A: Reducing blood loss in simultaneous bilateral total knee arthroplasty: combined intravenous-intra-articular tranexamic acid administration. A prospective randomized controlled trial. *Knee*, 2015; 22(2): 131–35
- Murkin JM, Falter F, Granton J et al: High-dose tranexamic acid is associated with nonischemic clinical seizures in cardiac surgical patients. *Anesth Analg*, 2010; 110(2): 350–53
- Morrison JJ, Dubose JJ, Rasmussen TE, Midwinter MJ: Military application of tranexamic acid in trauma emergency resuscitation (MATTERS) study. *Arch Surg*, 2012; 147(2): 113–19
- Ker K, Prieto-Merino D, Roberts I: Systematic review, meta-analysis and meta-regression of the effect of tranexamic acid on surgical blood loss. *Br J Surg*, 2013; 100(10): 1271–79
- Alshryda S, Mason J, Vaghela M et al: Topical (intra-articular) tranexamic acid reduces blood loss and transfusion rates following total knee replacement: A randomized controlled trial (TRANX-K). *J Bone Joint Surg Am*, 2013; 95(21): 1961–68
- Yuan ZF, Yin H, Ma WP, Xing DL: The combined effect of administration of intravenous and topical tranexamic acid on blood loss and transfusion rate in total knee arthroplasty: Combined tranexamic acid for TKA. *Bone Joint Res*, 2016; 5(8): 353–61
- Goyal N, Chen DB, Harris IA et al: Intravenous vs. intra-articular tranexamic acid in total knee arthroplasty: A randomized, double-blind trial. *J Arthroplasty*, 2017; 32(1): 28–32
- Pritzker KP, Gay S, Jimenez SA et al: Osteoarthritis cartilage histopathology: Grading and staging. *Osteoarthritis Cartilage*, 2006; 14(1): 13–29
- Kaplan LD: The analysis of articular cartilage after thermal exposure: “Is red really dead?”. *Arthroscopy*, 2003; 19(3): 310–13
- Chierichini A, Frassanito L, Vergari A et al: The effect of norepinephrine versus epinephrine in irrigation fluid on the incidence of hypotensive/bradycardic events during arthroscopic rotator cuff repair with interscalene block in the sitting position. *Arthroscopy*, 2015; 31(5): 800–6
- Buchko JZ, Gurney-Dunlop T, Shin JJ: Knee chondrolysis by infusion of bupivacaine with epinephrine through an intra-articular pain pump catheter after arthroscopic ACL reconstruction. *Am J Sports Med*, 2015; 43(2): 337–44
- Rao AJ, Johnston TR, Harris AH et al: Inhibition of chondrocyte and synovial cell death after exposure to commonly used anesthetics: Chondrocyte apoptosis after anesthetics. *Am J Sports Med*, 2014; 42(1): 50–58
- Dang AB, McCarthy MB, Dang AB et al: Effects of adding epinephrine to arthroscopic irrigation fluid on cultured chondrocyte survival *in vitro*. *Arthroscopy*, 2011; 27(8): 1118–22
- Tengborn L, Blombäck M, Berntorp E: Tranexamic acid – an old drug still going strong and making a revival. *Thromb Res*, 2015; 135(2): 231–42
- Digas G, Koutsogiannis I, Meletiadis G et al: Intra-articular injection of tranexamic acid reduce blood loss in cemented total knee arthroplasty. *Eur J Orthop Surg Traumatol*, 2015; 25(7): 1181–88
- Tuttle JR, Feltman PR, Ritterman SA, Ehrlich MG: Effects of tranexamic acid cytotoxicity on *in vitro* chondrocytes. *Am J Orthop (Belle Mead NJ)*, 2015; 44(12): E497–502
- Mannucci PM: Hemostatic drugs. *N Engl J Med*, 1998; 339(4): 245–53
- Seo JG, Moon YW, Park SH et al: The comparative efficacies of intra-articular and IV tranexamic acid for reducing blood loss during total knee arthroplasty. *Knee Surg Sports Traumatol Arthrosc*, 2013; 21(8): 1869–74