

Does the Posterior Bending Osteotomy in Bilateral Sagittal Split Osteotomy Affect the Condyle Position in Asymmetric Patients?



Taba Pergel, DDS, DS, *Subeyb Bilge, DDS, PhD,[†]
Abmet Emin Demirbaş, DDS, PhD,[‡] and Nükbet Kütük, DDS, PhD[§]

Purpose: To measure and compare changes in postoperative condylar position following bilateral sagittal split osteotomy in patients with asymmetry treated using a posterior bending osteotomy (PBO) and conventional methods (shaving of premature contacts).

Methods: Participants were randomized to either the PBO or conventional group. The inclusion criteria were the need for bilateral sagittal split osteotomy or bimaxillary asymmetric surgery (menton deviation >4 mm).

The primary outcome variable was changes in the condylar position in the axial, coronal, and sagittal planes 6 months after surgery, whereas the secondary outcome variable was changes in temporomandibular joint symptoms. Covariates included surgery type, deformity type, age, and sex. Categorical and numerical variables were analyzed using Fisher exact χ^2 test and 2-way analysis of covariance.

Results: The study sample comprised 42 patients with a mean age of 23.3 years; 57.5% were women. The alteration in the coronal condyle angle was $0.8^\circ \pm 0.86^\circ$ in the PBO and $2.72^\circ \pm 0.81^\circ$ in the conventional group. The differences in the condylar position in the coronal plane were not statistically significant ($P = .129$). The alteration in the axial condyle angle was $2.31^\circ \pm 1.74^\circ$ in the PBO group and $5.65^\circ \pm 1.65^\circ$ in the conventional group.

The alteration in the sagittal plane was $0.44^\circ \pm 1.52^\circ$ in PBO and $0.47^\circ \pm 1.44^\circ$ in the conventional group. Alterations in axial ($P = .194$) and sagittal ($P = .976$) condylar positions were insignificant. In the conventional group, statistically significant differences were found in the axial ($P = .002$) and coronal ($P = .002$) planes, and the condyle turned inward in both planes. There were no statistically significant differences between the groups or within the groups in the sagittal plane ($P > 0.5$). In PBO and conventional groups, joint noise examination revealed positive results in 11 and 6 patients preoperatively and 1 and 2 patients postoperatively, respectively. A statistically significant decrease in joint noise was detected in the PBO group ($P = 0.04$). The maximum mouth opening without pain was 5.95 ± 1.47 in the PBO group and 7.91 ± 1.39 in the conventional group, respectively. The alteration was not statistically significant between the groups but was significant within the groups ($P < .001$).

*Lecturer. Department of Oral and Maxillofacial Surgery, Faculty of Dentistry, Bezmialem Vakif University, Istanbul, Turkey.

[†]Assistant Professor. Department of Oral and Maxillofacial Surgery, Faculty of Dentistry, Erciyes University, Kayseri, Turkey.

[‡]Department Head, Associate Prof. Department of Oral and Maxillofacial Surgery, Faculty of Dentistry, Erciyes University, Kayseri, Turkey.

[§]Department Head, Professor. Department of Oral and Maxillofacial Surgery, Faculty of Dentistry, Bezmialem Vakif University, Istanbul, Turkey.

Conflict of Interest Disclosures: None of the authors have any relevant financial relationship(s) with a commercial interest.

Address correspondence and reprint requests to Dr Pergel: Faculty of Dentistry, Department of Oral and Maxillofacial Surgery, Bezmialem Vakif University, Fatih, Istanbul, Turkey; e-mail: tahapergel_05@hotmail.com

Received October 12 2022

Accepted March 27 2023

© 2023 American Association of Oral and Maxillofacial Surgeons

0278-2391/23/00329-4

<https://doi.org/10.1016/j.joms.2023.03.014>

Conclusions: PBO effectively prevents premature contact between mandibular segments in facial asymmetry.

© 2023 American Association of Oral and Maxillofacial Surgeons
J Oral Maxillofac Surg 81:855-868, 2023

Orthognathic surgery is indicated in patients with severe asymmetry to improve function and achieve a harmonious skeletal structure. The most common surgical procedure to treat mandibular prognathism and retrognathism is bilateral sagittal split osteotomy (BSSO), which was first described in 1957 by Obwegeser and Trauner.¹ During BSSO, the proximal segment containing the mandibular condyle and the distal segment containing the teeth were created. Complex mandibular movements, such as asymmetric mandibular setback or advancement, can change the position and angulation of the proximal segments.² Several factors that cause condylar displacement during BSSO have been previously described. These factors include fixation technique, bony interference, gaps between bone segments, condylar positioning, and osteotomy methods.³⁻⁶ In BSSO, especially in asymmetrical cases, if fixation is performed without removing premature contacts between the proximal and distal segments, the proximal segment may be rotated and displaced medially or laterally.⁵ Two techniques are commonly applied to remove premature bone contacts in BSSO. One of these techniques is to remove as many bone contacts as possible with the help of rotary or ultrasonic devices and passive closure of the gaps between the 2 segments before fixation. The second is plate bending (alignment) for passive fixation of the proximal segment by preserving premature bone contact between the segments. No definitive technique has been accepted in the literature for the effective removal of premature contacts between segments. However, in posterior bending osteotomy (PBO), defined by Ellis, premature bone contact is eliminated at the desired level, and the technique is considered reliable and efficient.⁷ The Ellis technique is an osteotomy performed using ultrasonic instruments in the distal segment just posterior to the last molar, creating a fracture by applying a medial force to the osteotomized part of the distal segment.

The purpose of this study was to investigate the techniques used to manage bony interference following BSSO in patients with asymmetry. The authors hypothesized that the conventional method would result in more remarkable angular changes in the temporomandibular joint (TMJ) than in the PBO. The specific aims of the study were to measure and compare changes in postoperative condylar position following BSSO in patients with asymmetry between those treated using PBO and those with conventional methods.

Materials and Methods

STUDY DESIGN AND SAMPLE DESCRIPTION

This prospective, randomized, controlled study followed the Declaration of Helsinki on Medical Protocol and Ethics and was approved by the Local Ethics Committee of Erciyes University (2019\17). The surgical procedure and possible undesirable conditions were explained to all patients in detail, and informed consent was obtained. The study included patients aged ≤ 18 to 30 scheduled for asymmetric orthognathic surgery due to Class 2 or Class 3 dentofacial deformity between 2019 and 2020 at the Erciyes University Faculty of Dentistry Oral and Maxillofacial Surgery Hospital.

INCLUSION CRITERIA FOR PATIENTS IN THIS CLINICAL STUDY

1. Presence of skeletal Class 2 or Class 3 deformity.
2. Need for asymmetric surgery during BSSO or Le Fort I and BSSO (menton deviation >4 mm).
3. Age >18 years.
4. The high-quality cone-beam computed tomography (CBCT) recordings for reliable measurements.

The exclusion criteria are as follows:

1. Bad split during surgery.
2. The presence of anomalies such as cleft lip and palate, craniofacial syndrome.
3. Patients who have had previous orthognathic surgery.
4. Patients with a history of trauma or pathology in the maxillofacial region.
5. Patients with missing cephalometric and TMJ examination findings.

Routinely acquired CBCT data from each patient 1 week before the orthognathic surgery were used. TMJ examinations were performed before and 6 months after the surgery, and parameters such as joint noise and maximum mouth opening were evaluated.

STUDY VARIABLES

Predictor Variables

The primary predictor variable was the technique used to manage bony interference following BSSO.

The patients were randomly divided into 2 groups. One of the 2 groups was the PBO group, and the other was the conventional group (shaving of premature contacts). BSSO was performed with the Hunsuck modification (1968) under nasotracheal intubation by the same anesthetic and surgery team at the Erciyes University Oral and Maxillofacial Surgery Hospital. The mandible was moved to its new position using a surgical splint prepared preoperatively. No condylar positioning devices or imaging techniques were used intraoperatively to determine the correct condylar position in any patient. Correct positioning of the condyle was ensured with manual manipulation. As defined by Ellis, PBO was performed for the passive positioning of the segments in the PBO group. An osteotomy was performed using ultrasonic instruments in the distal segment just behind the last molar tooth, starting coronally and inferior to the alveolar canal. Osteotomy lines above and below the neurovascular bundle were prepared vertically along the same line. A fracture was created by applying a medial force to the osteotomized part of the distal segment (Figs 1 and 2A,B)

In the conventional group, premature bone contact was removed by shaving during segment fixation. After the condyle was freely repositioned, the same surgeon performed semirigid fixation with a miniplate and screws. No patients underwent postoperative intermaxillary fixation (IMF) and they were allowed to open their mouths immediately after surgery. Active orthodontic treatment was initiated 1 month after surgery. Six months postoperatively, control CBCTs were performed to check the continuity of the natural condylar position of the patients.

OUTCOME VARIABLES

The primary outcome variable was the change in condylar position between the preoperative and postoperative (6 months) images. CBCT images of the patients in a standard supine position were obtained using the same device 1 week before and 6 months after the operation (NewTom 5G, QR, Verona, Italy) in the Department of Oral, Dental, and Maxillofacial Radiology. The skull base was traced in all images. Irradiation variables of the device were set as 16×18 cm scanning area, 110 kV tube voltage, 12.48 mA tube ampere, and 3.6 seconds irradiation time. All CBCT data were converted to the Digital Imaging and Communications in Medicine format and stored. Images were reconstructed with the 3-dimensional software MIMICS 18.0 (Materialise, Leuven, Belgium) and used to evaluate changes in the condylar position during the postoperative period.

The secondary outcome variable was changes in TMJ symptoms. TMJ examinations were performed

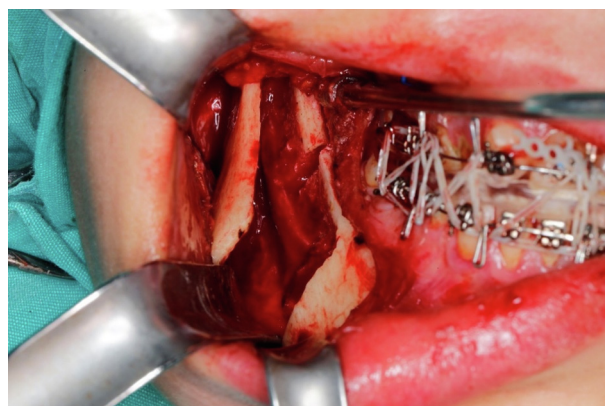


FIGURE 1. Posterior bending osteotomy.

Pergel et al. Posterior Bending Osteotomy and Condyle Position. J Oral Maxillofac Surg 2023.

1 week before and 6 months after surgery. Joint noise (click), maximum painless mouth opening (mm), painful mouth opening with manipulation (mm), right and left lateral excursions (mm), and protrusion movement (mm) were recorded.

The covariates included surgery type (bimaxillary or single-jaw), deformity type (Class 2 or Class 3), patient age, and sex.

REFERENCE POINTS AND MEASUREMENTS

First, the CBCT data were analyzed, and the following reference points were determined: right and left porion, right orbitale, nasion, basion, right and left condylion (Co), point A, and lateral and medial condyle pole points (Table 1).

LINEAR AND ANGULAR MEASUREMENTS

Before and after surgery, the distance (mm) between the midsagittal reference plane (MSR) and Co in the axial section was measured and compared to evaluate the change in the mediolateral condyle position in the glenoid fossa. For other measurements, the condylar axis was first determined. The condylar axis passed through the midpoint between the medial and lateral poles in the axial and coronal planes and was drawn through the center of the condylar head and neck in the sagittal plane. Angular measurements of the 3 planes relative to the reference planes were performed to evaluate changes in the condylar axis.⁸ To evaluate the medial or lateral rotation of the condyle in the glenoid fossa, angular measurements of the line starting from the lateral condyle pole and passing through the MCP in the axial section, where the condyle had the largest mediolateral dimension and the MSR plane were performed before and after the operation (Fig 3). First, the condylar axis was determined, followed by the inclination of the condylar axis, which passes through the Co and the center of the condylar neck

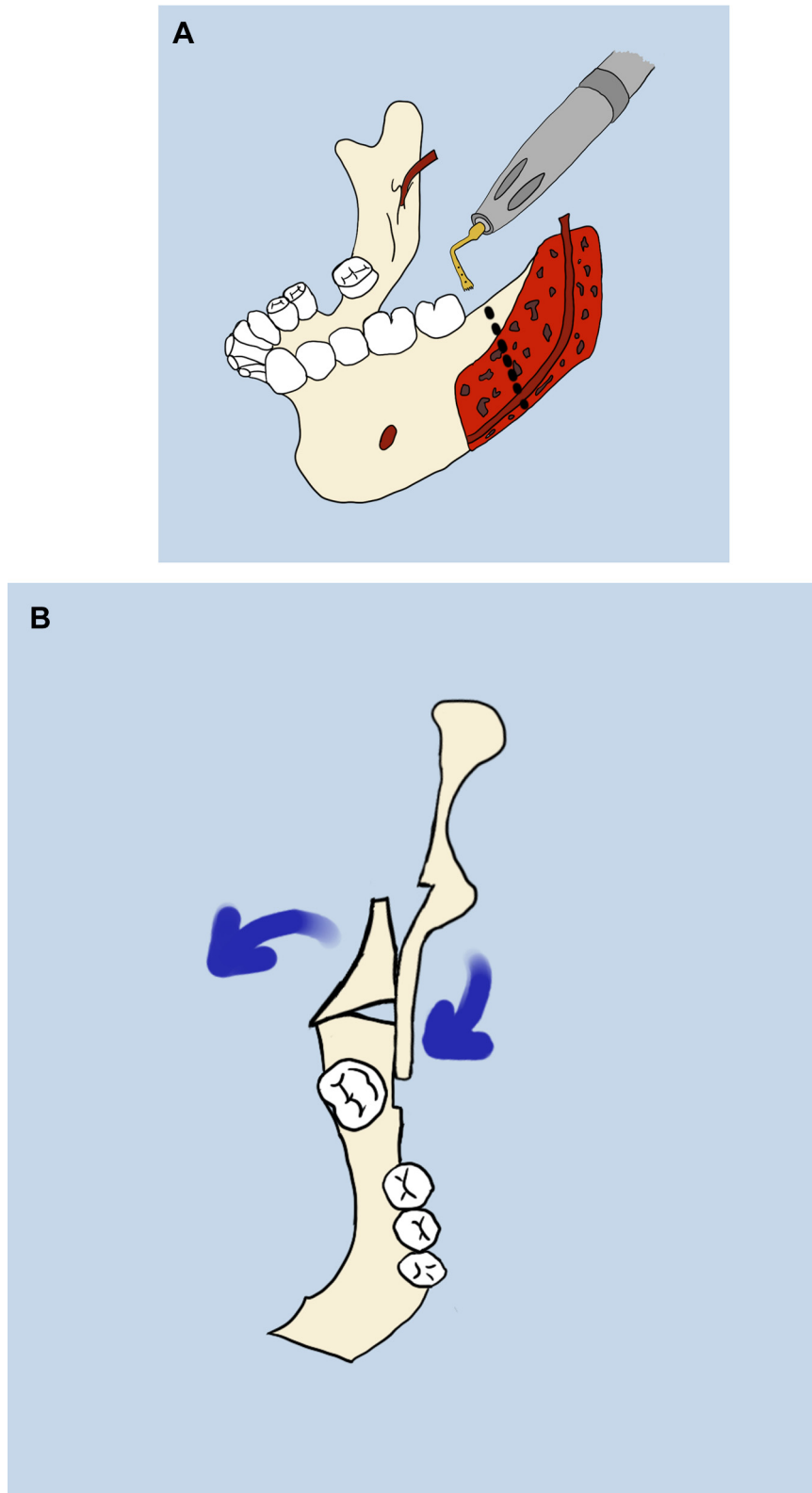


FIGURE 2. A, Osteotomy line on the lingual plate of the distal segment above and below the mandibular canal. B, Greenstick fracture of the posterior portion of the distal segment allows the proximal segment to align passively.

Pergel et al. Posterior Bending Osteotomy and Condyle Position. J Oral Maxillofac Surg 2023.

Table 1. POINT/PLANES DESCRIPTIONS

Point/Planes	Description
Orbitale (Or) (right)	Deepest point of the infraorbital margin
Porion (Po) (right-left)	The most superior point of the external auditory meatus
Nasion (Na)	The most anterior point of nasofrontal suture on midsagittal plane
Basion (Ba)	The midpoint of the anterior border of the foramen magnum
Lateral condyle pole (LCP) (right-left)	The outermost point of the condyle head in the axial plane (Fig 3)
Medial condyle pole (MCP) (right-left)	Innermost point of the condyle head in the axial plane (Fig 3)
Condyle center (Co) (right-left)	The midpoint of the line connecting the LCP and MCP points in the axial section (Fig 3)
A point	The highest point of the mandibular fossa in the sagittal plane (Fig 4)
Frankfurt horizontal plane (FHP)	The plane passing through the right and left porion and right orbitale (Fig 6)
Midsagittal reference plane (MSR)	Plane passing through nasion and basion points perpendicular to the FHP (Fig 5)
Multiplanar reconstruction plane (MPR)	Plane parallel to the MSR plane and passing through the center of the condyle (Fig 5)
A line	The plane parallel to FHP and passing through point A (Fig 4)

Pergel et al. Posterior Bending Osteotomy and Condyle Position. J Oral Maxillofac Surg 2023.

and extends to the angulus. Subsequently, the angle between this axis and the Frankfurt horizontal plane was measured before and after the operation in the coronal plane and compared (Fig 6). In order to determine the condyle axis angle in the sagittal plane, the

condyle axis passing through the center of the condyle and condyle neck was initially determined, and the angle of this axis with the Frankfurt horizontal plane was measured and compared before and after surgery (Fig 7).⁹ According to Pullinger’s method for

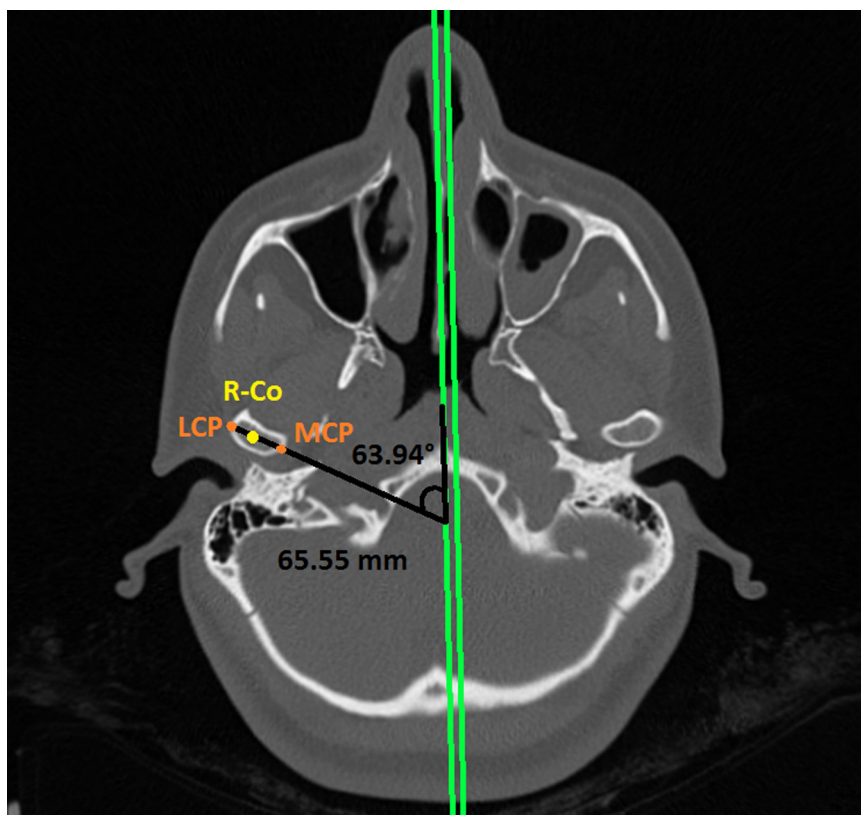


FIGURE 3. Axial section, midsagittal reference plane (green), right condyion (Co) point (yellow), and the angle between them and length measurement (mm). LCP, lateral condyle pole; MCP, medial condyle pole; R-Co, right condyion.

Pergel et al. Posterior Bending Osteotomy and Condyle Position. J Oral Maxillofac Surg 2023.

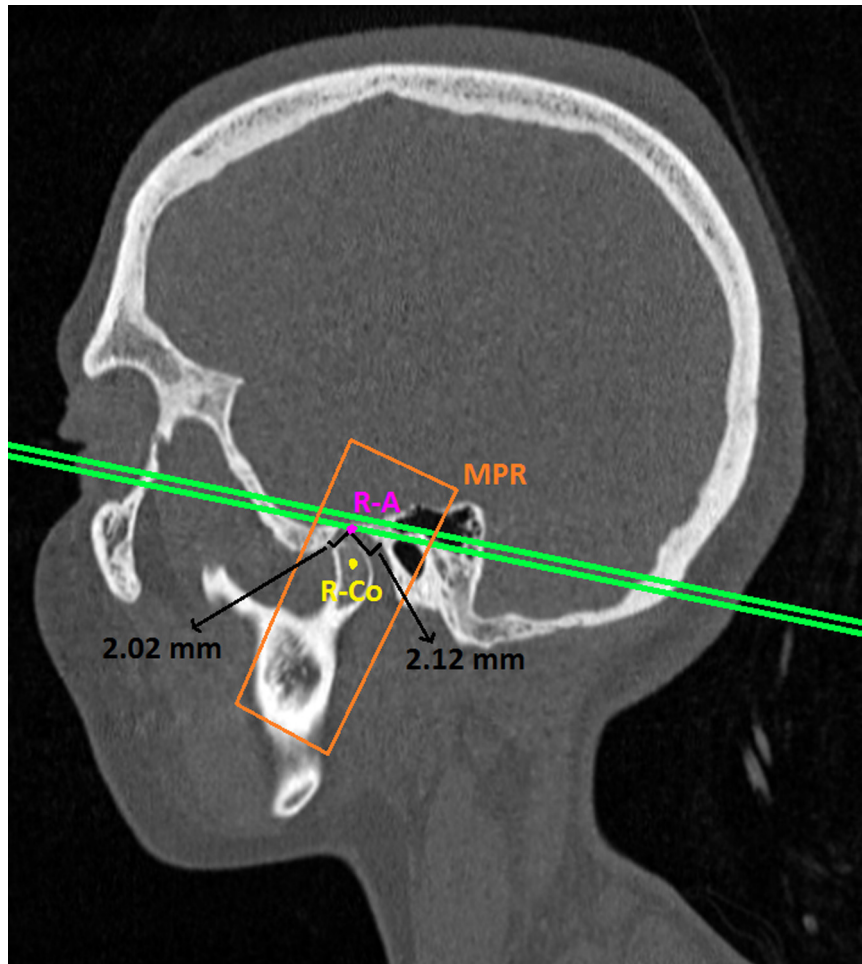


FIGURE 4. Anteroposterior distance (mm) measurement in sagittal plane. Multiplanar reconstruction plane (orange), right A point (pink), line A (green), and right Co (yellow). MPR, multiplanar reconstruction; R-A, right A; R-Co, right condyion.

Pergel et al. Posterior Bending Osteotomy and Condyle Position. J Oral Maxillofac Surg 2023.

evaluating the anteroposterior condyle position in the glenoid fossa, 3 positions (anterior, central, and posterior) were assigned to the condyle.¹⁰ The plane parallel to the MSR plane and passing through the center of the condyle, namely the sagittal multiplanar reconstruction plane, was used to measure the gap between the condyle and glenoid fossa (Fig 4). The anterior and posterior spaces were magnified thrice in the sagittal plane, and measurements were made in the multiplanar reconstruction plane section using the following formula:

$$\frac{\text{Posterior Space} - \text{Anterior Space}}{\text{Posterior Space} + \text{Anterior Space}} \times 100$$

A value between -12 and $+12$ indicates that the condyle is in the concentric position. Lower values than -12 indicate its posterior position, and higher values than $+12$ indicate its anterior position.⁸

STATISTICAL ANALYSES

Data were evaluated in the statistical package program IBM SPSS Statistics Standard Concurrent User V 25 (IBM Corp., Armonk, New York). Descriptive statistics are the number of units (n), percent (%), mean \pm standard deviation ($\bar{x} \pm \text{sd}$), median (M), 25th percentile (Q1), 75th percentile (Q3), smallest value (min), and the highest value (max). The normal distribution of the numerical variables was evaluated using the Shapiro-Wilk test of normality and Q-Q graphs. Comparisons between the PBO and conventional groups for categorical variables were made using Fisher exact χ^2 test developed for 2×2 and $r \times c$ tables. In-group comparisons of repeated measures for categorical variables were performed using the McNemar test for 2-category variables and the McNemar-Bowker test for 3-category variables. For non-normally distributed variables, group

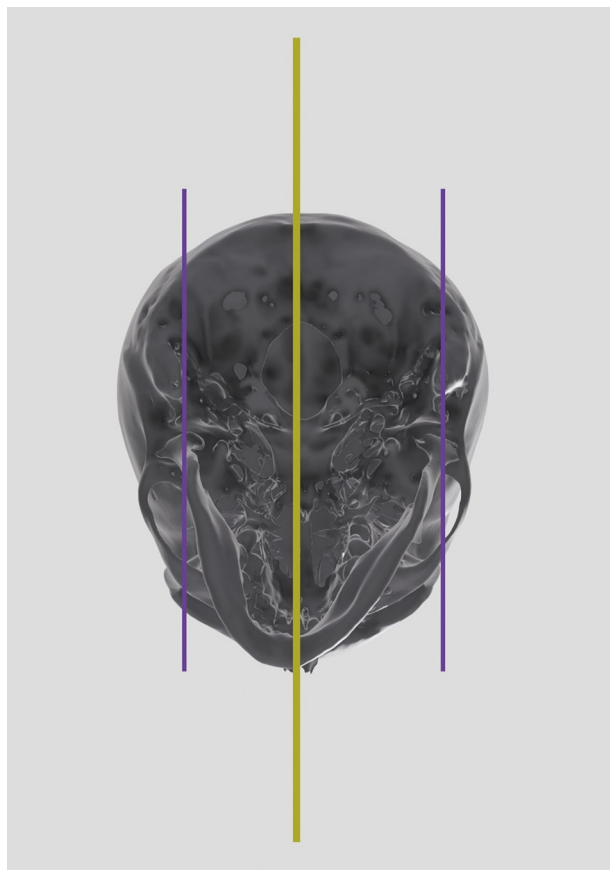


FIGURE 5. The right and left multiplanar reconstruction plane planes (purple) passing through the Co point and parallel to the midsagittal reference plane (yellow) in 3-dimensional model.

Pergel et al. *Posterior Bending Osteotomy and Condyle Position.* *J Oral Maxillofac Surg* 2023.

comparisons were performed using the Mann-Whitney *U* test. A 2-way analysis of covariance was used for repeated measurements since adjustments were made for sex and age when comparing numerical variables according to groups. The Bonferroni correction was applied to compare the main effects. In the 2-way covariance analysis, descriptive statistics were given as mean \pm standard error ($\bar{x} \pm sh$). Differences were considered statistically significant at $P < .05$.

Results

The sample comprised 42 participants (24 women and 18 men; mean age, 23.3). The patients were randomly divided into 2 groups, PBO ($n = 20$, 47.6%) and conventional ($n = 22$, 52.4%), according to the surgical method used to prevent premature contact during BSSO (Fig 8). The sex and age distribution of the patients is shown in Table 2. The sex and age distributions of the groups were statistically similar (Table 2). No significant differences were found in the preopera-

tive type of surgery, deformity type, or condylar position (Table 2).

The MSR condyle distance was 59.60 ± 1.87 mm in the preoperative PBO group and 59.37 ± 1.65 mm in the conventional group (Table 3). Postoperative MSR-condyle distance was 60.26 ± 1.77 mm in the PBO group and 62.15 ± 2.03 mm in the conventional group. The postoperative change was higher in the conventional group, with a statistically significant difference between the groups ($P = .025$). In addition, the postoperative increase was not statistically significant in the PBO group but was significantly different in the conventional group ($P = .014$).

Preoperative axial condyle angle values were $67.61^\circ \pm 1.84^\circ$ in the PBO group and $69.30^\circ \pm 1.74^\circ$ in the conventional group, while the postoperative values were $65.29^\circ \pm 2.06^\circ$ in the PBO group and $63.65^\circ \pm 1.96^\circ$ in the conventional group. Although the changes before and after the surgery did not create a statistically significant difference in the PBO group, they did create a significant difference in the conventional group ($P = .002$).

The preoperative coronal condyle angle was $86.44^\circ \pm 0.94^\circ$ in the PBO and $83.73^\circ \pm 0.89^\circ$ in the conventional group, while postoperatively it was $87.24^\circ \pm 0.86^\circ$ in the PBO group and $86.45^\circ \pm 0.82^\circ$ in the conventional group. Postoperative coronal condyle angle increased in both groups. The increase in the conventional group was statistically significant ($P = .002$).

The preoperative sagittal condyle angle was $69.96^\circ \pm 2.02^\circ$ in the PBO group and $67.00^\circ \pm 1.91^\circ$ in the conventional group, while postoperatively it was $70.40^\circ \pm 2.18^\circ$ in the PBO group and $67.47^\circ \pm 2.07^\circ$ in the conventional group. Although there was a slight increase in the angle in both groups, the change in the conventional group was more significant than that in the PBO group. The changes did not create a statistically significant difference within or between groups.

The preoperative condyle anterior distance was 1.91 ± 0.24 mm in the PBO group and 2.29 ± 0.23 mm in the conventional group, while postoperatively it was 2.23 ± 0.23 mm in the PBO group and 2.70 ± 0.21 mm in the conventional group. Although there was an increase in the postoperative values in both groups, the increase in the conventional group was greater. The values and changes before and after the operation did not differ significantly between or within groups.

Condyle posterior distance was 2.00 ± 0.34 mm in the preoperative PBO and 1.89 ± 0.32 mm in the conventional group. Postoperatively, it was 1.77 ± 0.22 mm in the PBO and 1.56 ± 0.21 mm in the conventional group. Although there was a decrease in the values in both groups, the change was greater in the conventional group. The values

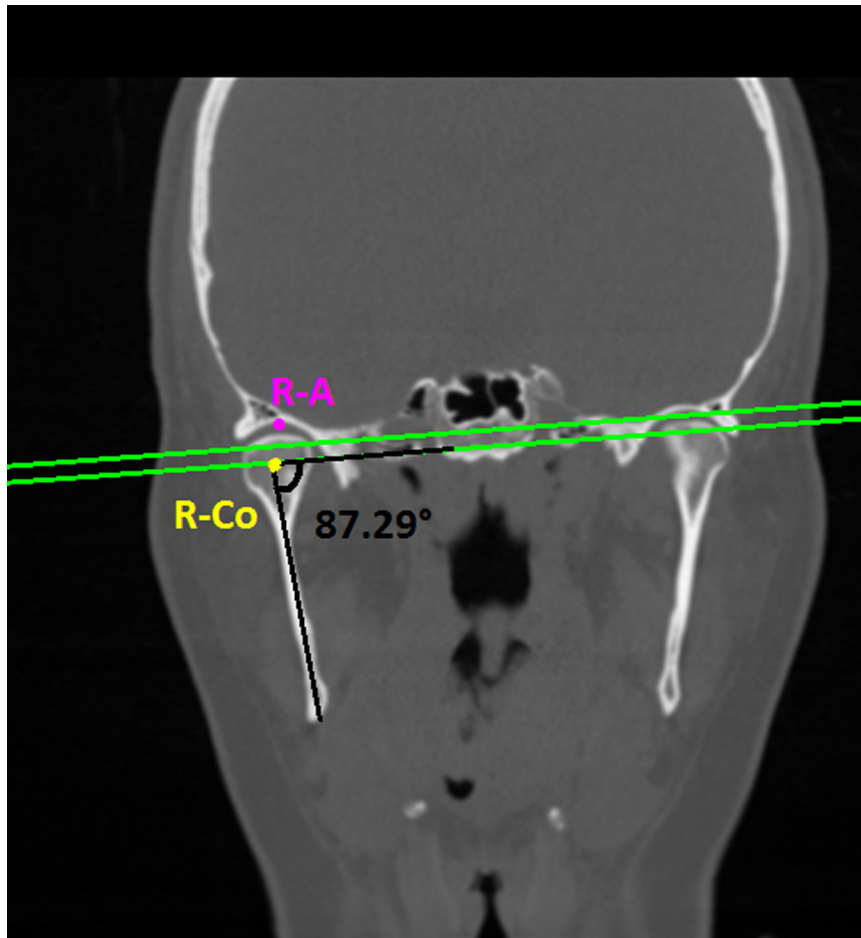


FIGURE 6. Frankfurt horizontal plane (green), right A point (pink), right Co point (yellow), and coronal condylar angle measurement between them. R-A, right A; R-Co, right condylian.

Pergel et al. Posterior Bending Osteotomy and Condyle Position. J Oral Maxillofac Surg 2023.

and amount of change before and after surgery did not differ significantly between the groups.

The condyle position variable was 3.89 ± 6.40 in the preoperative PBO and -10.98 ± 6.07 in the conventional group. Postoperative values were -7.39 ± 6.88 in the PBO and -13.29 ± 6.53 in the conventional group. Pre- and postoperative values did not differ significantly between the groups.

Preoperative clicks were observed in 11 (55%) patients in the PBO group and 6 (27.3%) patients in the conventional group (Table 4a). Postoperative clicks were observed in 1 patient (5%) in the PBO group and 2 patients (9.1%) in the conventional group. The pre- and postoperative click distributions were similar between the groups. The presence of clicks before and after surgery in the PBO group was statistically significant ($P = .004$).

The preoperative maximum painless opening values were 43.36 ± 1.35 mm in the PBO and 42.31 ± 1.28 mm in the conventional group

(Table 4b). Postoperative maximum painless opening values were 37.41 ± 0.98 mm in the PBO group and 34.40 ± 0.93 mm in the conventional group. The maximum painless opening in the postoperative PBO group was significantly higher than that in the conventional PBO group ($P = .039$). Both groups showed a statistically significant decrease in maximum painless opening values ($P < .001$).

Painful opening values with preoperative physician manipulation were 46.45 ± 1.30 mm in the PBO group and 45.18 ± 1.23 mm in the conventional group. Painful opening values with physician manipulation after surgery were 39.69 ± 1.03 mm in the PBO group and 36.51 ± 0.98 mm in the conventional group. There were no statistically significant differences in these values between the preoperative groups. Postoperative physician manipulation and mouth-opening rates were significantly higher in the PBO group than those in the conventional group ($P = .040$). Both groups showed a significant

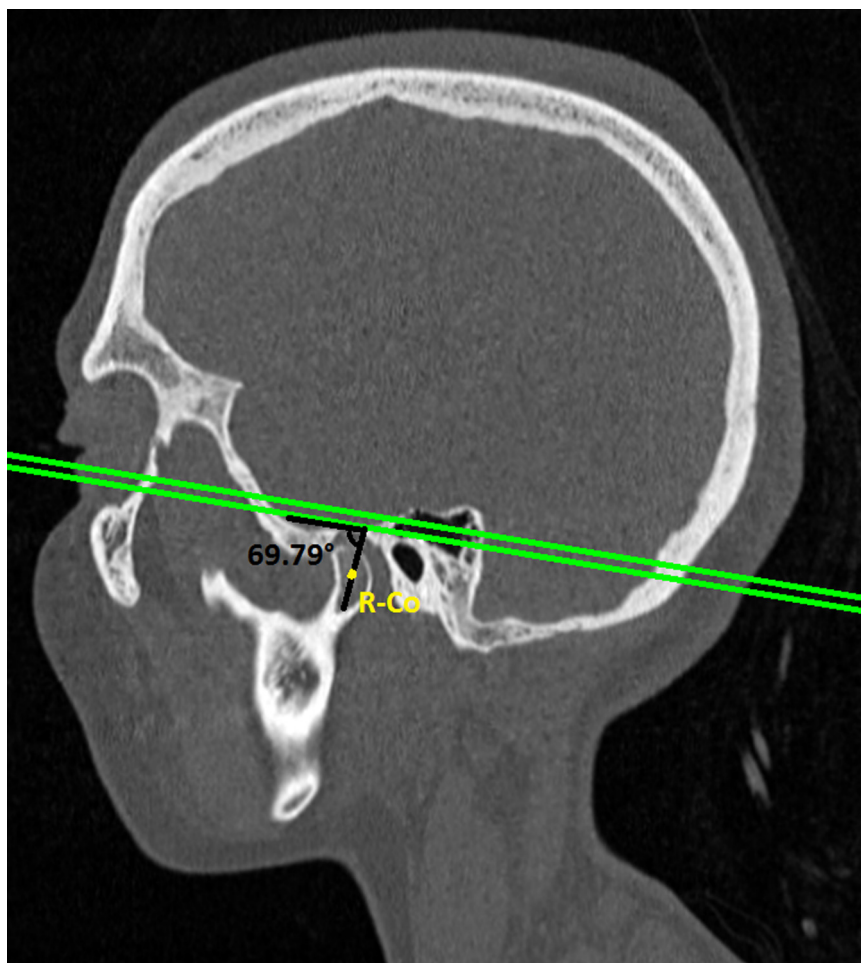


FIGURE 7. Frankfurt horizontal plane (green), right Co point (yellow), and measurement of sagittal condyle angle between them. R-Co, right condylion.

Pergel et al. Posterior Bending Osteotomy and Condyle Position. J Oral Maxillofac Surg 2023.

decrease in mouth opening with manipulation ($P < .001$).

Patients from both groups did not experience any pain 6 months postoperatively.

Discussion

The purpose of this study was to measure and compare changes in the postoperative condylar position following BSSO in patients with asymmetry between those treated using PBO and conventional methods.

It is thought that PBO preserves the preoperative position of the condyle better than BSSO in patients with asymmetry. Changes in the condylar position with the 2 different techniques were evaluated prospectively using CBCT, and the effects of these changes on the TMJ were investigated. The authors hypothesized that the conventional method would result in greater angular changes in the TMJ than in the PBO.

At the end of this study, the findings supported the hypothesis. For the conventional group, in both the

axial and coronal planes, it was determined that the condyle had a statistically significant inward rotation with an average of $5.65^\circ \pm 1.65^\circ$ and $2.72^\circ \pm 0.81^\circ$, respectively. No statistically significant difference was found in the position and movement of the condyles in the sagittal plane. This study observed a significant decrease in joint noise, a postoperative TMJ finding, in both PBO and conventional groups. In addition, although there was a statistically significant decrease in the maximum mouth opening values in both groups, the postoperative mouth opening values were greater than 35 mm.

Several studies have reported that the proximal segment and condyle positions change after mandibular advancement or setback surgery.^{2,9,11} Imamura et al reported that the change in condylar position might result from the surgical procedure itself.¹² In a study evaluating BSSO Dalpont modification, BSSO Hunsuck modification, and intraoral vertical ramus osteotomy (IVRO) in patients with mandibular asymmetry, the earliest bone contact between the proximal

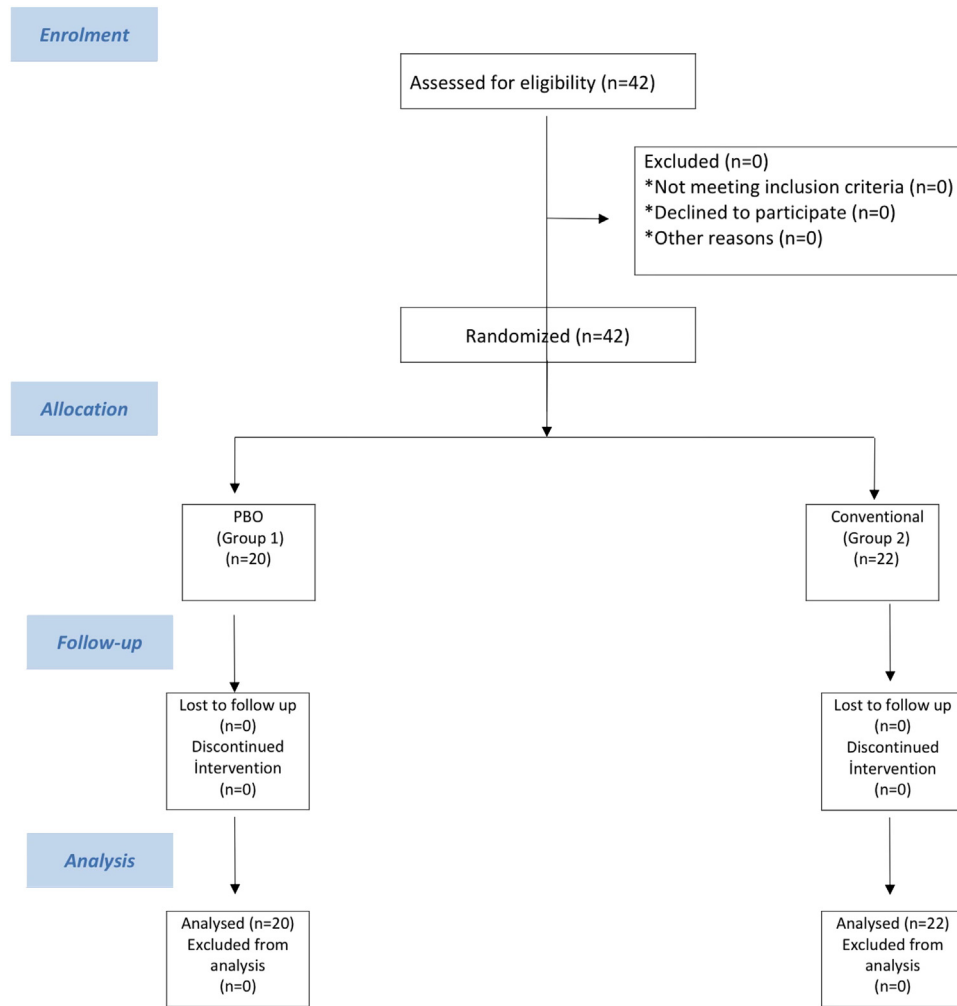


FIGURE 8. CONSORT (Consolidated Standards of Reporting Trials) flowchart of patient participation in study. PBO, posterior bending osteotomy.

Pergel et al. *Posterior Bending Osteotomy and Condyle Position*. *J Oral Maxillofac Surg* 2023.

and distal segments was observed with the Dalpont modification. The minimum bone contact was observed with the Hunsuck modification. In cases of severe asymmetry, no differences were found between the IVRO and Hunsuck modifications.⁵ In IVRO, especially in patients with asymmetry who require rotational movement, decreased bone contact between segments complicates postoperative recovery and fixation. Long-term postoperative intermaxillary fixation poses serious disadvantages in terms of patient comfort. Additionally, IVRO was not preferred in our study because of life-threatening bleeding complications related to the maxillary artery during surgery. Therefore, the BSSO Hunsuck modification is routinely used in our clinic. In the Hunsuck modification, 2 stages are considered important in the conventional technique to eliminate premature bone contact between the segments and prevent condylar movement. The first is the identification of premature contacts be-

tween the distal and proximal segments and their removal by trimming. The second is the alignment of the miniplates and fixation of the segments in their original passive position. However, one study showed that trimming the intersegmental region did not eliminate premature contacts at the desired level.¹³ In another study, the authors reported that premature bone contact in this region could not be eliminated because the osteotomy line was not on a single plane. The inner surfaces of the bones are indented, and the anatomical structures prevent premature bone contact in this region.¹⁴ Ellis described a technique for effectively and safely removing premature bone contact between the proximal and distal segments during BSSO.⁷ In this technique, the fracture formed in the lingual part of the distal segment and early contacts between the segments were eliminated quickly and safely. Another advantage of this technique is that it creates a large surface area for rapid bone healing. A

Table 2. COVARIATES

Variables	Groups				Test Statistics <i>P</i>
	PBO		Conventional		
	<i>n</i>	(%)	<i>n</i>	(%)	
Sex					.702
Male	8	40.0	10	45.0	
Female	12	60.0	12	55.0	
Type of surgery					.174
Bimaxillary surgery	16	80.0	21	95.5	
Single jaw osteotomy	4	20.0	1	4.5	
Deformity type					.123
C2	6	30.0	2	9.1	
C3	14	70.0	20	90.9	
Age					.541
$\bar{x} \pm sd$	22.1 ± 5.4		24.6 ± 6.6		
<i>M</i> (<i>Q</i> ₁ - <i>Q</i> ₃)	20.0 (19.2-23.7)		23.0 (20.7-30.2)		

Abbreviations: C2, Class 2 deformity; C3, Class 3 deformity; PBO, posterior bending osteotomy; sd, standard deviation.

Pergel et al. Posterior Bending Osteotomy and Condyle Position. *J Oral Maxillofac Surg* 2023.

disadvantage of this technique is the difficulty in finding a stable bone in the lingual segment during bicortical screw fixation. The types of fixation recommended in this technique are miniplate and screw fixation.⁷ Only 1 study has examined positional changes in the condyle using Ellis technique. In their study of 22 patients in 2014, Yang et al reported that the Ellis technique was superior to the conventional method for preserving condylar positions. In their 2014 study conducted on 22 skeletal S1 and S3 patients, Yang et al used the PBO technique in PBO, while the conventional method was used in the conventional group to prevent premature contact between the proximal and distal segments. Yang's study, the condyle rotated inward ($3.95^\circ \pm 2.96^\circ$) in the axial plane in the group in which the conventional method was applied, and this rotation was more than the PBO group ($1.50^\circ \pm 3.76^\circ$), on the coronal plane, the PBO group was on average $1.46^\circ \pm 4.69^\circ$ found an average of $1.53^\circ \pm 2.73^\circ$ in the group in which the conventional method was applied. They stated that the condyle rotated outward, although there was no statistically significant difference between the groups. They also emphasized that the angle between the long axis of the ramus and the horizontal axis decreased ($2.48^\circ \pm 3.61^\circ$) in the PBO group. In the results of this study, it was determined that the condyle in the conventional group had a statistically significant inward rotation ($5.65^\circ \pm 1.65^\circ$) in the axial plane, a statistically significant inward rotation of $2.72^\circ \pm 0.81^\circ$ in the coronal axis. In this study, the movement of the condyle in the coronal plane was an in-

ward rotation in the conventional technique group, whereas in the study by Yang et al, the movement of the condyle in the coronal plane in the PBO group was more outward than in the conventional technique. After completing miniplate fixation, Yang et al placed a bicortical screw on the lingual part that was released as a result of lingual osteotomy. As a result of this rigid fixation, the angle of the long axis of the ramus with the horizontal plane decreased and the condyle rotated externally, unlike the results of this study. In the technique described by Ellis et al, free bone fragments adhering to the periosteum and oral mucosa in the lingual part of the distal segment do not require fixation. In the present study, no additional fixation was performed on the free lingual piece. Unlike in the study by Yang et al, in the axial plane, the condyle moved laterally in the glenoid fossa, which was statistically significant in the conventional group. No statistically significant difference was found in the position and movement of the condyles in the sagittal plane.

Although there are many studies on the effect of orthognathic surgery on TMJ, there is still no consensus on the results.¹⁵⁻¹⁷ The effect of orthognathic surgical procedures on the TMJ has often been associated with changes in condylar position, and studies have reported that this may cause TMJ dysfunction.¹⁸⁻²¹ Similarly, rigid fixation causes a condylar position change, which is responsible for TMJ disorders after surgery.²² Orthognathic surgical procedures such as BSSO and IVRO can cause changes in the condylar position. Studies show that rigid fixation in BSSO may

Table 3. CHANGES IN CONDYLAR POSITION BETWEEN THE 2 TREATMENT GROUPS

Measurement Time	Groups				Intergroup Test Statistics <i>P</i>	
	PBO		Conventional			
	\bar{x}	<i>sd</i>	\bar{x}	<i>sd</i>		
MSR condyle distance (mm)	Preop	59.60	1.87	59.37	1.65	.572
	Postop	60.26	1.77	62.15	2.03	.025
	Difference	0.66	1.95	2.78	1.85	.916
	In-group test statistics	<i>P</i> = .651		<i>P</i> = .014		
Axial condyle angle	Preop	67.61	1.84	69.30	1.74	.528
	Postop	65.29	2.06	63.65	1.96	.585
	Difference	2.31	1.74	5.65	1.65	.194
	In-group test statistics	<i>P</i> = .192		<i>P</i> = .002		
Coronal condyle angle	Preop	86.44	0.94	83.73	0.89	.053
	Postop	87.24	0.86	86.45	0.82	.532
	Difference	0.80	0.86	2.72	0.81	.129
	In-group test statistics	<i>P</i> = .358		<i>P</i> = .002		
Sagittal condyle angle	Preop	69.96	2.02	67.00	1.91	.317
	Postop	70.40	2.18	67.47	2.07	.188
	Difference	0.44	1.52	0.47	1.44	.976
	In-group test statistics	<i>P</i> = .256		<i>P</i> = .744		
Condyle anterior distance (mm)	Preop	1.91	0.24	2.29	0.23	.289
	Postop	2.23	0.23	2.70	0.21	.894
	Difference	0.32	0.26	0.41	0.25	.555
	In-group test statistics	<i>P</i> = .523		<i>P</i> = .461		
Condyle posterior distance (mm)	Preop	2.0	0.34	1.89	0.32	.110
	Postop	1.77	0.22	1.56	0.21	.888
	Difference	0.23	0.36	0.33	0.34	.087
	In-group test statistics	<i>P</i> = .069		<i>P</i> = .820		
Condyle position	Preop	3.89	6.40	-10.98	6.07	.117
	Postop	-7.39	6.88	-13.29	6.53	.558
	Difference	3.5	7.93	2.31	7.52	.453
	In-group test statistics	<i>P</i> = .163		<i>P</i> = .761		

Abbreviations: MSR, midsagittal reference plane; PBO, posterior bending osteotomy; sd: standard deviation.

Pergel et al. Posterior Bending Osteotomy and Condyle Position. *J Oral Maxillofac Surg* 2023.

produce a greater change in condyle position and a higher incidence of TMJ dysfunction than semirigid fixation.^{23,24} No study has evaluated the effects of positional changes in the condyle on the TMJ in the literature using the Hunsuck modification and Ellis PBO techniques. This study showed that premature contacts are effectively eliminated and, similar to the preoperative position of the condyle, are preserved using Ellis technique. The literature has revealed that TMJ structures can tolerate the linear changes after orthognathic surgery as 1 to 2 mm without causing clinical findings.^{14,25} Although there is no definitively accepted reference range, our study's linear change in the axial plane was 2.78 ± 1.75 mm in the conventional group and 0.66 ± 1.95 mm in the PBO. These values are very close to those reported in the literature

and do not cause clinical symptoms. The tolerable range of angular changes in the literature was specified in only 1 study and was defined as $<4^\circ$.¹⁴ In this study, although the angular change of the conventional group in the axial plane was $5.65^\circ \pm 1.65^\circ$, slightly above the value given in the literature, it did not cause any clinical symptoms. In this study, the postoperative TMJ findings were consistent with those in the literature, and a significant decrease in joint noise was found in both the PBO and conventional groups. In addition, although there was a statistically significant decrease in the maximum mouth opening values, the postoperative mouth opening values were >35 mm in both groups. We attribute this decrease to the fact that some patients do not perform mouth-opening exercises regularly and to the type of elastics used in the

Table 4a. COMPARISON OF TEMPOROMANDIBULAR JOINT EXAMINATION VARIABLES BY GROUPS

Variables	Groups				Test Statistics
	PBO		Conventional		
	n	(%)	n	(%)	P
Clicking (preop)					.204
Yes	11	55.0	6	27.3	
No	9	45.0	16	72.7	
Clicking (postop)					1.000
Yes	1	5.0	2	9.1	
No	19	95.0	20	90.9	
In-group McNemar statistic	P = .004		P = .289		

Abbreviations: PBO, posterior bending osteotomy.

Pergel et al. Posterior Bending Osteotomy and Condyle Position. J Oral Maxillofac Surg 2023.

postoperative orthodontic treatment process. None of the angular changes in the condyle caused any pathology in the TMJ, indicating that the condyle remained within its adaptability.

The strengths of this clinical study include the fact that the same team performed the entire surgical procedure. The patient's tomography data were measured by an impartial observer who was not part of the

Table 4b. COMPARISON OF JOINT EXAMINATION VARIABLES BY GROUPS

Measurement Time	Groups				Intergroup Test Statistics	
	PBO		Conventional			
	\bar{x}	sd	\bar{x}	sd	P	
Maximum painless mouth opening (mm)	Preop	43.36	1.35	42.31	1.28	.592
	Postop	37.41	0.98	34.40	0.93	.039
	Difference	5.95	1.47	7.91	1.39	.362
	In-group test statistics	P < .001		P < .001		
Painful opening with manipulation (mm)	Preop	46.45	1.30	45.18	1.23	.503
	Postop	39.69	1.03	36.51	0.98	.040
	Difference	6.76	1.43	8.67	1.35	.362
	In-group test statistics	P < .001		P < .001		
Right lateral excursion (mm)	Preop	6.92	0.46	5.49	0.44	.421
	Postop	6.23	0.32	4.79	0.30	.341
	Difference	0.69	0.37	0.70	0.35	.672
	In-group test statistics	P = .141		P = .055		
Left lateral excursion (mm)	Preop	5.10	0.57	4.98	0.54	.198
	Postop	4.78	0.35	4.58	0.33	.302
	Difference	0.32	0.43	0.40	0.41	.167
	In-group test statistics	P = .108		P = .973		
Protrusion (mm)	Preop	4.10	0.55	3.98	0.52	.652
	Postop	3.42	0.30	3.35	0.28	.784
	Difference	0.68	0.55	0.63	0.52	.965
	In-group test statistics	P = .812		P = .899		

Abbreviations: PBO, posterior bending osteotomy; sd: standard deviation.

Pergel et al. Posterior Bending Osteotomy and Condyle Position. J Oral Maxillofac Surg 2023.

surgical team, using software that can make sensitive measurements, such as MIMICS. Another strength of this clinical study was its prospective, randomized, controlled design.

However, this clinical study has some limitations. There were a proportionally larger number of Class III patients with asymmetry in the conventional group than that in the PBO group. When correcting for asymmetry in a Class III patient, there is a greater chance of interference between the proximal and distal segments than when correcting for asymmetry in a Class II patient because of advancement in the Class II patient. TMJ symptoms can be affected by condylar morphology, condylar position, and the position or shape of the disc. Therefore, the shape and position of the articular disc should be evaluated using magnetic resonance imaging before and after surgery to precisely evaluate the improvement in the postoperative TMJ symptoms.

In this study, PBO was performed on the distal segment of the deviated side of the jaw. PBO is effective in preventing premature contact in patients with asymmetry and has the potential to help reduce positional shifts of the condyle. To evaluate the effect of the PBO alone, both positional changes in the condyle and TMJ symptoms were performed only on the deviated side. In the future, we plan to design comprehensive studies that include deviated and nondeviated condyles and the risk of nerve damage, postoperative edema, complications, and operative time according to the results of this clinical study.

References

- Agırnaslıgil MO, Amuk NG, Kılıç E, Kutuk N, Demırbas AE, Alkan A. The changes of self-esteem, sensitivity to criticism, and social appearance anxiety in orthognathic surgery patients: A controlled study. *Am J Orthod Dentofacial Orthop* 155:482-489.e2, 2019
- Becktor J, Rebellato J, Becktor K, Isaksson S, Vickers P, Keller E. Transverse displacement of the proximal segment after bilateral sagittal osteotomy. *J Oral Maxillofac Surg* 60:395-403, 2002
- Baek S-H, Kim T-K, Kim M-J. Is there any difference in the condylar position and angulation after asymmetric mandibular setback? *Oral Surg Oral Med Oral Pathol Oral Radiol Endod* 101:155-163, 2006
- Kang MG, Yun KI, Kim CH, Park J-U. Postoperative condylar position by sagittal split ramus osteotomy with and without bone graft. *J Oral Maxillofac Surg* 68:2058-2064, 2010
- Yang HJ, Lee WJ, Yi WJ, Hwang SJ. Interferences between mandibular proximal and distal segments in orthognathic surgery for patients with asymmetric mandibular prognathism depending on different osteotomy techniques. *Oral Surg Oral Med Oral Pathol Oral Radiol Endod* 110:18-24, 2010
- Harris MD, Van Sickels JR, Alder M. Factors influencing condylar position after the bilateral sagittal split osteotomy fixed with bicortical screws. *J Oral Maxillofac Surg* 57:650-654, 1999
- Ellis E. A method to passively align the sagittal ramus osteotomy segments. *J Oral Maxillofac Surg* 65:2125-2130, 2007
- Kim YI, Jung YH, Cho BH, et al. The assessment of the short-and long-term changes in the condylar position following sagittal split ramus osteotomy (SSRO) with rigid fixation. *J Oral Rehabil* 37:262-270, 2010
- Alder ME, Deahl ST, Matteson SR, Van Sickels JE, Tiner BD, Rugh JD. Short-term changes of condylar position after sagittal split osteotomy for mandibular advancement. *Oral Surg Oral Med Oral Pathol Oral Radiol Endod* 87:159-165, 1999
- Pullinger A, Hollender L. Variation in condyle-fossa relationships according to different methods of evaluation in tomograms. *Oral Surg Oral Med Oral Pathol* 62:719-727, 1986
- Carvalho FdAR, Cevidanes LHS, da Motta ATS, de Oliveira Almeida MA, Phillips C. Three-dimensional assessment of mandibular advancement 1 year after surgery. *Am J Orthod Dentofacial Orthop* 137:S53-S55, 2010
- Imamura R. Assessment of the position and morphology of the condylar head of mandible after sagittal split ramus osteotomy: A postoperative comparative study from 1 to 6 months. *Int J Oral-Medical Sci* 15:139-151, 2017
- Yang HJ, Hwang SJ. Change in condylar position in posterior bending osteotomy minimizing condylar torque in BSSRO for facial asymmetry. *J Craniomaxillofac Surg* 42:325-332, 2014
- Han YS, Jung YE, Song I-S, Lee SJ, Seo BM. Three-dimensional computed tomographic assessment of temporomandibular joint stability after orthognathic surgery. *J Oral Maxillofac Surg* 74:1454-1462, 2016
- Westermarck A, Shayeghi F, Thor A. Temporomandibular dysfunction in 1,516 patients before and after orthognathic surgery. *Int J Adult Orthodon Orthognath Surg* 16:145-151, 2001
- Dujoncquoy J-P, Ferri J, Raoul G, Kleinheinz J. Temporomandibular joint dysfunction and orthognathic surgery: A retrospective study. *Head Face Med* 6:27, 2010
- Egermark I, Blomqvist JE, Cromvik U, Isaksson S. Temporomandibular dysfunction in patients treated with orthodontics in combination with orthognathic surgery. *Eur J Orthod* 22:537-544, 2000
- Ellis E III. Condylar positioning devices for orthognathic surgery: Are they necessary? *J Oral Maxillofac Surg* 52:536-552, 1994
- Hackney FL, Van Sickels JE, Nummikoski PV. Condylar displacement and temporomandibular joint dysfunction following bilateral sagittal split osteotomy and rigid fixation. *J Oral Maxillofac Surg* 47:223-227, 1989
- Ellis E III, Hinton RJ. Histologic examination of the temporomandibular joint after mandibular advancement with and without rigid fixation: An experimental investigation in adult *Macaca mulatta*. *J Oral Maxillofac Surg* 49:1316-1327, 1991
- Reinerman DM, Piecuch JE. Long-term effects of orthognathic surgery on the temporomandibular joint: Comparison of rigid and nonrigid fixation methods. *Int J Oral Maxillofac Surg* 24:268-272, 1995
- Bouwman JP, Kerstens HC, Tuinzing DB. Condylar resorption in orthognathic surgery: The role of intermaxillary fixation. *Oral Surg Oral Med Oral Pathol* 78:138-141, 1994
- Paulus G, Steinhauser E. A comparative study of wire osteosynthesis versus bone screws in the treatment of mandibular prognathism. *Oral Surg Oral Med Oral Pathol* 54:2-6, 1982
- Timmis DP, Aragon SB, Van Sickels JE. Masticatory dysfunction with rigid and nonrigid osteosynthesis of sagittal split osteotomies. *Oral Surg Oral Med Oral Pathol* 62:119-123, 1986
- Vale F, Francisco I, Scherzberg J, Guimarães A, Caramelo F, Maló L. Condylar response to large mandibular advancement combined with maxillary impaction and counterclockwise rotation: A computed tomographic study. *J Clin Exp Dentistry* 10:e891-e901, 2018