

## Treatment of Large-Scale Oral Plasmacytoma in a Patient with Multiple Myeloma

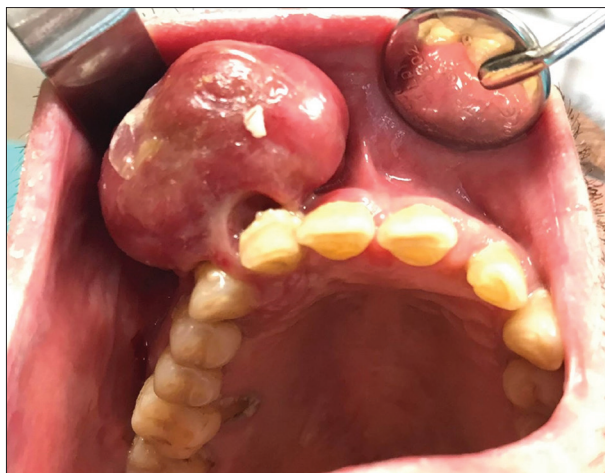### INTRODUCTION

Plasmacytoma is a rare malignant tumor originating from plasma cells in the bone marrow, or plasma cells alone, and also known as restricted type of multiple myeloma (MM). Lesions localized in bones are called solitary plasmacytoma and when they develop from soft tissues they are called extramedullary plasmacytoma.<sup>[1]</sup> In some cases, oral manifestations of extramedullary plasmacytoma can be the initial finding of the MM or can be the secondary finding.<sup>[2]</sup>

In the present case, we aimed to present the diagnosis and the treatment of an overlooked and large extramedullary plasmacytoma (EMP) in anterior maxilla in a patient with MM under bisphosphonate therapy.

### CASE REPORT

A 58-year-old male patient was referred to our clinic with swelling and pain in the right maxillary anterior region. On clinical examination, an erythematous, ulcerative, approximately 2 × 2 × 2 cm sized tumor was observed [Figure 1]. The patient failed to close the lips due to the size of the tumor. In addition, there was class 3 mobility in the associated teeth. The patient was on chemotherapy, taking warfarin and IV zoledronic acid for the treatment of MM. The excision of the tumor was planned because of pain during feeding. The patient was consulted to the Hematology Department to stop warfarin therapy. Within the approval of the Hematology Department warfarin therapy was stopped and the lesion was excised under local anesthesia when the INR level was 1.6. The teeth associated with tumor



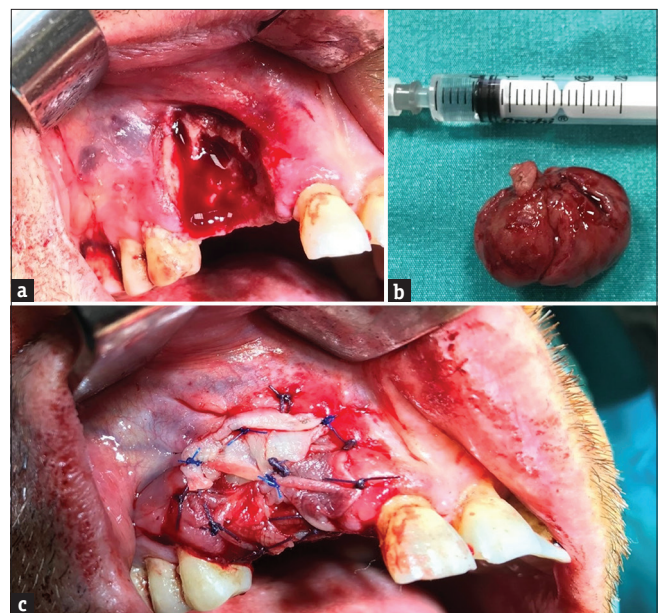
**Figure 1:** Intraoral view of the lesion. Note the erythematous, ulcerative, approximately 2 × 2 × 2 cm sized tumor

were extracted. Plasma rich fibrin (PRF) membrane and gel foam were used for covering exposed bone to limit the risk of bisphosphonate-related osteonecrosis of the jaws (BRONJ) [Figure 2]. The biopsy was reported as EMP. The patient continued to receive chemotherapy as arranged by oncologist. Uneventful healing was observed during a 3-month follow-up [Figure 3]. A 6-month follow-up of the lesion could not have been performed because the patient died.

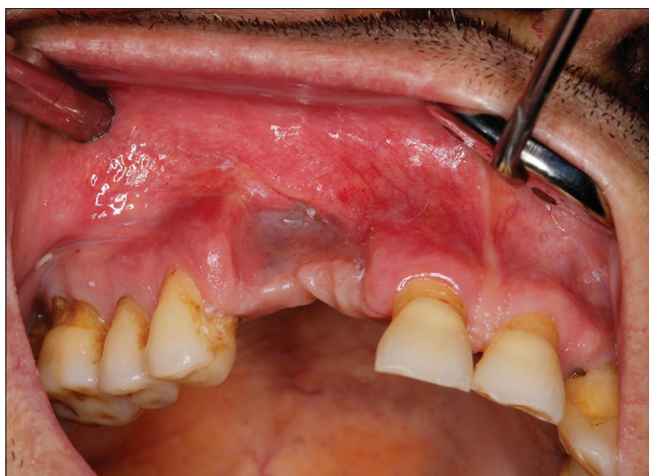### DISCUSSION

EMP of maxilla is extremely rare. Differential diagnosis includes peripheral giant cell granuloma, central giant cell granuloma and pyogenic granuloma, reactive plasmacytic hyperplasia, plasma cell granuloma, pseudolymphoma and malignancies such as hematopoietic neoplasms, malignant melanoma, olfactory neuroblastoma, anaplastic carcinoma, and metastases. The definitive diagnosis was made according to biopsy result.<sup>[3]</sup>

Oral manifestations of EMP include localized pain in the jaws and teeth, paraesthesia, swelling, soft tissue masses, mobility and migration of teeth, hemorrhage, and pathological fracture. Fatigue and fever are the most common systemic symptoms.<sup>[4]</sup> Our patient just had the expansion of anterior right maxilla and mobility in the associated teeth. He complained of pain during feeding and failing lip closure due to the size of tumor.



**Figure 2:** Intraoperative view of the surgical phase. (a) Affected bone area, (b) Biopsy specimen, (c) Plasma rich fibrin (PRF) membrane



**Figure 3:** Postoperative view at the 3-month follow-up

Treatment methods indicated in EMP include local surgery (curettage of the lesion), local irradiation, systemic chemotherapy, or a combination of these methods. Solitary plasmacytomas are highly radiosensitive lesions. Radiation therapy, radical extensive surgery, or a combination of both is recommended as primary treatment. Radical radiotherapy in the range of 40–50 Gy has been shown to control disease by 80%.<sup>[5]</sup> The role of adjuvant chemotherapy is at present not clearly defined. The addition of chemotherapy to radiotherapy in the treatment of EMP has not been shown to decrease local recurrence or increase survival rates compared with local treatment with radiotherapy alone, and therefore, should be reserved for those patients progressing to MM.<sup>[6]</sup> Surgery is rarely necessary but may be required in situations where plasmacytoma involvement of the bone causes skeletal instability and high risk of fracture. In these cases, radiation therapy may be delayed until after surgery.<sup>[7]</sup> In the present case, patient was unable to close his lips due to the size and volume of the lesion. Hence, surgical excision was preferred for the diagnosis and treatment of the lesion. The patient continues to receive chemotherapy as arranged by oncologist.

All patients with plasmacytomas require follow-up, at least, for the first five years after treatment has been completed. The course of EMP of bone is relatively benign and the 5-year survival rate of it is 60%; however, it falls to 5.7% when progression to multiple lesions occurs.<sup>[7]</sup> In the present case, however, long-term follow-up could not have been performed due to the loss of the patient.

## CONCLUSION

EMP of the jawbone mostly seen in the maxilla is a rare clinical condition. Oral manifestations of EMP can be the initial finding of the MM or can be the secondary finding. The purpose of this report is to underline how the rapid recognition is the basis for resolving the disease with the right treatment. In addition, successful treatment of EMP with PRF can be achieved even if the patient is on bisphosphonate therapy. The cooperation between oral and maxillofacial surgeons, radiologist, pathologist, and hematologist plays a decisive role for avoiding delay on performing the best treatment.

## Declaration of patient consent

Informed consent from the patient was obtained after providing detailed information of the necessary treatment. Furthermore, informed consent was also obtained for the publication of the procedure and follow-up treatment.

## Financial support and sponsorship

Nil.

## Conflicts of interest

There are no conflicts of interest.

*E Soylu, YN Kaba, T Pergel*

Department of Oral and Maxillofacial Surgery, Faculty of Dentistry, Erciyes University, Kayseri, Turkey

**Address for correspondence:** Dr. E Soylu, Department of Oral and Maxillofacial Surgery, Faculty of Dentistry, Erciyes University, Kayseri, Turkey. E-mail: dtemrahsoylu@hotmail.com

**Received:**

20-May-2019;

**Revision:**

30-Aug-2019;

**Accepted:**

09-Sep-2019;

**Published:**


10-Jan-2020

## REFERENCES

1. Pisano JJ, Coupland R, Chen SY, Miller AS. Plasmacytoma of the oral cavity and jaws. A clinopathological study of 13 cases. *Oral Surg Oral Med Oral Pathol* 1997;83:265-71.
2. Ramaiah KK, Joshi V, Thayi SR, Sathyanarayana P, Patil P, Ahmed Z. Multiple myeloma presenting with a maxillary lesion as the first sign. *Imaging Sci Dent* 2015;45:55-60.
3. Attanasio G, Viccaro M, Barbaro M, De Seta E, Filippo R. Extramedullary plasmacytoma of paranasal sinuses. A combined therapeutic strategy. *Acta Otorhinolaryngol Ital* 2006;26:118-20.

4. Poggio CE. Plasmacytoma of the mandible associated with a dental implant failure: A clinical report. *Clin Oral Implan Res* 2007;18:540-3.
5. Rodriguez-Caballero B, Sanchez-Santolino S, Garcia-Montesinos-Perea B, Garcia-Reija MF, Gomez-Roman J, Saiz-Bustillo R. Mandibular solitary plasmocytoma of the jaw: A case report. *Med Oral Patol Oral* 2011;16:e647-50.
6. Elias HG, Scott J, Metheny L, Quereshy FA. Multiple myeloma presenting as mandibular ill-defined radiolucent lesion with numb chin syndrome: A case report. *J Oral Maxillofac Surg* 2009;67:1991-6.
7. Jeong JA, Seo GE, Song JH, Park SJ. Solitary plasma cell myeloma on anterior maxilla: A case report. *Maxillofac Plast Reconstr Surg* 2010;32:77-80.

This is an open access journal, and articles are distributed under the terms of the Creative Commons Attribution-NonCommercial-ShareAlike 4.0 license, which allows others to remix, tweak, and build upon the work non-commercially, as long as appropriate credit is given and the new creations are licensed under the identical terms.

Access this article online	
<b>Quick Response Code:</b> 	<b>Website:</b> <a href="http://www.njcponline.com">www.njcponline.com</a>
	<b>DOI:</b> 10.4103/njcp.njcp_261_19

**How to cite this article:** Soylu E, Kaba YN, Pergel T. Treatment of large-scale oral plasmacytoma in a patient with multiple myeloma. *Niger J Clin Pract* 2020;23:125-7.