



Routine Histopathologic Examination of Appendectomy Specimens: Retrospective Analysis of 1255 Patients

Arif Emre¹, Sami Akbulut², Zehra Bozdog³, Mehmet Yilmaz², Murat Kanlioz¹, Rabia Emre⁴, Nurhan Sahin³

¹*Department of Surgery, Malatya State Hospital, 44300 Malatya, Turkey*

²*Department of Surgery, Inonu University Faculty of Medicine, 44280 Malatya, Turkey*

³*Department of Pathology, Malatya State Hospital, 44300 Malatya, Turkey*

⁴*Malatya Public Health Center, 44300 Malatya, Turkey*

The objective of this study was to analyze the clinical benefit of histopathologic analysis of appendectomy specimens from patients with an initial diagnosis of acute appendicitis. We retrospectively analyzed the demographic and histopathologic data of 1255 patients (712 males, 543 females; age range, 17–85 years) who underwent appendectomy to treat an initial diagnosis of acute appendicitis. Patients who underwent incidental appendectomy during other surgeries were excluded from the study. Histopathologic findings of the appendectomy specimens were used to confirm the initial diagnosis. Ninety-four percent of the appendectomy specimens were positive for appendicitis. Of those, 880 were phlegmonous appendicitis, 148 were gangrenous appendicitis with perforation, and the remaining 88 showed unusual histopathologic findings. In the 88 specimens with unusual pathology, fibrous obliteration was observed in 57 specimens, carcinoid tumor in 11, *Encheliophis vermicularis* parasite infection in 8, granulomatous inflammation in 6, appendiceal endometriosis in 2, and 1 specimen each showed mucocele, eosinophilic infiltration, *Taenia saginata* parasite infection, and appendicular diverticulitis. All carcinoid tumors were located in the distal appendix. Six of the 11 carcinoid tumors were defined by histopathology as involving tubular cells, and the other 5 as involving enterochromaffin cells. Six patients had muscularis propria invasion, 2 patients had submucosa invasion, 2 patients had mesoappendix invasion, and 1 patient had serosal

Reprint requests: Sami Akbulut, MD, Liver Transplant Institute, Inonu University Faculty of Medicine, 44280 Malatya, Turkey.
Tel.: +90 422 3410660; Fax: +90 422 3410036; E-mail akbulutsami@gmail.com

invasion. All patients with tumors remained disease free during the follow-up (range, 1–27 months). We conclude that when the ratio of unusual pathologic findings for appendectomy specimens is considered, it is evident that all surgical specimens should be subjected to careful histologic examination.

Key words: Appendicitis – Carcinoid – Oxyuris – Taeniasis – Mucocele – Endometriosis – Appendiceal neuroma

Acute appendicitis is defined as an inflammation of the inner lining of the appendix vermiformis, which then spreads to other parts of the organ. Various etiologies for this clinic-pathologic condition have been identified, but luminal obstruction is considered the most critical factor, as it triggers the inflammatory process.^{1–20} When lumen obstruction occurs, intraluminal pressure surpasses that in the appendiceal veins, causing venous outflow obstruction. Finally, ischemia develops in the appendiceal wall, which weakens the epithelial integrity and increases the organ's risk of bacterial invasion. Although lymphoid hyperplasia and fecaliths are the most common causative factors of luminal obstruction, other less frequent factors have been associated with the condition, including enterobiasis,¹ endometriosis,^{1,16,21} tuberculosis,¹ amebiasis,¹ actinomycosis,¹ adenovirus,⁴ granulomatous diseases,^{1,7,15,19} eosinophilic granuloma,⁸ neurogenic appendicopathy,^{11,12} foreign body melanosis,⁴ neurofibroma,⁴ diverticulitis,^{1,9,20} and taeniasis,^{1,17,21} as well as appendiceal malignancies, such as carcinoid tumor,^{1,13,14} gastrointestinal stromal tumor,¹ hyperplastic polyp,¹ tubular adenoma,¹ villous adenoma,¹ mucocele,¹⁰ mucinous cystadenoma,¹ adenocarcinoma,¹ mucinous cystadenocarcinoma,¹ lymphoma,¹ and leukemia.¹ This study was designed to investigate the occurrence and distribution of unusual pathologic findings encountered in appendectomy specimens of patients who had undergone surgery to treat an initial diagnosis of acute appendicitis.

Materials and Methods

The demographic data and histopathologic findings of patients who underwent appendectomy at the Malatya State Hospital (Malatya, Turkey) between January 2009 and January 2012 were retrieved from the hospital's electronic record system and retrospectively analyzed. Patients were selected for study inclusion according to the following criteria: ≥ 16 years of age and receipt of appendectomy to treat an

initial diagnosis of acute appendicitis. Patients were excluded according to the following criteria: age < 16 years old or receipt of incidental appendectomy during other surgical procedures. Three investigators (A.E., M.K., and Z.B.) working independently evaluated the pathology reports of all patients included in the study. The pathology slides of all cases showing unusual histopathologic findings were reevaluated by 2 experienced pathologists (Z.B. and N.S.).

Based on the histopathologic findings, the appendectomy specimens were classified as either *positive* for acute appendicitis features or *negative* for acute appendicitis features. Positive specimens showed the presence of fecaliths or worms, neurogenous hyperplasia, appendiceal neuroma, granulomatous inflammation, foreign body reaction, mucocele, endometriosis, cystadenoma, or appendiceal tumors. Negative specimens were microscopically normal, with no evidence of inflammation or appendiceal neuroma.³ Follow-up was done concerning all patients to determine survival and complications in the postoperative period. For this study, the follow-up period was calculated as months from the date of appendectomy until the final clinical information was reported in the electronic database, or up to February 2012.

Results

Characteristics of patients who underwent appendectomy

A total of 1255 patients met the inclusion criteria, including 712 (56.7%) males and 543 (43.3%) females. The mean age was 30.0 ± 11.9 years (range, 17–85 years), and the majority of the patients (61.7%) were < 30 years old, with only 7% of patients > 50 years old. The demographic and histopathologic characteristics of the 1255 patients are summarized in Table 1.

Histopathologic findings indicated that 1179 (94%) of the appendectomy specimens were positive for acute appendicitis. Among these, 880 were phlegmonous appendicitis, and 148 were gangre-

Table 1 Demographic and pathologic characteristics of 1255 patients who underwent appendectomy for presumptive diagnosis of acute appendicitis

Patients' characteristics	Results
Patients (n)	1255
Sex [n (%)]	
Male	712 (56.7)
Female	543 (43.3)
Age [mean \pm SD (range)]	
Overall	30 \pm 11.9 (17–85)
Female	31 \pm 12 (17–74)
Male	29.2 \pm 11.9 (17–85)
Distribution of patients according to age range [n (%)]	
17–20 y	308 (24.5)
21–30 y	466 (37.1)
31–40 y	265 (21.1)
41–50 y	127 (10.1)
51–60 y	52 (4.1)
>60 y	37 (3.0)
Distribution of patients according to histopathologic findings	
Positive appendectomy [n (%)]	1179 (100)
Acute phlegmonous appendicitis	880 (74.6)
Acute gangrenous appendicitis perforated	148 (12.6)
Lymphoid hyperplasia	63 (5.3)
Unusual histopathologic findings	88 (7.5)
Negative appendectomy [n (%)]	76 (100)
Male	30 (39.5)
Female	46 (60.5)
Appendix vermiformis	58 (76.3)
Other pathologic conditions without appendicitis	18 (23.7)
Ovarian cyst rupture	9
Gangrenous cholecystitis	3
Double meckel diverticulitis	1
Cecum adenocarcinoma	1
Splenosis in mesoappendix	1
Meckel diverticulitis	1
Ovarian carcinoma right	1
Ruptured ectopic pregnancy	1
Distribution of patients with negative appendectomy according to age range [n (%)]	
17–20 y	2 (2.6)
21–30 y	30 (39.5)
31–40 y	29 (38.2)
41–50 y	10 (13.1)
>50 y	5 (6.6)

nous appendicitis with perforation. Sixty-three were defined as lymphoid hyperplasia. Unusual pathology was found in 88 specimens.

Seventy-six of the specimens, accounting for 6.0% of the total, showed no pathology that supported the initial diagnosis of appendicitis, and they were classified as negative specimens. Fifty-eight (76.3%) of these cases had undergone laparotomy with a McBurney incision, and the appendectomy procedure was standard. In 18 (31.0%) of the laparotomy cases, the appendix vermiformis appeared normal upon microscopic analysis, and other pathologic conditions were revealed upon further

testing. Specifically, cystic rupture was found in 9 patients, severe gangrenous cholecystitis in 3 patients, and splenosis of the mesoappendix in 1 case. The remaining 5 laparotomy cases with normal appendix vermiformis were characterized, respectively, as double Meckel's diverticulitis, Meckel's diverticulitis, cecal adenocarcinoma, right ovarian carcinoma, and ruptured ectopic pregnancy. When the age distribution of the patients with negative appendectomy specimens was evaluated, 73.7% were <30 years old. Therefore, negative laparotomy rates decreased with increasing age.

Table 2 Clinicopathologic features of the 88 patients with unusual histopathologic findings

Patients' characteristics	Results
Patients (n)	88
Age [mean \pm SD (range)], y	34.5 \pm 15.9 (17–72)
Sex [n (%)]	
Male	36 (41)
Female	52 (59)
Histopathologic findings [n (%)]	
Fibrous obliteration	57 (64.8)
Carcinoid tumor	11 (12.5)
<i>E. vermicularis</i>	8 (9.0)
Granulomatous inflammation	6 (6.8)
Endometriosis	2 (2.3)
Mucocele	1 (1.1)
Eosinophilic infiltration	1 (1.1)
<i>T. saginata</i>	1 (1.1)
Appendicular diverticulitis	1 (1.1)
Surgical approach (n)	
Appendectomy	88
Follow-up [mean \pm SD (range)], mo	15.9 \pm 9.5 (1.0–36.5)
Recurrence or complication [n (%)]	1 (scar endometriosis)

Evaluation of patients with unusual histopathologic findings

Unusual histopathologic findings were detected in 88 (7.0%) of the total patients who underwent appendectomy. The clinicopathologic characteristics of these patients are summarized in Table 2. Fifty-two of these patients were female, and 36 were male. The mean age of this group was 34.5 \pm 15.9 years (range, 17–72 years). Fifty-seven of the specimens with unusual pathology showed fibrous obliteration, also known as neurogenous hyperplasia or appendiceal neuroma (Fig. 1a). In addition, 11 of the specimens had a carcinoid tumor (Fig. 1b), 8 had an *Enterobius vermicularis* parasite infection (Fig. 1c), 6 had granulomatous inflammation (Fig. 1d), 2 had appendiceal endometriosis (Fig. 1e), and 1 specimen each had mucocele, eosinophilic infiltration, *Taenia saginata* parasite infection (Fig. 1f), and appendicular diverticulitis.

The age distribution of the patients with fibrous obliteration included 37 (65%) <40 years old, 13 (22.8%) between 40 and 60 years old, and 7 (12.2%) >60 years old. Evaluation of the medical histories of the 6 patients with granulomatous inflammation revealed no cases of tuberculosis or Crohn's disease. The 2 patients with appendiceal endometriosis were female, married with children, and had no history of endometriosis prior to the appendectomy. Moreover, physical examination and abdominal ultrasonography findings for both of these patients were consistent with acute appendicitis. In another 45-year-old female patient, McBurney scar endometri-

osis, characterized by frequent pain, was reported to have developed at month 6 after the appendectomy; the subsequent clinical management included removal of a mass $\sim 3 \times 3$ cm in size at the scar site.

None of the 11 patients with an initial diagnosis of acute appendicitis but with a histologic diagnosis of carcinoid tumor had exhibited symptoms of carcinoid syndrome or been preoperatively diagnosed with an appendicular tumor. The detailed clinicopathologic characteristics of these patients are summarized in Table 3. All histologically detected tumors were located in the distal appendix. The mean diameter of these tumors was 5.7 \pm 3.1 mm (range, 3–12 mm). Six of these tumors were characterized as tubular cell carcinoid, and 5 were characterized as enterochromaffin cell carcinoid. Six of the 11 carcinoid tumor patients had muscularis propria invasion, 2 had submucosa invasion, 2 had mesoappendix invasion, and 1 had serosal invasion. Following pathologic confirmation of the diagnosis, each of these 11 patients was referred to the affiliated University Hospital for staging and close follow-up. All 11 patients survived and were disease free during the mean follow-up period of 12.9 \pm 9.5 (1–27 months).

Discussion

Acute appendicitis is one of most frequent indicators of acute abdominal surgical intervention, and appendectomy is one of the most common surgical procedures performed worldwide.^{1,4,5,20,22–24} The

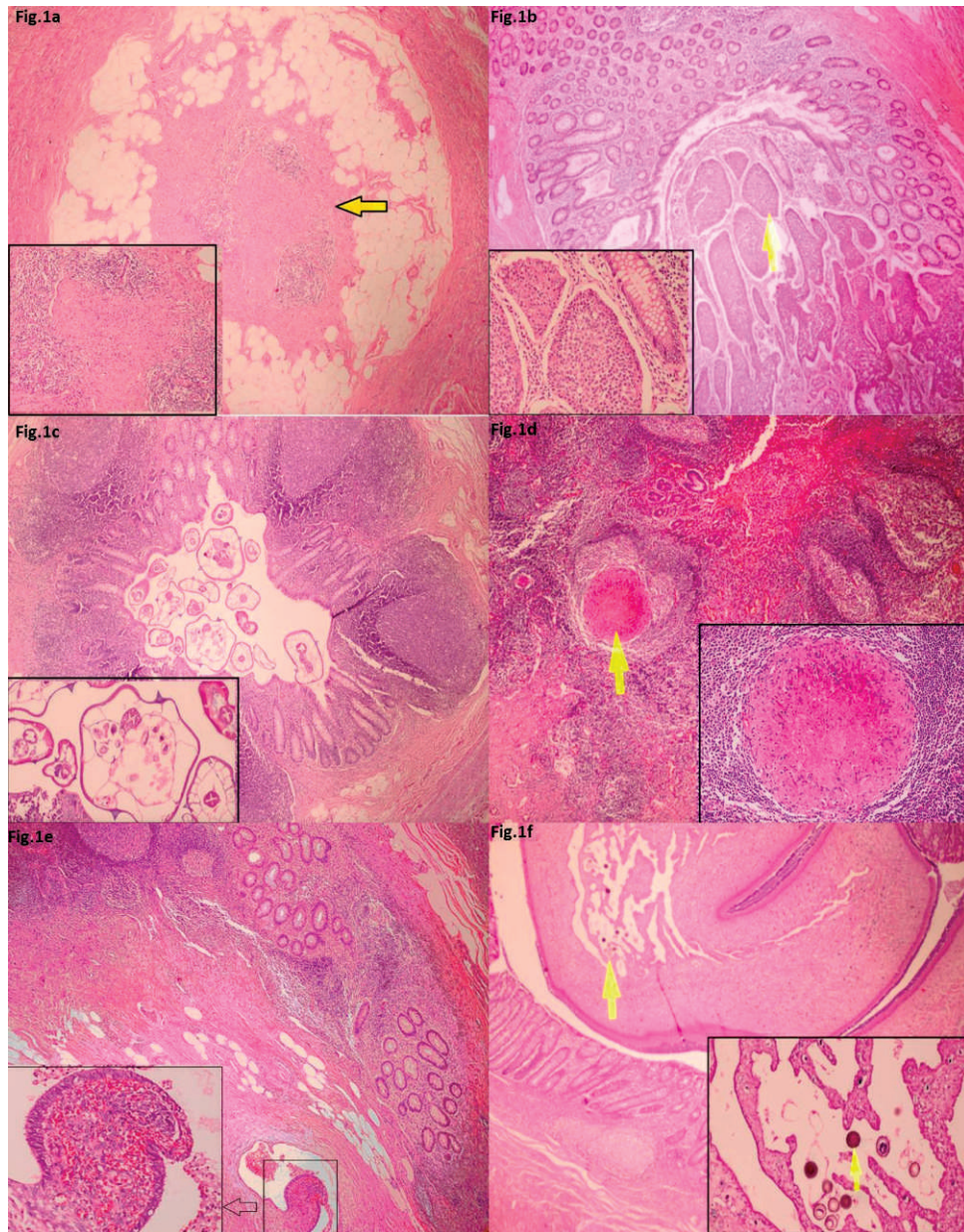


Fig. 1 Unusual histopathologic findings. (a) Fibrous obliteration. Spindle cell proliferation appeared to cause the obliteration. Loss of lymphoid follicles and mucosa were apparent in the appendix lumen [hematoxylin and eosin (H&E) $\times 40$]. (b) Carcinoid tumor. Solid islands of carcinoid tumor consisting of cells with granular eosinophilic cytoplasm. Minimal pleomorphism was found within the submucosa (H&E $\times 40$). (c) *E. vermicularis*. Cross section of *E. vermicularis* in the appendix lumen (H&E $\times 40$). (d) Granulomatous appendicitis. Submucosal granuloma with central necrosis in the lymphoid tissue (H&E $\times 40$). (e) Appendiceal endometriosis. Focus of endometriosis-containing endometrial glands and stroma within the muscular layer proximal to the appendicular mucosa (H&E $\times 40$). (f) *T. saginata*. Cross section of a proglottid of *T. saginata*. Eggs were apparent in the appendix lumen (H&E $\times 40$).

incidence of acute appendicitis roughly parallels that of lymphoid development, with peak incidence occurring between the ages of 10 and 30 years. Although there is sex ratio equality in acute appendicitis cases occurring before puberty, the

frequency in males begins to increase gradually at puberty; by the age of 15 to 25 years old, the sex ratio has shifted to 2:1 in favor of men. This bias decreases with age, and the related incidence again becomes equal. The lifetime incidence of acute

Table 3 Detailed demographic and pathologic characteristics of the 11 patients with appendicular carcinoid tumors

Patient ID	Age/ sex	Tumor size, mm	Tumor location	Surgical approach	Invasion of mesoappendix	Cell type	Parietal spread	Nuclear pleomorphism	Mitosis, 10HPF	Ki-67, %	Necrosis	Follow-up, mo
RK	34/M	3	Distal	Appendectomy	No	Tubular	M. propria	None	Neg	0	Neg	1
BK	35/M	6	Distal	Appendectomy	No	EC	M. propria	None	1	1	Neg	1
EE	18/M	8	Distal	Appendectomy	No	EC	Serosa	None	Neg	2	Neg	1
BM	19/M	12	Distal	Appendectomy	Yes	EC	Mesoapp	None	Neg	2	Neg	13
CB	85/M	2	Distal	Appendectomy	No	Tubular	Submucosa	None	Neg	1	Neg	8
EK	17/M	10	Distal	Appendectomy	No	Tubular	M. propria	None	1	1	Neg	15
CC	33/F	4	Distal	Appendectomy	No	Tubular	M. propria	None	Neg	1	Neg	27
EB	19/M	8	Distal	Appendectomy	Yes	EC	Mesoapp	None	Neg	1	Neg	26
MT	19/M	4	Distal	Appendectomy	No	EC	Submucosa	None	1	2	Neg	26
DK	17/F	3	Distal	Appendectomy	No	Tubular	M. propria	None	Neg	0	Neg	13
TU	49/F	3	Distal	Appendectomy	No	Tubular	M. propria	None	1	1	Neg	11

EC, enterochromaffin cell; F, female; M, male; M. propria, muscularis propria; Neg, negative.

appendicitis is estimated to be 7.0% overall, with 8.6% for men and 6.7% for women; however, the lifetime incidence of appendectomy is much lower for males than for females (12% versus 23%, respectively).^{2,23,24}

The diagnosis of acute appendicitis relies on an evaluation of the patient's history, laboratory and radiologic findings, as well as the surgeon's subjective judgment based on experience. However, the reported rates of histology-proven negative cases following appendectomy have ranged between 9.2% and 35.0%.^{2,3,23,24} Intriguingly, the rates of negative cases are particularly high for women during child-bearing years.^{4,23,24} The rate of negative appendectomy found in the current study (6.0%) is low compared to that in the collective literature. However, if patients requiring surgery are denied the procedure in order to avoid the risk of performing a negative laparotomy, there may be an increased risk of undesirable clinical events, such as perforation. In the current study, the perforation rates were similar to those in the collective literature.

Differential diagnosis of acute appendicitis can be made in most patients with abdominal ultrasonography (US), computed tomography (CT), or diagnostic laparoscopy. US is valuable in the diagnosis of doubtful cases of appendicitis and is a cost-efficient adjunct to the clinical evaluation. CT has emerged as the leading imaging modality for adult patients whose diagnosis is not obvious from a patient's history, physical examination, and other radiologic tools. CT is a quick and accurate examination that is operator-independent and relatively easy to perform and provides images that are easy to interpret. CT is also very successful in the differential diagnosis of other appendicular diseases.^{25,26}

Development of luminal obstruction, regardless of etiology, has been proposed as the most significant factor in the etiopathogenesis of acute appendicitis. While the most commonly encountered underlying condition of acute appendicitis in the first two decades of life is lymphoid hyperplasia, in elderly patients it is fecal obstruction. In the current study, apart from these common factors, several unusual factors were also determined as the causes of clinical symptoms of acute appendicitis as well as the symptoms that mimicked the condition. As this study's objective was focused on investigating unusual factors, more emphasis is given to these factors in the Discussion section.

It has been reported that ~30% of resected appendix specimens show fibrous obliteration. Despite its descriptive name, this occlusive process

has been shown to predominantly comprise neurogenic proliferation. As such, neurogenic appendicopathy and appendiceal neuroma have recently been proposed as alternative diagnostic terminology. Regardless, the molecular mechanisms underlying this pathogenic process remain unknown. It is believed to develop secondary to hyperplasia of neuroendocrine cells, because appendiceal lumen replacement by fibrous tissue and chronic inflammatory cells is generally accompanied by remarkably increased proliferation of nerve cells and neuroendocrine cells. Differential diagnosis between appendiceal neuroma and acute appendicitis is difficult and relies on the patient's clinical history, symptoms, and laboratory and physical examination findings. Most appendiceal neuromas are found incidentally, when pathologic examination of the appendix reveals fibrous obliteration in asymptomatic patients.^{11,12}

Carcinoid tumor, which is considered to be the most common type of appendiceal primary malignant lesion and accounts for ~60% of all appendiceal tumors, is found in 0.3% to 2.3% of patients undergoing an appendectomy. It is rare for carcinoids to be diagnosed preoperatively, and they are usually found incidentally during appendectomy.^{1,13,14} In 70% to 95% of cases, the carcinoid tumors are <1 cm and are located at the tip of the appendix.¹ The majority of appendiceal carcinoids are benign, and metastases are rare. A near zero rate of calculated risk of metastasis from tumors <1 cm allows for management by simple appendectomy. However, increased tumor size (≥ 2 cm) is associated with a remarkably increased (up to 85%) risk of metastasis. Therefore, appendiceal carcinoid tumor >2 cm is usually managed by formal right hemicolectomy.^{1,6,13,14} The incidence of appendiceal carcinoid in the patient series presented herein (0.8%) was similar to that of other published studies in the collective literature.

The parasitic infection *E. vermicularis* (also known as pinworms, seatworms, or threadworms) is extremely common among the world's population, and it is estimated to currently affect up to 200 million people. The association of *E. vermicularis* infection with appendicitis was first reported in the late 19th century, with the presence of the organism being related to the appendix lumen. Previous reports of the incidence of *E. vermicularis* in appendectomy specimens of patients with presumed appendicitis have ranged from 0.2% to 41.8%, while rates of inflammation in appendices infested with these pinworms has ranged from 13%

to 37%.¹ The incidence of pinworms in the current patient series (0.6%) was similar to that of other published studies.

Granulomatous appendicitis may be discovered incidentally in a patient with a clinical presentation of acute appendicitis. The incidence of this rare condition has been reported as 0.14% to 0.3% in Western countries and as 1.3% to 2.3% in underdeveloped countries.^{7,15} Diagnostic criteria include granulomatous inflammation, transmural lymphoid aggregates, and fissuring-type ulcers, similar to the diagnostic features in the gastrointestinal (GI) tract. Granulomatous appendicitis can be caused by various infectious and noninfectious factors. Systemic conditions, such as Crohn's disease and sarcoidosis, may also be associated with granulomatous inflammation of the appendix. However, in the majority of cases, the initial belief that this condition was a manifestation of Crohn's disease was proven incorrect; indeed, only 5% to 10% of patients with granulomatous appendicitis develop signs of Crohn's disease elsewhere in the GI tract. Infectious causes of granulomatous appendicitis include *Yersinia* spp, *Mycobacterium tuberculosis*, blastomycosis, *Schistosoma* spp, *Actinomyces* spp, *Campylobacter* spp, and *Histoplasma capsulatum*.^{1,7,15,19} In the current study, 0.47% of patients were histologically diagnosed with granulomatous inflammation. As tuberculosis is endemic in the study region, these patients were subjected to detailed testing for this infectious condition; however, no positive findings for tuberculosis were obtained.

Endometriosis is defined as the presence of ectopic endometrial tissue outside of the uterine cavity. Although many women of reproductive age suffer from this disease, a GI tract location is rare. Intestinal endometriosis is classified as external endometriosis and occurs in only ~10% of women with endometriosis. Most intestinal endometriosis occurs in the rectum and sigmoid colon, and occurrence in the appendix is rare. Appendiceal endometriosis is usually asymptomatic, although it can occasionally cause appendicitis, perforation, and intussusception. The histologic presence of endometrial tissue in the specimen is the basis for diagnosis of appendiceal endometriosis.^{1,16,21}

Taeniasis is characterized by the presence of the helminth in the intestine, and the infection is generally recognized when a segment of the parasite appears in the stool. Although there are reports in the literature showing association between *Taenia* spp and appendicitis, the underlying mechanism is

not yet fully understood. Fortunately, identification of the specific species is not required for treatment of taeniasis cases, as the infections are effectively resolved with a single dose of praziquantel.^{1,22}

First described in 1842, mucocele is an obstructive dilatation of the appendix resulting from intraluminal accumulation of mucoid material.¹ The incidence of this condition in appendectomy specimens has been reported as 0.2% to 0.7%. Four histologic types of appendiceal mucocele have been described: retention cyst, mucosal hyperplasia, mucinous cystadenoma, and mucinous cystadenocarcinoma. Mucoceles are often asymptomatic and are usually discovered incidentally during appendectomy, laparotomy for another indication, or the histologic examination of an operative specimen. The standard treatment for mucinous cystadenoma is appendectomy, whereas a cystadenocarcinoma requires a right hemicolectomy.^{1,10}

Appendiceal diverticula are very rare, and the reported incidence in appendectomy specimens has ranged from 0.004% to 2.1%.^{9,20} Diverticula may occur singly or multiply, but are usually smaller than 0.5 cm and located within the distal third of the appendix on the mesenteric side. The etiologies of diverticula are congenital or acquired. The congenital form of true diverticulum is extremely rare; the more prevalent acquired diverticulum is characterized as a false diverticulum or pseudodiverticulum, consisting of mucosa and submucosa herniated through vascular clefts in the muscular layer. Four variants of diverticular disease of the appendix are recognized: appendiceal diverticula without inflammation, acute appendicitis with diverticula, acute appendiceal diverticulitis with acute appendicitis, and isolated acute diverticulitis. Appendicular diverticulosis is usually asymptomatic, but the most common complications (perforation and inflammation) can cause abdominal pain that mimics acute appendicitis.^{9,20}

In the current study, we sought to determine the occurrence and type of unusual factors in acute appendicitis cases or in cases that mimicked the clinical presentation of acute appendicitis. The findings are expected to help answer two key questions related to clinical management of these cases. First, how much importance should be given to the topic of acute appendicitis in the basic training of general surgeons? Second, what is the benefit to the patient or clinician of histopathologic examination of every appendectomy specimen? We may start to answer these questions by considering some case examples related to our findings. Appen-

diceal endometriosis may be the first indication of underlying pelvic endometriosis, which is an important cause of infertility.^{16,21} Therefore, the histopathologic examination strategy may benefit women of child-bearing age by facilitating diagnosis of endometriosis and initiation of interventional treatments.

Granulomatous appendicitis may be the first indication of tuberculosis, an important risk of patients living in tuberculosis-endemic regions, or of Crohn's disease. For both conditions, the histopathologic examination may enable early initiation of specific treatment. Parasite infections of the intestinal system, such as those involving *E vermicularis*, *T saginata*, or *Enterobius histolitica*, often manifest rather generalized symptoms, such as perianal irritation, tenesmus, flatulence, loss of appetite, and inability to gain weight. Incidental diagnosis of parasites in appendectomy specimens may allow for initiation of anti-helminth treatment. Most appendix carcinoids and primary adenocarcinoma are diagnosed incidentally during surgery for acute appendicitis. Certainly, early diagnosis of cancer and initiation of treatment is extremely beneficial to patient survival. Therefore, even when appendectomy specimens show normal macroscopic features, histopathologic analyses may provide clinically useful insights into the patient's condition and help to improve patient outcome by revealing a previously unrecognized disease.

References

1. Akbulut S, Tas M, Sogutcu N, Arikanoglu Z, Basbug M, Ulku A. Unusual histopathological findings in appendectomy specimens: a retrospective analysis and literature review. *World J Gastroenterol* 2011;**17**(15):1961-1970
2. Zdichavsky M, Gögele H, Blank G, Kraulich M, Meile T, von Feilitzsch M. Histological characterization of appendectomy specimens with intraoperative appearance of vascular injection. *Surg Endosc* 2013;**27**(3):849-853
3. Chandrasegaram MD, Rothwell LA, An EI, Miller RJ. Pathologies of the appendix: a 10-year review of 4670 appendectomy specimens. *ANZ J Surg* 2012;**82**(11):844-847
4. Marudanayagam R, Williams GT, Rees BI. Review of the pathological results of 2660 appendectomy specimens. *J Gastroenterol* 2006;**41**(8):745-749
5. Swank HA, Eshuis EJ, Ubbink DT, Bemelman WA. Is routine histopathological examination of appendectomy specimens useful? A systematic review of the literature. *Colorectal Dis* 2011;**13**(11):1214-1221
6. Duzgun AP, Moran M, Uzun S, Ozmen MM, Ozer VM, Seckin S. Unusual findings in appendectomy specimens: evaluation

- of 2458 cases and review of the literature. *Indian J Surg* 2004; **66**(4):221–226
7. AbdullGaffar B. Granulomatous diseases and granulomas of the appendix. *Int J Surg Pathol* 2010; **18**(1):14–20
 8. Aravindan KP, Vijayaraghavan D, Manipadam MT. Acute eosinophilic appendicitis and the significance of eosinophil-edema lesion. *Indian J Pathol Microbiol* 2010; **53**(2):258–261
 9. Manzanares-Campillo Mdel C, Pardo-García R, Martín-Fernández J. Appendicular pseudodiverticula and acute appendicitis. Our 12-year experience. *Rev Esp Enferm Dig* 2011; **103**(11):582–585
 10. Demetrashvili Z, Chkhaidze M, Khutsishvili K, Topchishvili G, Javakhishvili T, Pipia I. Mucocele of the appendix: case report and review of literature. *Int Surg* 2012; **97**(3):266–269
 11. Gupta K, Solanki A, Vasishtha RK. Appendiceal neuroma: report of an elusive neuroma. *Trop Gastroenterol* 2011; **32**(4):332–333
 12. Patel AV, Friedman M, MacDermott RP. Crohn's disease patient with right lower quadrant abdominal pain for 20 years due to an appendiceal neuroma (fibrous obliteration of the appendix). *Inflamm Bowel Dis* 2010; **16**(7):1093–1094
 13. Shapiro R, Eldar S, Sadot E, Papa MZ, Zippel DB. Appendiceal carcinoid at a large tertiary center: pathologic findings and long-term follow-up evaluation. *Am J Surg* 2011; **201**(6):805–808
 14. In't Hof KH, van der Wal HC, Kazemier G, Lange JF. Carcinoid tumour of the appendix: an analysis of 1,485 consecutive emergency appendectomies. *J Gastrointest Surg* 2008; **12**(8):1436–1438
 15. Tucker ON, Healy V, Jeffers M, Keane FB. Granulomatous appendicitis. *Surgeon* 2003; **1**(5):286–289
 16. Akbulut S, Dursun P, Kocbiyik A, Harman A, Sevmis S. Appendiceal endometriosis presenting as perforated appendicitis: report of a case and review of the literature. *Arch Gynecol Obstet* 2009; **280**(3):495–497
 17. Sartorelli AC, da Silva MG, Rodrigues MA, da Silva RJ. Appendiceal taeniasis presenting like acute appendicitis. *Parasitol Res* 2005; **97**(2):171–172
 18. Jones AE, Phillips AW, Jarvis JR, Sargen K. The value of routine histopathological examination of appendectomy specimens. *BMC Surg* 2007; **7**:17
 19. Shivakumar P, Shanmugam RP, Mani CS. Idiopathic granulomatous appendicitis: a rare appendicular pseudo tumor. *Trop Gastroenterol* 2010; **31**(2):130–131
 20. Coulier B, Pierard F, Malbecq S. Appendicular diverticulitis in an Amyand's hernia. *JBR-BTR* 2010; **93**(2):114
 21. Emre A, Akbulut S, Yilmaz M, Bozdog Z. An unusual cause of acute appendicitis: appendiceal endometriosis. *Int J Surg Case Rep* 2012; **4**(1):54–57
 22. Hafezi Ahmadi M, Seifmanesh H. Taeniasis caused appendicitis without local tenderness: a rare case. *Hospital Chronicles* 2011; **6**(4):207–209
 23. Khairy G. Acute appendicitis: is removal of a normal appendix still existing and can we reduce its rate? *Saudi J Gastroenterol* 2009; **15**(3):167–170
 24. Seetahal SA, Bolorunduro OB, Sookdeo TC, Oyetunji TA, Greene WR, Frederick W. Negative appendectomy: a 10-year review of a nationally representative sample. *Am J Surg* 2011; **201**(4):433–437
 25. Brown MA. Imaging acute appendicitis. *Semin Ultrasound CT MR* 2008; **29**(5):293–307
 26. Jain RK, Jain M, Rajak CL, Mukherjee S, Bhattacharyya PP, Shah MR. Imaging in acute appendicitis: a review. *Indian J Radiol Imaging* 2006; **16**(4):523–532