



Subcoracoid dislocation of the acromioclavicular joint

Kerem M. CANBORA¹, Tolga TÜZÜNER², Serhat H. YANIK¹, Mücahit GÖRGEÇ¹

¹Department of Orthopedics and Traumatology, Haydarpaşa Numune Training and Research Hospital, İstanbul, Turkey;

²Department of Orthopedics and Traumatology, Bezmialem Vakıf University School of Medicine, İstanbul, Turkey

Subcoracoid acromioclavicular dislocations are rarely seen injuries of the shoulder. We present a patient with multiple injuries and a subcoracoid acromioclavicular dislocation resulting from a falling injury. Physical examination revealed painful mechanical block at 90 degrees of abduction and swelling in the acromioclavicular region. Diagnosis was made with direct radiographs and computerized tomography. Treatment consisted of distal clavicular resection and coracoclavicular reconstruction with the transfer of the coracoacromial ligament over the clavicle. The patient had a pain-free shoulder after two years and was capable of performing daily activities despite the presence of coracoclavicular ossification.

Key words: Acromioclavicular joint; dislocation.

Acromioclavicular joint injuries are classified according to the degree of injury to the acromioclavicular and coracoclavicular ligaments. Tossy et al. first described three types of acromioclavicular dislocation.^[1] Rockwood developed the currently used classifications with the addition of new dislocation types.^[2] These classifications are used to decide the suitable treatment modality. Type 1 and 2 injuries should be treated with pain control and progressive rehabilitation. Treatment of Type 3 injuries is still debated; and both conservative and surgical methods can be used.^[3] Type 4, 5, and 6 injuries nearly always require operative intervention. Type 6 injuries are very rare. Gerber and Torrens published 4 cases in which the distal clavicle was trapped under the acromion or coracoid.^[4,5] Injuries of this type are often the result of severe trauma and the mechanism of injury is thought to be forceful abduction and external rotation of the arm. Associated fractures, including clavicle, upper ribs and neurologic injuries, can be seen. No consensus regarding the exact surgical technique has yet been established.

We used a modified Weaver-Dunn technique which included the transfer of the coracoacromial ligament to the distal clavicle with suture augmentation. Most recent data support the effectiveness of this technique.^[3,6,7]

Case report

A 28-year-old woman sustained multiple injuries to the skeleton, including an inferior (subcoracoid) dislocation of the distal end of the clavicle, following a falling injury. The patient with unstable vital signs was not cooperative. On physical examination, there was a painful mechanical block to abduction of the shoulder at 90 degrees. There was minimal swelling with tenderness over the acromioclavicular joint area. The acromion was prominent, and the superior surface of the coracoid process was easily palpated. Radiographs, computerized tomography (CT) and three-dimensional CT showed the subcoracoid location of the clavicle leading to diagnosis of subcoracoid acromioclavicular joint dislocation (Fig. 1).

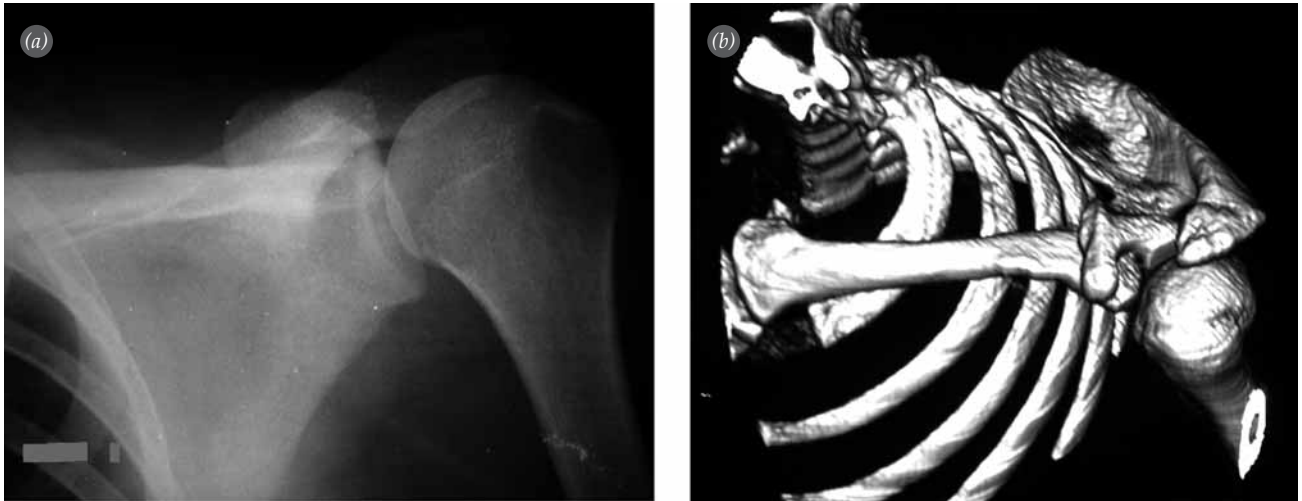


Fig. 1. Preoperative (a) AP radiography and (b) 3D CT image.

Neurovascular examination of the left upper extremity and electromyography revealed normal findings.

Sixteen days after the injury, the patient's condition became stable and open reduction was performed. Following the distal resection, two bone tunnels in the superior portion of the distal clavicle were created, exiting into the intramedullary canal. The coracoacromial ligament was then transected sharply from its acromial attachment. The free ends of the suture were passed into the bone tunnels created in the distal clavicle through the medullary canal. The clavicle was reduced into an anatomical position and the coracoacromial ligament was secured and tied. Two additional drill holes were created to further secure the clavicle around the base of the coracoid

with nonabsorbable sutures. Finally, the delto-trapezial fascia was carefully repaired over the top of the clavicle. The arm was immobilized in a shoulder immobilizer for three weeks. Active-assisted rehabilitation of the shoulder was initiated a week after the surgery. At the 5th postoperative week, full activity without restriction was permitted. Shoulder stretching exercises were initiated at the 8th postoperative week. Forced exercises were avoided until the 12th postoperative week. Radiographs of the shoulder showed significant coracoclavicular ossification with reduction of the coracoclavicular space after eighteen months (Fig. 2). Patient function was not assessed on any scale because of patient's preoperative general status. Two years after surgery she had no pain in the

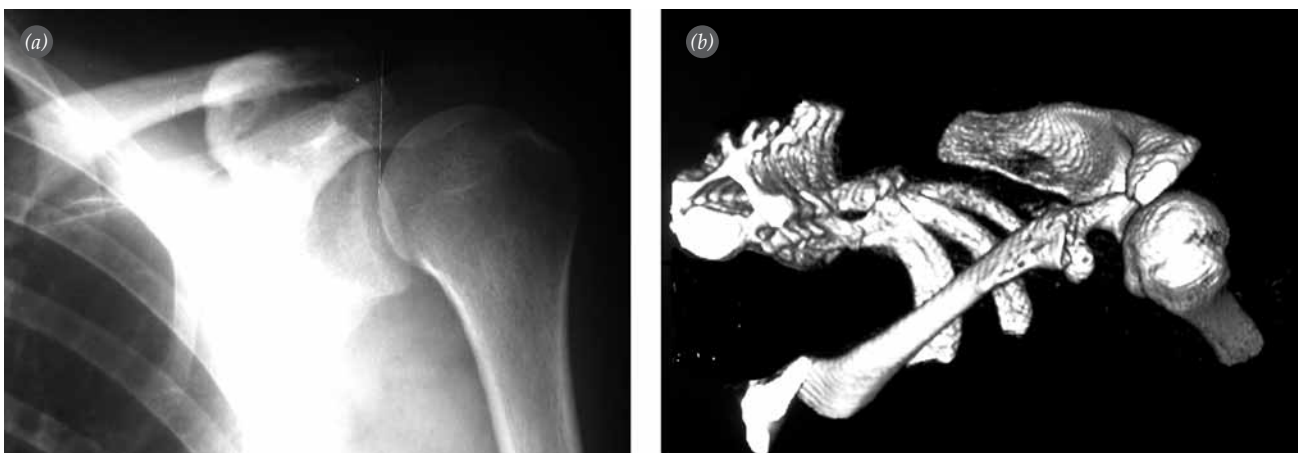

Fig 2. Postoperative 18th month (a) AP radiography and (b) 3D CT image.

shoulder and was able to return to daily activities without complaint.

Discussion

Subcoracoid dislocation of the acromioclavicular joint is extremely uncommon. The mechanism of injury is thought to be severe hyperabduction and external rotation of the arm, combined with retraction of the scapula. In all reported cases of subcoracoid dislocations, the clavicle becomes lodged behind an intact conjoint tendon.^[4,8] With the exception of one patient with an acromial fracture, all patients reported by Torrens et al. had a painful mechanical block to abduction of the shoulder.^[5] In our case, a painful mechanical block was present at 90 degrees of abduction.

As these injuries are produced by high-energy trauma, other skeletal fractures, including those of the clavicle and upper ribs, can also be seen. Gerber and Rockwood, McPhee, and Patterson reported transient neurologic or vascular lesions.^[4,8,9] McPhee and Patterson hypothesized that transient neurological lesions were not directly related to the dislocation but rather to the contusion of the shoulder.^[8,9] Gerber and Rockwood reported a patient in which paresthesia was only elicited by movement of the shoulder.^[4] This pathologic condition was thought to be caused by the clavicle displacement due to neurologic irritation. In our patient, there were no neurologic or vascular lesions.

In the literature, all patients were treated with surgery.^[4,5] Surgical techniques usually focus on coracoclavicular ligament augmentation because it has been shown to be the primary stabilizer of the acromioclavicular joint. Gerber and Rockwood reported the extra-articular technique, incorporating a special coracoclavicular lag screw, ligament repair, and imbrication of the deltotrapezial fascia over the top of the clavicle.^[4] Torrens et al. stabilized the clavicle with a coracoclavicular screw as described by Bosworth.^[5] In our patient, we transferred the coracoacromial ligament to the outer clavicle, as described by Weaver and Dunn.^[10] The distal clavicle was resected to prevent the development of secondary degenerative changes because of the injury to the joint soft tissue and intra-articular disk.

Coracoclavicular ossification can be observed regardless of the type of acromioclavicular injury. Although some authors proposed that ossification

was the result of operative treatment, most showed that ossification occurred regardless of the treatment method of the lesion.^[11] As in the literature, coracoclavicular ossification developed after surgery in our case. However, the patient had no complaints and a full-functional shoulder was achieved. These findings show that further information concerning these pathologic conditions is needed.

In conclusion, subcoracoid dislocation of the clavicle is a rare injury that is usually associated with high-energy trauma. Although diagnosis is difficult to make without radiographic and CT findings, clinicians should consider this injury in the differential diagnosis, located in the shoulder girdle.

Conflicts of Interest: No conflicts declared.

References

1. Tossy JD, Mead NC, Sigmond HM. Acromioclavicular separations: useful and practical classification for treatment. *Clin Orthop Relat Res* 1963;(28):111-9.
2. Williams GR, Nguyen VD, Rockwood CA Jr. Classification and radiographic analysis of acromioclavicular dislocations. *Appl Radiol* 1989;18:29-34.
3. Bishop JY, Kaeding C. Treatment of the acute traumatic acromioclavicular separation. *Sports Med Arthrosc Rev* 2006;14:237-45.
4. Gerber C, Rockwood CA Jr. Subcoracoid dislocation of the lateral end of the clavicle. A report of three cases. *J Bone Joint Surg Am* 1987;69:924-7.
5. Torrens C, Mestre C, Pérez P, Marin M. Subcoracoid dislocation of the distal end of the clavicle. A case report. *Clin Orthop Relat Res* 1998;(348):121-3.
6. Dimakopoulos P, Panagopoulos A, Syggelos SA, Panagiotopoulos E, Lambiris E. Double-loop suture repair for acute acromioclavicular joint disruption. *Am J Sports Med* 2006;34:1112-9.
7. Tienen TG, Oyen JF, Eggen PJ. A modified technique of reconstruction for complete acromioclavicular dislocation: a prospective study. *Am J Sports Med* 2003;31:655-9.
8. McPhee IB. Inferior dislocation of the outer end of the clavicle. *J Trauma* 1980;20:709-10.
9. Patterson WR. Inferior dislocation of the distal end of the clavicle. A case report. *J Bone Joint Surg Am* 1967;49:1184-6.
10. Weaver JK, Dunn HK. Treatment of acromioclavicular injuries, especially complete acromioclavicular separation. *J Bone Joint Surg Am* 1972;54:1187-94.
11. Rockwood CR Jr, Williams GR Jr, Young DC. Disorders of the acromioclavicular joint. In: Rockwood CR Jr, Matsen FA III, editors. *The Shoulder*. 2nd ed. Philadelphia: Saunders; 1998. p. 536-7.

Copyright of Acta Orthopaedica Traumatologica Turcica is the property of Turk Ortopedi ve Travmatoloji Dernegi and its content may not be copied or emailed to multiple sites or posted to a listserv without the copyright holder's express written permission. However, users may print, download, or email articles for individual use.