



Is coracoclavicular ossification a complication or a good prognostic factor after surgical treatment of acromioclavicular joint injury?



Rodi Ertogrul, MD^a, Koray Sahin, MD^b, Haluk Celik, MD^c, Mehmet Kapicioglu, MD^d, Ali Ersen, MD^e, Kerem Bilsel, MD^{d,*}

^aSisli Hamidiye Etfal Training and Research Hospital, Orthopaedics Department, Istanbul, Turkey

^bMus State Hospital, Department of Orthopaedics and Traumatology, Muş, Turkey

^cHisar Intercontinental Private Hospital, Department of Orthopaedics and Traumatology, Istanbul, Turkey

^dBezmialem Vakif University, Department of Orthopaedics and Traumatology, Istanbul, Turkey

^eIstanbul University, Istanbul Medical School, Department of Orthopaedics and Traumatology, Istanbul, Turkey

ARTICLE INFO

Keywords:

Acromioclavicular joint dislocation
Arthroscopic fixation
Heterotopic ossification
Coracoclavicular ligament surgery
Shoulder injuries
AC joint

Level of evidence: Level IV; Case Series;
Treatment Study

Background: The purpose of this study was to investigate whether heterotopic ossification (HO) in the coracoclavicular (CC) space after surgical treatment of acromioclavicular joint (ACJ) injury is a complication or a sign of good prognosis.

Methods: Fifty-nine consecutive patients who underwent CC reconstruction with or without augmentation of the ACJ for acute ACJ injuries were analyzed. Postoperative American Shoulder and Elbow Surgeons (ASES) score, Constant score (CS), subjective shoulder value (SSV), and visual analog scale (VAS) results were evaluated. For radiological evaluation, HO was evaluated, and CC distances were measured.

Results: Fifty-one patients (11 women and 40 men; mean age, 36 years [range, 17–68 years]) were evaluated after a mean follow-up of 3 years (range, 2–8 years). The mean ASES score at the follow-up was 82.73 (range, 51.6–100), mean CS was 85 (range, 50–100), mean SSV was 80 (range, 40–100), and mean VAS was 1.9 (range, 0–5). It was observed that the clinical outcomes (ASES, CS, SSV, VAS) of patients who developed ossification in the CC space were better than those who did not although it was not statistically significant. No statistically significant differences were found in the clinical outcomes (ASES, CS, SSV, VAS) between patients who underwent CC reconstruction without augmentation of the ACJ and those who were combined ($P > .05$).

Conclusion: HO in the CC space is a common finding following AC joint fixation injury. We suggest that HO is not a complication and might possibly have positive effects on clinical outcomes.

© 2022 The Authors. Published by Elsevier Inc. on behalf of American Shoulder and Elbow Surgeons. This is an open access article under the CC BY-NC-ND license (<http://creativecommons.org/licenses/by-nc-nd/4.0/>).

Acromioclavicular (AC) joint injuries account for approximately 9% of shoulder girdle injuries.¹⁶ These injuries mostly occur after direct trauma, caused by a fall or blow while the arm is in the adduction position.¹⁶ These injuries are mostly seen in 20- to 30-year-old male patients who engage in high-contact sports.^{4,5,8,16,21,26} According to Rockwood, these injuries may be classified into 6 types.²³ In the current approach, types I and II injuries are treated conservatively, while types IV, V, and VI are treated surgically. No consensus on the treatment of type III injuries exists; nonoperative treatment is recommended as initial therapy,

but acute reconstruction may also be considered on a case-by-case basis.^{8,27}

More than 150 different surgical techniques have been described in previous studies for the treatment of AC joint injury.⁴ The common purpose of these surgical procedures is to reduce the joint and reconstruct the injured ligaments.^{14,16} All of these surgical procedures have consequences and complications. Coracoid and clavicle fracture, hardware irritation, vessel and nerve injury, infection, and redislocation are some of these complications. In some studies, the complication rate is up to 44%.²⁴ Coracoclavicular (CC) ligament ossification, which was previously considered a complication and later a phenomenon, has not been clearly defined as to whether it is a complication or a sign of good prognosis.^{2,3}

The objective of the present study was to evaluate the possible effect of heterotopic ossification on clinical outcomes following after surgical treatment of AC joint injury. Since ossification in the

This study was approved by Bezmialem Vakif University (identification no. E-45446446-010.99-17064).

*Corresponding author: Kerem Bilsel, MD, Bezmialem Vakif Universitesi Tip Fakultesi Hastanesi, vatan street, Fatih, istanbul 34093, Turkey.

E-mail address: kbilsel@gmail.com (K. Bilsel).

<https://doi.org/10.1016/j.jseint.2022.04.009>

2666-6383/© 2022 The Authors. Published by Elsevier Inc. on behalf of American Shoulder and Elbow Surgeons. This is an open access article under the CC BY-NC-ND license (<http://creativecommons.org/licenses/by-nc-nd/4.0/>).

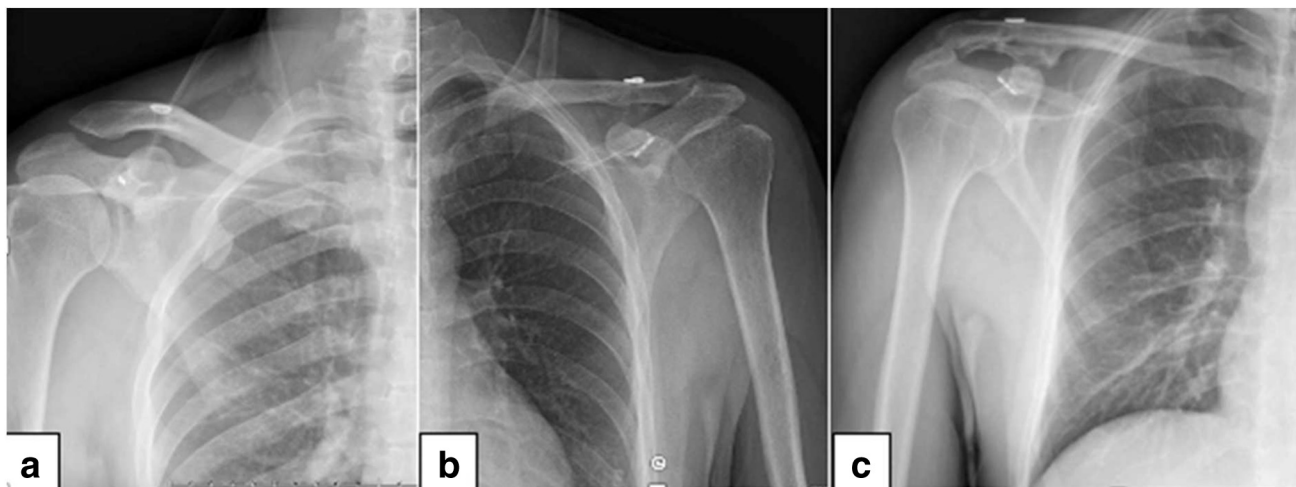


Figure 1 (a) Minimal bone formation around the CC space (mild grade). (b) More than 50% of ossification around the CC space without bridging (moderate grade). (c) Bone formation around the CC ligament with bridging (severe grade). CC, coracoclavicular.

CC space after AC joint reconstruction is seen as a complication, few studies in the literature showing the effect of ossification in the CC space on clinical outcomes can be found. Our hypothesis was that CC space ossification was not a complication but a sign of good prognosis. We also evaluated the effect of CC reconstruction with and without augmentation of the AC joint on clinical outcomes.

Materials and methods

Fifty-nine consecutive patients with a diagnosis of acute AC joint separation who underwent surgery between December 2013 and February 2020 at 3 different institutions with 3 different senior surgeons using the 2 different all-arthroscopic surgical techniques (CC reconstruction with and without AC joint augmentation) were included in the study. Institutional review board approval was granted before study initiation from the relevant department (identification no. E-45446446-010.99-17064).

All procedures were performed under general anesthesia with patients positioned in beach-chair position. CC fixation was performed arthroscopically in all patients using AC TightRope (Arthrex, Naples, FL, USA) or Loop Double Endobutton (Smith & Nephew, London, United Kingdom). In patients with AC ligament repair, mini-incisions were made and #5 nonadsorbable braided Ethibond sutures were passed through the tunnels opened from the clavicle and acromion, and horizontal stabilization was established.

Patients who were acutely treated after injury with a minimum of 2-year follow-up duration were included in the study. All patients were diagnosed with Rockwood and Green type III or V injury. Indications for operative treatment included type III injury in manual/overhead workers or athletes and type V injuries. Time to surgical treatment in all patients was less than 3 weeks. Patients who were younger than 16 years at the time of surgery, who underwent revision surgery, who had preoperative clavicle fractures, and who had less than 2-year follow-up were excluded from the study.

In 48 patients, the cause of injury was direct trauma to the shoulder. Eleven patients had undergone indirect trauma during a car accident. Injury mechanisms were sports injury in 21 patients, falling off a bike in 16 patients, falling down from stairs in 8 patients, and falling from standing position in 3 patients.

For the diagnosis of AC joint separation, true anteroposterior and Zanca views of the affected shoulder and bilateral

anteroposterior views were used. The CC distance was measured between the coracoid process and the inferior cortex of the clavicle on the anteroposterior stress views.

Final clinical and radiological evaluations were performed by a single examiner. Clinical outcomes measures included the American Shoulder and Elbow Surgeons (ASES) Shoulder Score, Constant score (CS), Subjective Shoulder Value (SSV), and pain score based on the visual analog scale (VAS).

Postoperative radiological assessments were performed using standard shoulder anteroposterior radiographs. Radiological evaluations included ossification of the CC space, measurement of coracoclavicular distance, presence of AC joint arthrosis, recurrent dislocation, and osteolysis.

Ossification between the clavicle and the coracoid was divided into the following four grades: (1) none, (2) mild, (3) moderate, and (4) severe. Bone formation around the CC ligament without bridging was graded as mild, and that with bridging was graded as severe (Fig. 1). Two study groups were formed according to radiological findings of ossification (with and without ossification), and these two groups were compared in terms of clinical outcomes. Another comparison of clinical outcomes was performed between two groups of different surgical techniques (isolated CC fixation vs. combined CC and AC fixation).

Statistical analyses were performed using the Number Cruncher Statistical System Statistical Software (Kaysville, UT, USA). Descriptive statistical methods included mean, median, and range (minimum and maximum). Comparison of study groups was performed using the Shapiro-Wilk and Mann-Whitney U tests for parametric and nonparametric variables, respectively. The level of significance was set at $P = .05$ for all analyses.

Postoperative management

Immobilization with a simple hanging sling (shoulder immobilizer; DJO, Carlsbad, CA, USA) was carried out for 4 weeks. Immediate elbow, wrist, and hand motions were initiated postoperatively. At the fourth week, shoulder pendulum exercises were initiated and performed for 2 weeks. Patients started an active range of motion exercises in the seventh postoperative week. Muscle strengthening exercises were initiated at the 12th week postoperatively.

Table 1
Pain and functional outcomes at final follow-up visit.

	Mean + SD	Median (Min-Max)
ASES	82.73 ± 15.64	90 (51.6-100)
CS	85.0 ± 16.0	90 (50-100)
SSV	80.0 ± 21.0	90 (40-100)
VAS	1.9 ± 1.8	1.5 (0-5)

CS, Constant score; Max, maximum; Min, minimum; SD, standard deviation; SSV, Subjective Shoulder Value; VAS, visual analog scale.

Results

Of 59 patients, 51 (40 men, 11 women) were available for the long-term follow-up (median follow-up duration, 3 years; range, 1-8 years) and were reevaluated both clinically and with plain radiographs. Five patients could not be contacted, and 3 patients refused to participate in the follow-up. The lost to follow-up ratio was 13.5% (8 of 59).

The mean age of the patients was 36 years (range, 17-68 days). The mean time to surgery after trauma was 6.4 days (range, 2-20 days). The dominant side was affected in 34 patients and nondominant shoulder in 17 patients. Forty-two patients suffered from type V and 9 from type III injuries according to the Rockwood classification.

The mean ASES score result at the final follow-up was 82.7 (range, 51.6-100), mean CS result was 85.0 (range, 50-100), mean SSV result was 80.0 (range, 40-100), and mean VAS result was 1.9 (range, 0-5) as shown in Table 1.

Ossification in the CC space was observed in 15 of 42 patients (35.7%) with type V AC joint dislocation and in 4 of 9 patients (44.4%) with type III AC joint dislocation. Overall, 19 (37.3%) patients showed ossifications between the clavicle and coracoid. There were 4 mild, 13 moderate, and 2 severe ossifications according to the radiological assessment. Outcomes of patients who developed ossification in the CC range were compared with outcomes of those who did not (Table 2).

Of the 19 patients who developed heterotopic ossification, 16 were male and 3 were female patients. Injury mechanisms of patients with heterotopic ossification were car accident in 3 patients, sports injury in 10 patients, falling off a bike in 2 patients, and falling down from stairs in 4 patients.

No statistically significant differences in terms of ASES, CS, SSV, and pain scores between patients with and without ossification were observed ($P > .5$). Even though statistically insignificant, higher ASES scores, CS, and SSV scores and lower pain scores were remarkable in patients with ossification (Figs. 2–4, respectively).

The mean preoperative CC distance was 17.8 ± 4.1 mm. Postoperatively, the mean CC distance was 6.7 ± 2.0 mm on the first postoperative day and 8.8 ± 2.5 mm at the final follow-up evaluation (Table 3).

CC distance measurements were compared between patients with and without ossification. The mean CC distance of patients with ossification was shorter than in those who did not. However, there was no statistically significant difference between the 2 study groups ($P > .05$) as shown in Table 4.

While 27 patients (52.9%) underwent isolated CC fixation, combined AC + CC fixation was performed in 24 patients (47.1%). Clinical outcomes were compared between patients with isolated CC ligament repair and combined AC + CC ligament repair. No statistically significant difference in clinical outcomes (ASES, CS, SSV, VAS) between these two groups was found ($P > .05$) as shown in Table 5.

While heterotopic ossification was observed in 11 of 27 patients (40.7%) who underwent isolated CC fixation, there were

heterotopic ossification in 8 of 24 patients (33.3%) who underwent combined AC and CC stabilization.

Additionally, arthrosis of the AC joint was observed in 5 patients, and distal clavicular osteolysis was observed in 2 patients. One patient developed frozen shoulder and was treated with arthroscopic release. Superficial wound infection was observed in 1 patient who was successfully treated with oral antibiotic therapy. In 2 patients, intraoperative coracoid fracture occurred. The first patient responded well to conservative management, and union was achieved. However, conservative management failed for the second patient, and excision of the coracoid with tenodesis of the conjoint tendon to the subscapularis was performed.

Discussion

The most important finding of this study indicates that clinical outcomes of patients with ossification in the CC space were better than outcomes of those without ossification although the results were not statistically significant. The results support the hypothesis that heterotopic ossification in the CC space after surgical treatment of AC joint injury might be a sign of good prognosis.

Although many surgical techniques have been described in AC joint dislocation, the essential is adequate reduction of the AC joint and reconstruction of the injured ligaments. Arthroscopic isolated CC fixation and combined CC fixation with AC augmentation are the most frequently performed surgical procedures in recent years.¹⁹ In our study population, both techniques were used for treatment of patients.

Previous studies reporting that CC fixation should be performed together with AC augmentation as it provides stability in the horizontal plane have been published.^{1,13,17} Jordan et al¹⁰ reported no significant differences in functional outcomes, complication, and revision rates between isolated CC fixation and with additional AC fixation were detected. However, reports that favored addition of an AC fixation due to superior clinical outcomes have also been published.²⁵ In our study, no statistically significant difference was observed in terms of clinical outcomes (ASES, CS, SSV, VAS) between the two surgical techniques.

Heterotopic ossification is bone tissue formation occurring in an undesirable location in the body. The specific pathophysiology of heterotopic ossification still remains unclear. Its etiology is multifactorial, and the pathomechanism is thought to be caused by postsurgical bone marrow leakage and subsequent inappropriate differentiation of mesenchymal cells and fibroblasts into bone-forming cells due to local factors, such as soft-tissue edema, tissue hypoxia, and unknown systemic factors.^{7,9,11,20}

Heterotopic ossification in the CC space is a common finding after surgical treatment of AC joint injuries, regardless of the treatment modality, and has been traditionally considered a complication according to previous knowledge.^{6,9,22,28} However, it is unknown whether heterotopic ossification in the CC space is due to injured ligaments or opened bone tunnels. Assessment of heterotopic ossification in techniques without bone tunneling may be helpful for further understanding of this issue.

Motta et al¹⁸ reported that ossification in the CC space was related to the postoperative immobilization time and that presence of ossification in the CC space provided better AC joint stabilization and had a positive effect on clinical outcomes. These findings were previously noted by Larsen et al,¹² who stated that ossification was more common in patients with excellent results. Scheibel et al²² showed that the CC distance was significantly shorter in patients who developed ossification in the CC space than in patients who did not. They also found that SSV, CS, Taft score, and Acromioclavicular Joint Instability scores improved as the amount of ossification increased, but only the Acromioclavicular Joint Instability score

Table II
A comparison of clinical outcomes between patients with and without ossification.

	Ossification				P value
	Negative		Positive		
	Mean ± SD	Median (Min-Max)	Mean ± SD	Median (Min-Max)	
ASES	79.65 ± 15.82	80 (51.6-100)	87.93 ± 14.23	93.3 (54.9-100)	.058
CS	81.56 ± 17.02	90 (50-100)	89.53 ± 14.06	95 (55-100)	.150
SSV	76.41 ± 21.56	82.5 (40-100)	87.11 ± 17.27	95 (40-100)	.099
VAS	2.23 ± 1.76	3 (0-5)	1.26 ± 1.76	0 (0-5)	.071

ASES, American Shoulder and Elbow Surgeons; CS, Constant score; Max, maximum; Min, minimum; SD, standard deviation; SSV, Subjective Shoulder Value; VAS, visual analog scale.

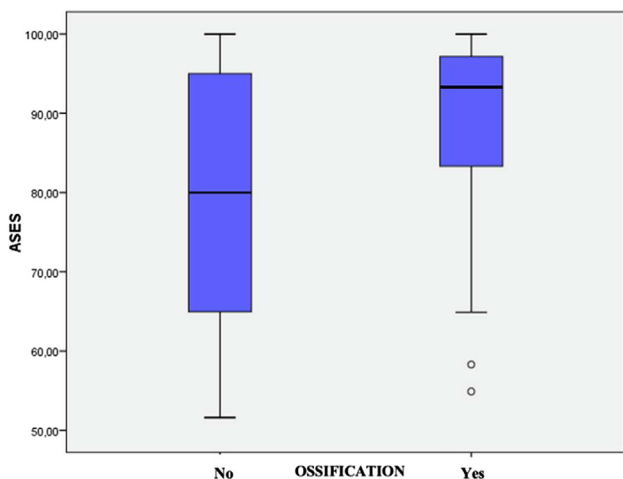


Figure 2 Range of the American Shoulder and Elbow Surgeons (ASES) Shoulder Score according to ossification status.

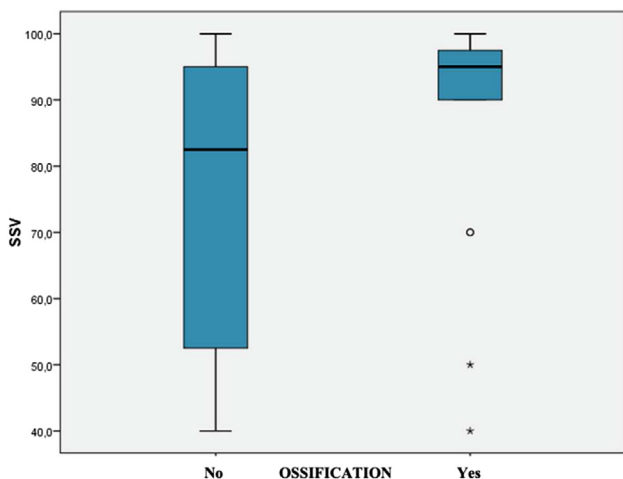


Figure 3 Range of the Subjective Shoulder Value (SSV) score according to ossification status.

improvement was statistically significant. Another study by Masionis et al¹⁵ reported that patients with ossification had better Simple Shoulder Test scores than those who did not.

Few studies in current literature showing the effect of CC space ossification after treatment of AC joint injury on clinical outcomes are available. Some authors have considered ossification in the CC space as a phenomenon rather than a complication. They state that clinical outcomes of patients who developed ossification in the CC

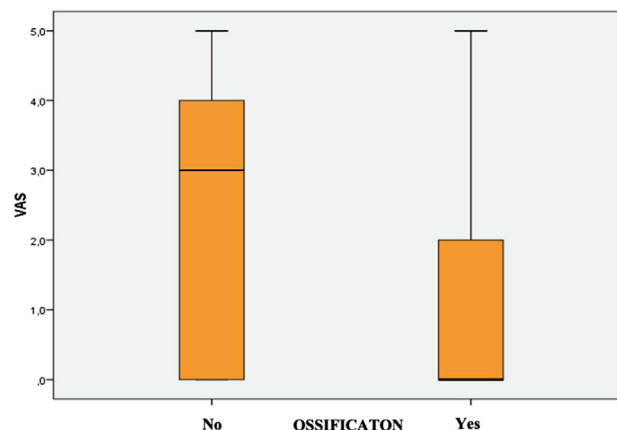


Figure 4 Range of the visual analog scale (VAS) score according to ossification status.

Table III
Coracoclavicular distance (CCD) measurements.

CCD	Mean + SD	Median (Min-Max)
Preoperative	17.8 ± 4.1	17.5 (8-29)
Postoperative day	6.7 ± 2.0	6.4 (1.6-11.8)
Last control	8.8 ± 2.5	8.8 (4.1-13.9)

CCD, coracoclavicular distance; Max, maximum; Min, minimum; SD, standard deviation.

space were better than those who did not. Although clinical outcomes of patients with ossification in the CC space were better than those of the patients without ossification in our study, the difference was insignificant. Another finding of our study demonstrated that ossification also caused an improvement in radiological outcomes and that postoperative CC distance was shorter in patients with ossification. However, this difference was also not statistically significant. In addition to this finding, other findings from our study suggest that AC augmentation with CC fixation did not lead to a significant improvement in clinical outcomes. Findings of our study support the idea that heterotopic ossification is not a complication, does not require additional intervention, does not cause patient dissatisfaction, and only appears as a finding that the surgeon evaluates on the radiograph during the patient's routine examination.

There are some limitations to our study which should be discussed. The retrospective nature of our study is the first limitation that decreases the level of evidence. Second, procedures were performed in 3 different centers by 3 different surgeons, which may have influenced outcomes due to difference of technique and expertise among the surgeons. Third, all clinical and radiological assessments were performed by a single author which might have caused an evaluation bias. Another limitation is the relatively short

Table IV
Comparison of CC distance measurements between patients with and without ossification.

CCD	Ossification				P value
	Negative		Positive		
	Mean ± SD	Median (Min-Max)	Mean ± SD	Median (Min-Max)	
Final control	9.28 ± 2.49	9.05(48-13.9)	8.05 ± 2.31	7.5(4.1-12.5)	.126

CC, coracoclavicular; CCD, coracoclavicular distance; Max, maximum; Min, minimum; SD, standard deviation.

Table V
Comparison of clinical outcomes between surgical techniques.

	Surgical technique: CC reconstruction with and without AC joint augmentation				P value
	CC		CC + AC		
	Mean ± SD	Median (Min-Max)	Mean ± SD	Median (Min-Max)	
ASES	81.00 ± 15.35	80 (52-100)	84.67 ± 16.05	93.3 (51.6-100.0)	.409
CS	81.33 ± 17.67	90 (50-100)	88.12 ± 14.12	94.0 (58.0-100.0)	.163
SSV	76.29 ± 21.19	90 (40-100)	85.00 ± 19.22	95.0 (40.0-100.0)	.096
VAS	1.92 ± 1.59	2 (0-4)	1.78 ± 2.06	1.0 (0.0-5.0)	.710

ASES, American Shoulder and Elbow Surgeons; CS, Constant score; Max, maximum; Min, minimum; SD, standard deviation; SSV, Subjective Shoulder Value; VAS, visual analog scale.

follow-up duration. This study has a considerable population size compared to previous literature. Therefore, we believe that our findings make a valuable contribution to current knowledge. Nonetheless, it is quite likely that our population size is insufficient to show some significant clinical benefit of heterotopic in coracoclavicular space and might be a possible reason for insignificant differences. Consequently, a larger population is needed to draw such a conclusion.

Conclusion

Heterotopic ossification after surgical treatment of AC joint injuries is a common finding. Our findings suggest that this ossification is not a complication. Results of our studies showed that ossification might improve clinical and radiological outcomes; however, further research studies are needed to draw such a conclusion.

Disclaimers:

Funding: No funding was disclosed by the authors.

Conflicts of interest: The authors, their immediate families, and any research foundation with which they are affiliated have not received any financial payments or other benefits from any commercial entity related to the subject of this article.

Patient consent: Obtained.

References

- Aliberti GM, Kraeutler MJ, Trojan JD, Mulcahey MK. Horizontal Instability of the acromioclavicular joint: a systematic review. *Am J Sports Med* 2020;48:504-10. <https://doi.org/10.1177/0363546519831013>.
- Altıntaş B, Yıldız F, Uzer G, Kapıcıoğlu M, Bilsel K. All-arthroscopic guideless single suture-button fixation of acute acromioclavicular joint dislocation: a description of the technique and early treatment results. *Clin Shoulder Elbow* 2017;20:59-67. <https://doi.org/10.5397/cise.2017.20.2.59>.
- Arrigoni P, Brady PC, Zottarelli L, Barth J, Narbona P, Huberty D, et al. Associated lesions requiring additional surgical treatment in grade 3 acromioclavicular joint dislocations. *Arthroscopy* 2014;30:6-10. <https://doi.org/10.1016/j.arthro.2013.10.006>.
- Beitzel K, Cote MP, Apostolakis J, Solovyova O, Judson CH, Ziegler CG, et al. Current concepts in the treatment of acromioclavicular joint dislocations. *Arthroscopy* 2013;29:387-97. <https://doi.org/10.1016/j.arthro.2012.11.023>.
- Boffano M, Mortera S, Wafa H, Piana R. The surgical treatment of acromioclavicular joint injuries. *EFORT Open Rev* 2017;2:432-7. <https://doi.org/10.1302/2058-5241.2.160085>.
- Cerciello S, Berthold DP, Uyeki C, Kia C, Cote MP, Imhoff AB, et al. Anatomic coracoclavicular ligament reconstruction (ACCR) using free tendon allograft is effective for chronic acromioclavicular joint injuries at mid-term follow-up. *Knee Surg Sports Traumatol Arthrosc* 2021;29:2096-102. <https://doi.org/10.1007/s00167-020-06123-0>.
- Ekelund A, Brosjö O, Nilsson OS. Experimental induction of heterotopic bone. *Clin Orthop Relat Res* 1991;263:102-12.
- Frank RM, Cotter EJ, Leroux TS, Romeo AA. Acromioclavicular joint injuries: evidence-based treatment. *J Am Acad Orthop Surg* 2019;27:775-88. <https://doi.org/10.5435/JAAOS-D-17-00105>.
- Jobmann S, Buckup J, Colcuc C, Roessler PP, Zimmermann E, Schüttler KF, et al. Anatomic ligament consolidation of the superior acromioclavicular ligament and the coracoclavicular ligament complex after acute arthroscopically assisted double coracoclavicular bundle stabilization. *Knee Surg Sports Traumatol Arthrosc* 2019;27:3168-79. <https://doi.org/10.1007/s00167-017-4717-1>.
- Jordan RW, Malik S, Bentick K, Saithna A. Acromioclavicular joint augmentation at the time of coracoclavicular ligament reconstruction fails to improve functional outcomes despite significantly improved horizontal stability. *Knee Surg Sports Traumatol Arthrosc* 2019;27:3747-63. <https://doi.org/10.1007/s00167-018-5152-7>.
- Kaplan FS, Hahn GV, Zasloff MA. Heterotopic ossification: two rare forms and what they can teach us. *J Am Acad Orthop Surg* 1994;2:288-96.
- Larsen E, Bjerg-Nielsen A, Christensen P. Conservative or surgical treatment of acromioclavicular dislocation. a prospective randomized study. *J Bone Joint Surg Am* 1986;68:552-5.
- Li H, Wang C, Wang J, Wu K, Hang D. Restoration of horizontal stability in complete acromioclavicular joint separations: surgical technique and preliminary results. *Eur J Med Res* 2013;18:1-8. <https://doi.org/10.1186/2047-783X-18-42>.
- MacDonald PB, Lapointe P. Acromioclavicular and sternoclavicular joint injuries. *Orthop Clin North Am* 2008;39:535-45. <https://doi.org/10.1016/j.jocl.2008.05.003>.
- Masionis Povilas, Bobina Rokas, Ryliskis Sigitas. The relationship between the clinical and radiological findings and the outcomes of early surgical treatment after Tossy type III acromioclavicular joint dislocation. *Cureus* 2020;12:6681. <https://doi.org/10.7759/2Fcurious.6681>.
- Mazzocca AD, Arciero RA, Bicos J. Evaluation and treatment of acromioclavicular joint injuries. *Am J Sports Med* 2007;35:316-29. <https://doi.org/10.1177/0363546506298022>.
- Minkus M, Hann C, Scheibel M, Kraus N. Quantification of dynamic posterior translation in modified bilateral Alexander views and correlation with clinical and radiological parameters in patients with acute acromioclavicular joint instability. *Arch Orthop Trauma Surg* 2017;137:845-52. <https://doi.org/10.1007/s00402-017-2691-1>.
- Motta P, Bruno L, Maderni A, Tosco P, Mariotti U. Acromioclavicular motion after surgical reconstruction. *Knee Surg Sports Traumatol Arthrosc* 2012;20:1012-8. <https://doi.org/10.1007/s00167-011-1627-5>.
- Nolte PC, Lacheta L, Dekker TJ, Elrick BP, Millett PJ. Optimal management of acromioclavicular dislocation: current Perspectives. *Orthop Res Rev* 2020;12:27-44. <https://doi.org/10.2147/2FORR.S218991>.
- Oc Y, Ozcan MS, Sezer HB, Kilinc BE, Eren OT. Nontraumatic myositis ossificans of hip: a case presentation. *Case Rep Orthop* 2016;2016:1982656. <https://doi.org/10.1155/2016/1982656>.

21. Pallis M, Cameron KL, Svoboda SJ, Owens BD. Epidemiology of acromioclavicular joint injury in young athletes. *Am J Sports Med* 2012;40:2072-7. <https://doi.org/10.1177/2F0363546512450162>.
22. Scheibel M, Droschel S, Gerhardt C, Kraus N. Arthroscopically assisted stabilization of acute high-grade acromioclavicular joint separations. *Am J Sports Med* 2011;39:1507-16. <https://doi.org/10.1177/2F0363546511399379>.
23. Schneider MM, Balke M, Koenen P, Fröhlich M, Wafaisade A, Bouillon B, et al. Inter- and intraobserver reliability of the Rockwood classification in acute acromioclavicular joint dislocations. *Knee Surg Sports Traumatol Arthrosc* 2016;24:2192-6. <https://doi.org/10.1007/s00167-014-3436-0>.
24. Shin SJ, Kim NK. Complications after arthroscopic coracoclavicular reconstruction using a single adjustable-loop-length suspensory fixation device in acute acromioclavicular joint dislocation. *Arthroscopy* 2015;31:816-24. <https://doi.org/10.1016/j.arthro.2014.11.013>.
25. Sircana G, Saccomanno MF, Mocini F, Campana V, Messinese P, Monteleone A, et al. Anatomic reconstruction of the acromioclavicular joint provides the best functional outcomes in the treatment of chronic instability. *Knee Surg Sports Traumatol Arthrosc* 2021;29:2237-48. <https://doi.org/10.1007/s00167-020-06059-5>.
26. Sirin E, Aydin N, Mert Topkar O. Acromioclavicular joint injuries: diagnosis, classification and ligamentoplasty procedures. *EFORT Open Rev* 2018;3:426-33. <https://doi.org/10.1302/2058-5241.3.170027>.
27. Stucken C, Cohen SB. Management of acromioclavicular joint injuries. *Orthop Clin North Am* 2015;46:57-66. <https://doi.org/10.1016/j.jocl.2014.09.003>.
28. Tang G, Zhang Y, Liu Y, Qin X, Hu J, Li X. Comparison of surgical and conservative treatment of Rockwood type-III acromioclavicular dislocation: a meta-analysis. *Medicine* 2018;97. <https://doi.org/10.1097/2FMD.00000000000009690>.