

Foetal mediastinal cavernous haemangioma: A case report

Y. Yozgat, M. E. Avci, M. Karacelik, A.L. Avci, R. Ozdemir & T. Mese

To cite this article: Y. Yozgat, M. E. Avci, M. Karacelik, A.L. Avci, R. Ozdemir & T. Mese (2015) Foetal mediastinal cavernous haemangioma: A case report, Journal of Obstetrics and Gynaecology, 35:8, 852-853, DOI: [10.3109/01443615.2015.1017560](https://doi.org/10.3109/01443615.2015.1017560)

To link to this article: <https://doi.org/10.3109/01443615.2015.1017560>



Published online: 15 Jun 2015.



Submit your article to this journal [↗](#)



Article views: 111



View related articles [↗](#)



View Crossmark data [↗](#)

advanced research and management. We detected a 2*3*2-cm bilobulated well-circumscribed homogenous anterior mediastinal mass lesion. Foetal echocardiographic findings at the examination were normal. In addition, colour Doppler imaging revealed rich vascular formation and blood flow in the mediastinal mass. Weekly follow-up for the duration of the pregnancy revealed no cardiac compression signs by the mass, pericardial effusion or dysrhythmia (Figure 1 a,b). On the echocardiographic examination of the healthy 3500-g-weighting newborn who was born at term via repeat caesarean, we recognised 4*5*7-cm multilobulated well-circumscribed anterior mediastinal mass including cystic components near the right atrium (Figure 1 c,d). Thoracic magnetic resonance imaging (MRI) of the newborn reported an anterior mediastinal heterogenous mass. When the newborn was 10-day-old trans-thoracic fine-needle aspiration was performed. Histopathological examination revealed benign, cystic tissue components rich in vascular structures. Left posterolateral thoracotomy was performed when he was 3-week-old, which showed a solid and cystic mass originating from the ascending aorta and filling the entire anterior mediastinum. A fragile anterior mediastinal mass rich in vascular structure measuring 4*5*6 cm was surgically excised (Figure 1e). Pathological investigation of the specimen was

Foetal mediastinal cavernous haemangioma: A case report

Y. Yozgat¹, M. E. Avci², M. Karacelik³, A.L. Avci⁴, R. Ozdemir¹ & T. Mese¹

¹Department of Pediatric Cardiology, Dr. Behcet Uz Children's Hospital, İzmir, Turkey, ²Department of Perinatology, Aegean Training and Research Hospital, İzmir, Turkey, ³Department of Cardiovascular Surgery, Dr. Behcet Uz Children's Hospital, İzmir, Turkey, and ⁴Department of Anesthesiology, Gaziemir State Hospital, İzmir, Turkey

DOI: 10.3109/01443615.2015.1017560

Correspondence: M. E. Avci, Ege Doğumevi Eğitim ve Araştırma Hastanesi, 35120, Yenisehir, İzmir, Turkey. E-mail: eftar77@yahoo.com

Introduction

Benign vascular tumours are seldom found in the mediastinum and anterior localisation is more common than posterior (Karakaya et al. 2004). Haemangiomas are the most common type and are called capillary, cavernous or venous with respect to their size. Among them, cavernous type is least prevalent, largest and least circumscribed one and generally invades deep structures (Carrico et al. 2003). According to our knowledge no case of mediastinal cavernous haemangioma with images during foetal life exists in the literature. Here we report a case of anterior mediastinal mass that we followed since the 23 weeks' gestation by foetal and postnatal echocardiographic images and by paediatric intra-operative photograph and histopathological image of the surgical specimen.

Case report

A twenty-four-year-old, gravida 2, para1 woman with initial diagnosis of thoracic mass in her foetus was referred to our centre for

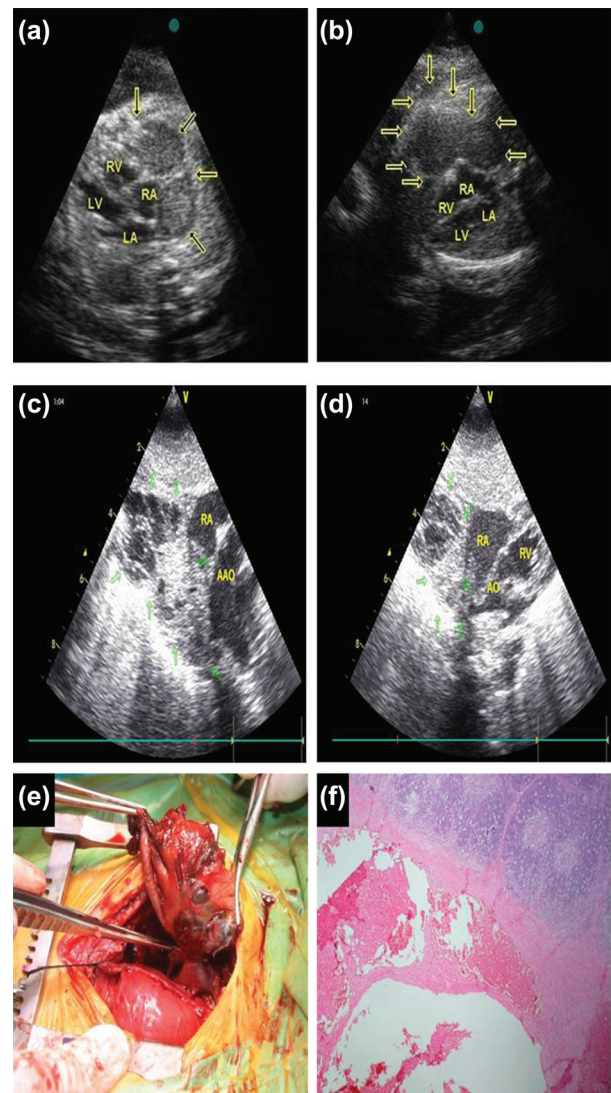


Figure 1. Foetal echocardiographic images of mediastinal mass at 23 (a) and 26 weeks' (b) gestation. Trans-thoracic image of mediastinal haemangioma at the neonatal period (c,d) image of mediastinal haemangioma at the operation (e) and histopathological image of cavernous haemangioma near the thymus tissue (Haematoxylin-eosin staining) (f). Short arrows point out the mass. LA, left atrium; LV, left ventricle; RA, right atrium; RV, right ventricle; Ao, aorta; AAO, ascending aorta.

reported as cavernous haemangioma (Figure 1f). The patient was discharged home on the fifth post-operative day after an uneventful recovery. He is 1 years old now, there is no mediastinal mass lesion on trans-thoracic echocardiography and ultrasonographic examination and he is healthy.

Discussion

Mediastinal haemangiomas constituting less than 0.5% of mediastinal tumours are benign uncommon vascular tumours and can be found anywhere in the mediastinum (Hammoumi et al. 2014). They are characterised by excessive proliferation of vascular endothelial cells. Ninety per cent of mediastinal haemangiomas are capillary or cavernous and sixty-eight per cent of mediastinal haemangiomas are localised in the anterior mediastinum; posterior mediastinal location is extremely rare (McAdams et al. 1994; Abe et al. 2001; Sabharwal and Strouse 2005). Haemangiomas are visualised as heterogeneous, circular or lobulated and well-circumscribed structures on ultrasonography and/or computed tomography (Davis et al. 1978; Cohen et al. 1987). Notwithstanding haemangiomas are seen as well-circumscribed, they have no real capsules. In our case, MRI and ultrasonographic imaging of the mediastinal mass visualised the mass as a lobulated and well-circumscribed cystic mass. Haemangiomas have specific findings on direct radiographic imaging known as 'phleboliths', which are calcified fields found in 10% of cases; these were not seen on imaging of our patient (McAdams et al. 1994; Abe et al. 2001). The differential diagnosis of anterior mediastinal mass in foetus includes teratomas and haemangiomas, primarily. Mediastinal teratoma represents a multilobulated mass with solid and cystic areas as well as the characteristic calcification spots and acoustic shadows by two-dimensional B-mode ultrasound (Uehara et al. 2013). In our case, colour Doppler echocardiography shows rich vascular formation and blood flow in the mass, which helps to differentiate haemangioma from teratomas.

Mediastinal masses detected during foetal life may remain asymptomatic till birth or may cause complications ranging from minimal pericardial effusion to massive hydrops. In our case, diagnosis of mediastinal mass was made at 23 weeks' gestation and remained asymptomatic till birth. Postnatally, 50% of the patients with mediastinal mass remain asymptomatic; in other half of the patients because of the pressure on the vital organs, symptoms such as cough and dyspnoea can be seen (Hanaoka et al. 2002). In our case, the patient has had no symptoms related to mediastinal mass effect in postnatal life.

Even if patients with mediastinal mass are asymptomatic, differential diagnosis from malignant vascular tumours such as haemangioendothelioma and haemangiopericytoma is indicated (Hanaoka et al. 2002; McAdams et al. 1994). While capillary haemangiomas can resolve spontaneously, cavernous haemangiomas do not regress spontaneously. Treatment options of haemangiomas are systemic steroid usage, sclerosant material injection, laser therapy, cryotherapy or a watch and wait approach. Because of potential of pressure effect on vital organs and furthermore there is no non-invasive method for differentiating benign from malignant vascular tumours, treatment of mediastinal masses by surgical resection is the proposed standard (Tan et al. 2003). We performed a surgical resection at postnatal 3rd week and at the end, pathological examination made the diagnosis of large cavernous haemangioma originated from ascending aorta. In summary, we must keep in mind benign vascular tumours whose prognosis is good, in case of foetal mediastinal masses. In addition that, as in our case, if the mediastinal mass is asymptomatic, it must be followed in foetal life and excised surgically in postnatal life for differential diagnosis and treatment.

Acknowledgements

Special thanks to Dr. Malik Ergin for preparation of histopathological image of surgical specimen.

Declaration of interest: The authors report no declaration of interest. The authors alone are responsible for the content and writing of the paper.

References

- Abe K, Akata S, Ohkubo Y, Park J, Kakizaki D, Simatani H, et al. 2001. Venous hemangioma of the mediastinum. *European Radiology* 11:73–75.
- Carricho A, Baptista MJ, Bastos P, Azevedo I. 2003. Mediastinal cavernous hemangioma in a newborn. *Portuguese Journal of Cardiology* 22:1421–1423.
- Cohen AJ, Sbaschnig RJ, Hochholzer L, Lough FC, Albus RA. 1987. Mediastinal hemangiomas. *Annals of Thoracic Surgery* 43:656–659.
- Davis JM, Mark GJ, Greene R. 1978. Benign blood vascular tumours of the mediastinum. Report of four cases and review of the literature. *Radiology* 126:581–587.
- Hammoumi MM, Sinaa M, Arsalane A, Queirachi FE, Kabiri H. 2014. Mediastinal Cystic Haemangiomas: A Two Cases Report and Review of the Literature. *Heart Lung and Circulation* 23:118–121.
- Hanaoka J, Inoue S, Fujino S, Kontani K, Sawai S, Tezuka N, et al. 2002. Mediastinal cavernous hemangioma in a child: report of a case. *Surgery Today* 32:985–988.
- Karakaya O, Akgul E, Binokay F, Aikimbaev K. 2004. Mediastinal hemanjiyom. Tanısal ve girişimsel radyoloji: Tıbbi Görüntüleme ve Girişimsel Radyoloji Derneği yayın organı 10:210–212.
- McAdams HP, Rosado-de-Christenson ML, Moran CA. 1994. Mediastinal hemangioma: radiographic and CT features in 14 patients. *Radiology* 193: 399–402.
- Sabharwal GK, Strouse PJ. 2005. Posterior mediastinal hemangioma. *Pediatric Radiology* 35:1263–1266.
- Tan C, Alphonso N, Anderson D, Austin C. 2003. Mediastinal haemangiomas in children. *European Journal of Cardiothoracic Surgery* 23:1065–1067.
- Uehara S, Hasegawa T, Okuyama H, Kawahara H, Kubota A, Osuga K, Morii E. 2013. Prenatally detected giant congenital hemangioma of the fetal neck. *Journal of Pediatric Surgery Case Reports* 1:29–31.