

Angioid streaks in a case of Camurati-Engelmann disease

*Betül Tuğcu, Taha Sezer, Ahmet Elbay,
Hakan Özdemir*

Camurati–Engelmann disease (CED) is a rare autosomal dominant disease with various phenotypic expressions. The hallmark of the disease is bilateral symmetric diaphyseal hyperostosis of the long bones with progressive involvement of the metaphysis. Ocular manifestations occur rarely and mainly result from bony overgrowth of the orbit and optic canal stenosis. We report a case of CED showing angioid streaks (ASs) in both fundi with no macular involvement and discuss the possible theories of the pathogenesis of AS in this disease.

Key words: Angioid streak, Camurati–Engelmann disease, connective tissue disorder, retina

Angioid streaks (ASs) are a rare ophthalmic condition resulting from pathological changes of the Bruch's membrane. AS appears as visible, irregular, crack-like dehiscences in Bruch's membrane with typical appearance of dark reddish-brown bands which irradiate from the optic disc. Most patients may remain asymptomatic till the development of choroidal rupture or subretinal neovascularization. Despite 50% of cases being idiopathic, AS has been shown in association with numerous systemic diseases, the most commonly seen are pseudoxanthoma elasticum, Paget's disease of bone, and sickle cell disease.^[1] In this case report, we report an unusual case presenting Camurati-Engelmann disease (CED) associated with AS. To the best of our knowledge, there has been no report of an association between AS with CED disease. We aimed to explore the possible underlying causes in the development of AS in CED disease and propose theories from the existing literature.

Case Report

A 28-year-old female had been diagnosed as having CED when she was 3-year-old. She had presented to the medical department initially for hearing difficulty and diagnosis of CED had been made during her childhood according to the characteristic clinical and radiological findings. Diagnosis had also been confirmed by molecular genetic testing with identification of transforming growth factor beta 1 (TGF- β 1) gene mutation. On general examination, she had kyphoscoliosis, contracture of both elbow joints, frontal bossing, mandibular enlargement, and bilateral

This is an open access article distributed under the terms of the Creative Commons Attribution-NonCommercial-ShareAlike 3.0 License, which allows others to remix, tweak, and build upon the work non-commercially, as long as the author is credited and the new creations are licensed under the identical terms.

For reprints contact: reprints@medknow.com

Cite this article as: Tugcu B, Sezer T, Elbay A, Özdemir H. Angioid streaks in a case of Camurati–Engelmann disease. *Indian J Ophthalmol* 2017;65:628-30.

Access this article online	
Quick Response Code:	Website: www.ijo.in
	DOI: 10.4103/ijo.ijo_910_16

Department of Ophthalmology, Faculty of Medicine, Bezmialem Vakıf University, Istanbul, Turkey

Correspondence to: Dr. Betül Tuğcu, Department of Ophthalmology, Faculty of Medicine, Bezmialem Vakıf University, 34093 Istanbul, Turkey. E-mail: betultugcu@gmail.com

Manuscript received: 22.11.16; Revision accepted: 11.05.17

sensorineural hearing loss [Fig. 1]. Irregular systemic corticotherapy had been used more than 6 years for her symptomatic treatment.

She had vision difficulty in both eyes for 2 years. Best-corrected visual acuity was 20/40 in the right eye with +0.50 dp of correction and 20/32 in the left eye with +0.75 dp of correction. Anterior segment examinations showed mild posterior capsular lenticular opacity in both eyes. Intraocular pressures were 26 and 25 mmHg right and left eye, respectively. Central corneal thickness was 655 μ in the right eye and 658 μ in the left eye. Fundus examination revealed AS radiating from the optic discs in both eyes. Typical peau d'orange appearance was seen in the temporal part of midperipheral retina [Fig. 2]. Optic discs were normal and C/D ratio was 0.3 in both eyes. Fluorescein angiography showed the linear hyperfluorescence streaks radiating from the optic disc in both eyes [Fig. 3]. Optic coherence tomography assessment was normal in both maculae [Fig. 4].

Discussion

CED has variable clinical course and findings and this might be attributable to the absence of correlation between

genotype and phenotype.^[2] Typical presenting manifestations of musculoskeletal involvement are hyperostosis of bones, proximal muscle weakness, waddling gait, and joint contractures.^[3] Neurological disorders occur through cranial base involvement leading to foraminal sclerosis resulting in neurovascular compromise and raised intracranial pressure.^[4] Facial palsy, hearing, and visual loss are the most common deficits, and orbital bone involvement may result in proptosis, optic nerve compression, epiphora, and subluxation of the globe.^[5,6] Our patient had a bilateral sensorineural hearing loss without abnormalities of orbit or optic nerve.

Prognosis of CED is poor owing to lack of definitive treatment. No disease-modifying treatment is available and corticosteroids are used predominantly for symptomatic therapy.^[3] Prolonged use of corticosteroids commonly induces posterior subcapsular cataract and glaucoma.^[7,8] Due to long-term use of steroid, our patient had also posterior subcapsular cataract and ocular hypertension without glaucoma.

In the present case, detailed fundus examination revealed bilateral AS. To the best of our knowledge, this is the first case presenting CED with AS. Histopathological findings of AS are degeneration of elastic lamina of Bruch's membrane

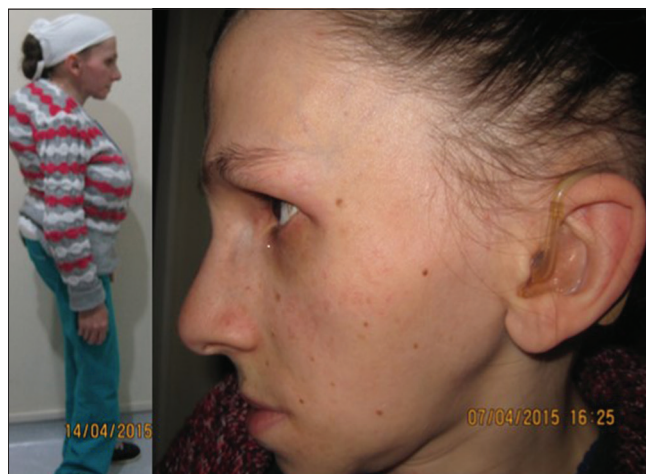

Figure 1: Patient showing kyphoscoliosis, frontal bossing, mandibular enlargement, and sensorineural hearing loss

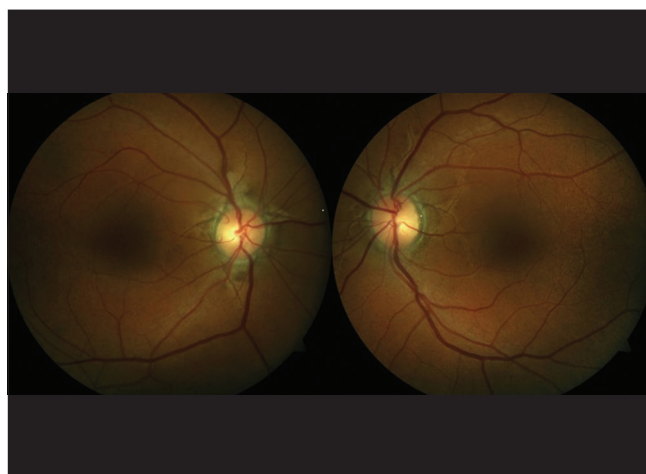


Figure 2: Fundus photograph showing typical angioid streaks

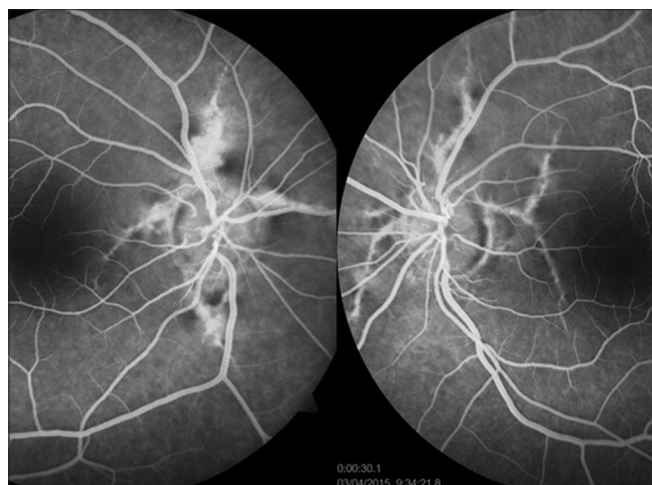

Figure 3: Fluorescein angiography showing linear hyperfluorescent streaks radiating from the optic disc in both eyes

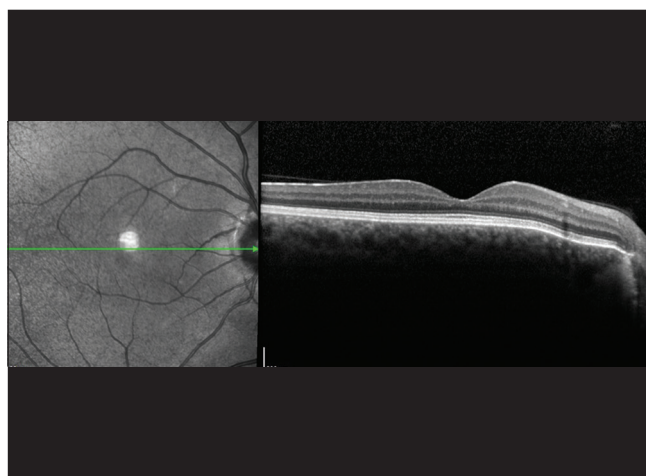


Figure 4: Normal optic coherence tomography assessment in macula of the right eye

with calcium deposition at break, absence of choriocapillaris, and thinning of retina pigment epithelium.^[1] In patients with CED, elasticity of Bruch's membrane might be altered due to the mutation of TGF- β 1 playing multiple roles in controlling proliferation, differentiation, and apoptosis of many cell types.^[9] Besides, the choroidal vasculature might be compromised by arterial wall thickening as part of a generalized vasculopathy seen in this disease.^[10]

Conclusion

In conclusion, we propose that the presence of AS in this patient is most likely related to predisposing factors concerned with CED rather than just coincident.

Declaration of patient consent

The authors certify that they have obtained all appropriate patient consent forms. In the form the patient(s) has/have given his/her/their consent for his/her/their images and other clinical information to be reported in the journal. The patients understand that their names and initials will not be published and due efforts will be made to conceal their identity, but anonymity cannot be guaranteed.

Financial support and sponsorship

Nil.

Conflicts of interest

There are no conflicts of interest.

References

1. Georgalas I, Papaconstantinou D, Koutsandrea C, Kalantzis G, Karagiannis D, Georgopoulos G, *et al.* Angioid streaks, clinical course, complications, and current therapeutic management. *Ther Clin Risk Manag* 2009;5:81-9.
2. Makita Y, Nishimura G, Ikegawa S, Ishii T, Ito Y, Okuno A. Intrafamilial phenotypic variability in Engelmann disease (ED): Are ED and Ribbing disease the same entity? *Am J Med Genet* 2000;91:153-6.
3. Janssens K, Vanhoenacker F, Bonduelle M, Verbruggen L, Van Maldergem L, Ralston S, *et al.* Camurati-Engelmann disease: Review of the clinical, radiological, and molecular data of 24 families and implications for diagnosis and treatment. *J Med Genet* 2006;43:1-11.
4. Carlson ML, Beatty CW, Neff BA, Link MJ, Driscoll CL. Skull base manifestations of Camurati-Engelmann disease. *Arch Otolaryngol Head Neck Surg* 2010;136:566-75.
5. Brodrick JD. Luxation of the globe in Engelmann's disease. *Am J Ophthalmol* 1977;83:870-3.
6. Soni JP, Gupta BD, Soni M, Mund V, Aneja R. Engelmann's disease with optic atrophy. *Indian J Pediatr* 2002;69:823-4.
7. James ER. The etiology of steroid cataract. *J Ocul Pharmacol Ther* 2007;23:403-20.
8. Kersey JP, Broadway DC. Corticosteroid-induced glaucoma: A review of the literature. *Eye (Lond)* 2006;20:407-16.
9. Low SF, Abu Bakar N, Ngui CS. Camurati-engelmann disease association with hypogonadism and primary hypothyroidism. *Iran Red Crescent Med J* 2014;16:e9481.
10. Simpson RK Jr., Fischer DK, Gall GK, Rose JE. Fatal cerebellar herniation secondary to Camurati-Engelmann's disease. *J Neurol Neurosurg Psychiatry* 1988;51:1349-52.