

---

## Maxillary sinus floor augmentation in patients with maxillary sinus pseudocyst: case report

Nukhet Celebi, DDS, PhD,<sup>a</sup> Zeynep Burcin Gonen, DDS,<sup>b</sup> Erdem Kilic, DDS, PhD,<sup>a</sup> Osman Etoz, DDS, PhD,<sup>a</sup> and Alper Alkan, DDS, PhD,<sup>c</sup> Kayseri, Turkey  
ERCIYES UNIVERSITY

The maxillary sinus floor elevation procedure has gained popularity with predictable results, and is a safe, acceptable technique for bone augmentation, providing a base for dental implant treatment. Faint radiopaque lesions at the base of the maxillary sinus are frequent diagnoses on radiographs and must be identified during dental implant planning. Pseudocysts classically appear hemispheric, homogeneously opaque, and well delineated in panoramic and periapical radiographs. The great majority of these lesions are asymptomatic and do not require surgical treatment. In this case report, we present 4 patients who had a maxillary sinus floor elevation procedure using either crestal or lateral approaches in the presence of antral pseudocysts. No complications were encountered during follow-up periods in these patients and all implants are functioning successfully. (**Oral Surg Oral Med Oral Pathol Oral Radiol Endod** 2011;112:e97-e102)

Maxillary sinus floor elevation is a safe and predictable surgical procedure to vertically augment the residual alveolar bone,<sup>1</sup> and allows the placement of dental implants with adequate length in the edentulous posterior maxilla.<sup>2</sup> Currently, a sinus floor elevation procedure can be performed with either a lateral or a crestal approach.<sup>3</sup> The lateral approach was originally described by Tatum and subsequently published by Boyne and James.<sup>4</sup> The classic procedure for this augmentation entails the preparation of a trap door to elevate the Schneiderian membrane in the lateral sinus wall. The space created beneath the lifted sinus membrane is then grafted with different fillers consisting of autogenous bone, bone substitutes, or a mixture of these materials.<sup>4-7</sup> More recently, Summers<sup>1</sup> suggested the crestal approach for sinus floor elevation with subsequent placement of implants, using a set of osteotomes of varying diameters to prepare the implant site. The crestal approach is proposed when there is at least 5 to 6 mm of residual alveolar bone height.<sup>8</sup>

Regardless of the method used, risk assessment must be considered during the preoperative surgical planning

to reduce intra- and postsurgical sinus complications.<sup>9</sup> Radiopaque lesions, such as mucocoeles, retention cysts, and pseudocysts at the floor of the maxillary sinus may present obstacles during sinus elevation.<sup>9</sup> Sinus cysts present different clinicopathologic features and behavior.<sup>10</sup> Mucocoeles are extravasations of mucous into the surrounding soft tissues following trauma or obstruction of salivary flow. The expansive nature of the lesion can cause bone resorption. Retention cysts are thought to arise from blockage of an antral seromucous gland, resulting in a ductal epithelium-lined cystic structure filled with mucin. Pseudocysts are inflammatory in origin and result from fluid accumulation within the sinus membrane. This lesion lacks an epithelial lining.<sup>10</sup> Antral pseudocysts have recently been reported not to be a contraindication for sinus floor augmentation procedures with lateral approach.<sup>11,12</sup>

In this case report, we present 4 patients who had a maxillary sinus floor elevation procedure using either crestal or lateral approaches in the presence of antral pseudocysts.

### MATERIAL AND METHODS

Four patients (2 men, 2 women) with an edentulous atrophic maxilla, median age 42.7 (range, 37-50), underwent maxillary sinus floor bone augmentation procedures (Table I). All of the patients were referred to Erciyes University, Oral and Maxillofacial Surgery Hospital, for implant-supported prosthesis in a partially edentulous maxilla. The panoramic radiographic examination revealed insufficient alveolar bone height for the placement of implants with adequate length on the posterior maxilla, and a dome-shaped, faintly radiopaque lesion, compatible with an antral pseudocyst,

This study was presented as an oral presentation at the 5th ACBID International Conference, May 25-29, 2011.

<sup>a</sup>Assistant Professor, Department of Oral and Maxillofacial Surgery, Faculty of Dentistry, Erciyes University, Kayseri, Turkey.

<sup>b</sup>Resident, Department of Oral and Maxillofacial Surgery, Faculty of Dentistry, Erciyes University, Kayseri, Turkey.

<sup>c</sup>Professor, Department of Oral and Maxillofacial Surgery, Faculty of Dentistry, Erciyes University, Kayseri, Turkey.

Received for publication May 3, 2011; accepted for publication Jun 2, 2011.

1079-2104/\$ - see front matter

© 2011 Mosby, Inc. All rights reserved.

doi:10.1016/j.tripleo.2011.06.001

**Table I.** Patients and procedures

Case	Gender	Age	Radiographic examination	Diameter of pseudocyst (width × height)	Residual bone height	Sinus augmentation procedure	Implants
1	Male	38	OPG + CT	25 × 18 mm	4 mm	Crestal approach	4.0 × 11.5 mm 3I
2	Female	46	OPG	13 × 10 mm	5 mm	Crestal approach	4.0 × 11.5 mm 3I
3	Female	37	OPG	18 × 16 mm	2 mm	Lateral approach	4.1 × 12.0 mm ITI
4	Male	50	OPG + CT	16 × 13 mm	2 mm	Lateral approach	4.1 × 12.0 mm ITI

OPG, orthopantomograph; CT, computerized tomography.

located in the related maxillary sinuses in all of the patients. Antral pseudocyst was confirmed with either computerized tomographic (CT) examination and/or panoramic radiographic examination (Figs. 1-4). The patients' medical histories were uneventful except for case 1, who had been smoking for 20 years.

### Crestal-approach patients

In the first 2 cases, 3I implants (3I Dental Implant System, BIOMET, Inc, Warsaw, IN) were inserted with the crestal approach using osteotomes of gradually increasing diameters in the right posterior maxillas of both patients. No graft materials were used for sinus lifting. Amoxicillin/clavulanic acid, 625 mg twice daily for 10 days, chlorhexidine gluconate-benzylamine HCl mouth rinse 3 times daily for 7 days, and flurbiprofen 100 mg twice daily for 7 days, and a nasal decongestant spray regimen were prescribed to all patients after the operations. The patients had no discomfort and no complaints postoperatively. Final prosthetic restorations were reconstructed at least 4 months after the surgery.

### Lateral-approach patients

In these 2 cases, a 2-stage procedure was performed using the lateral approach. To augment the sinus floor, 1 g of bovine bone xenograft (Bio Oss, Geistlich Sons, Ltd., Wolhusen, Switzerland) was used. The lateral sinus window was covered with platelet-rich fibrin membrane in case 3, and with 20 × 20-mm collagen membrane (OsteoBiol, Tecness Dental, Torino, Italy) in case 4. The same prescriptions as with the first 2 cases were delivered. ITI implants (ITI, Straumann, Basel, Switzerland) were inserted 7 months after the first surgery.

No problems occurred related either to the cyst or to the implants for 6 to 8 months postoperatively for all patients. All implants were osseointegrated successfully in all patients (Figs. 5-8).

## DISCUSSION

Sinus augmentation has a high percentage of success, but presents a number of complications, such as membrane perforation, obstruction of the maxillary ostium,

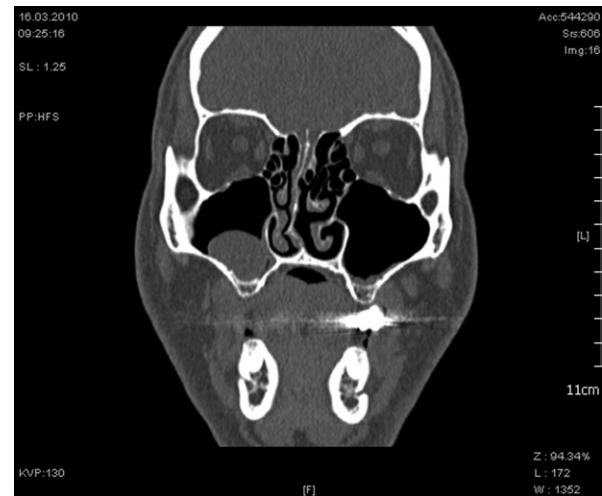

Fig. 1. Right antral pseudocyst was confirmed with CT examination in case 1.

hemorrhage, acute or chronic infection, graft loss, and dental implant failure.<sup>9</sup> Proper maintenance of normal physiology is necessary for decreasing the incidence of complications. The ostium, located 25 to 35 mm above the antral floor, connects the maxillary sinus to the nasal cavity.<sup>13</sup> Ostium in patients with a pseudocyst may be blocked by obliteration of the sinus cavity by overfilling with bone graft in sinus augmentation procedures.

Faint radiopaque lesions at the base of the maxillary sinus are frequently diagnosed on radiographs<sup>9</sup> and must be identified during dental implant planning. Pseudocysts classically appear hemispheric, homogeneously opaque, and well delineated in panoramic and periapical radiographs. They usually demonstrate an attachment to the floor of the maxillary sinus. The great majority of these lesions are asymptomatic and do not require surgical treatment.<sup>14</sup>

Although the literature indicates that sinus augmentation procedures are predictable and safe,<sup>9</sup> the presence of maxillary antral pseudocysts and retention cysts may present an obstacle during sinus elevation and might result in future complications and potential fail-

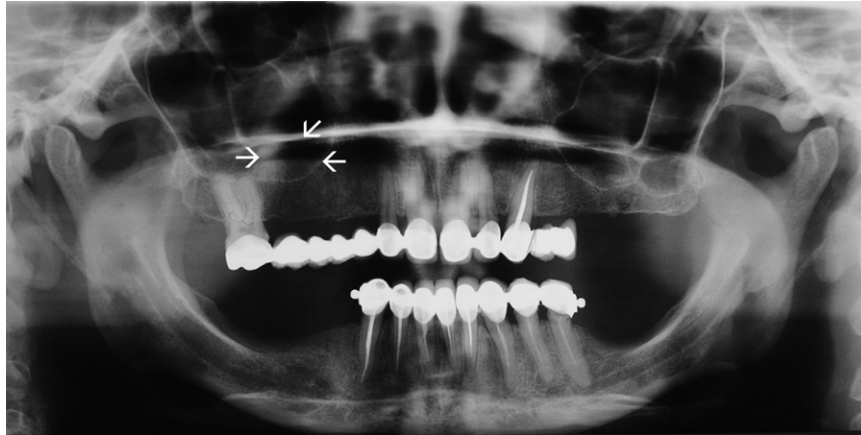


Fig. 2. White arrows indicate maxillary sinus pseudocyst in case 2.

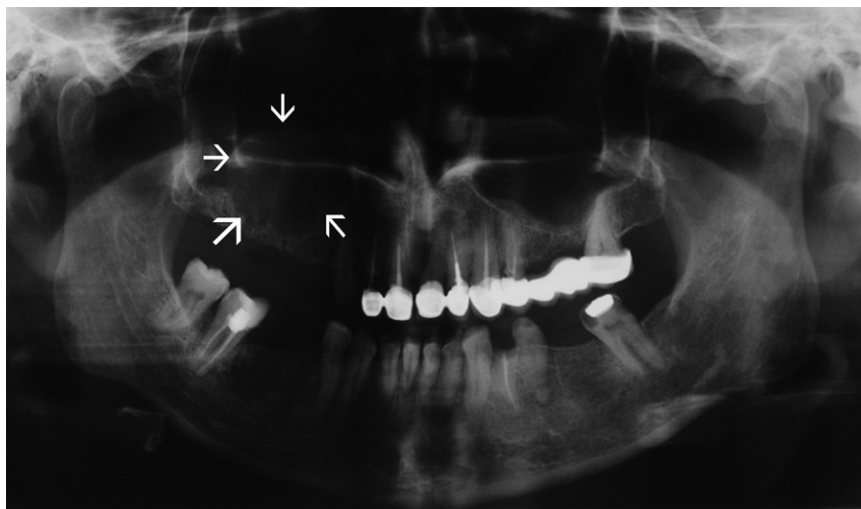


Fig. 3. White arrows indicate maxillary sinus pseudocyst in case 3.

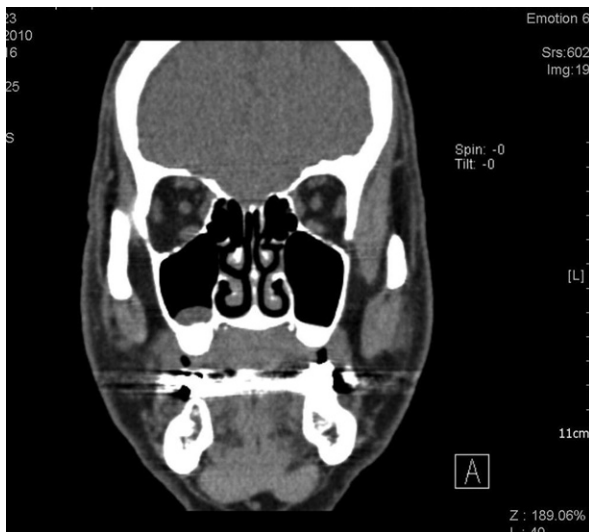


Fig. 4. CT image shows right maxillary sinus pseudocyst after sinus floor elevation in case 4.

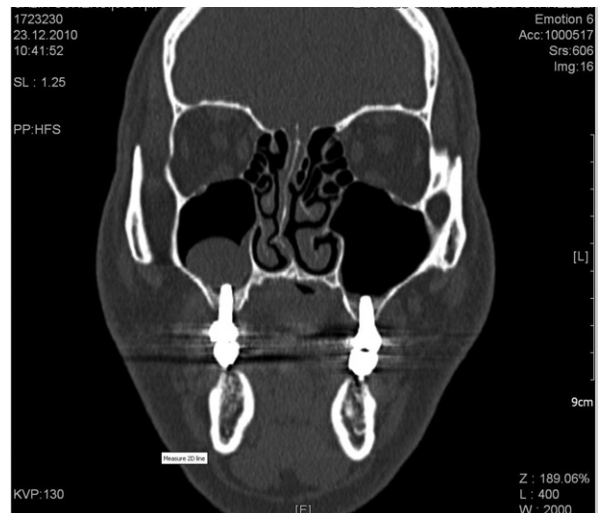


Fig. 5. CT image shows antral pseudocyst and implant relation 3 months after implant insertion in case 1.

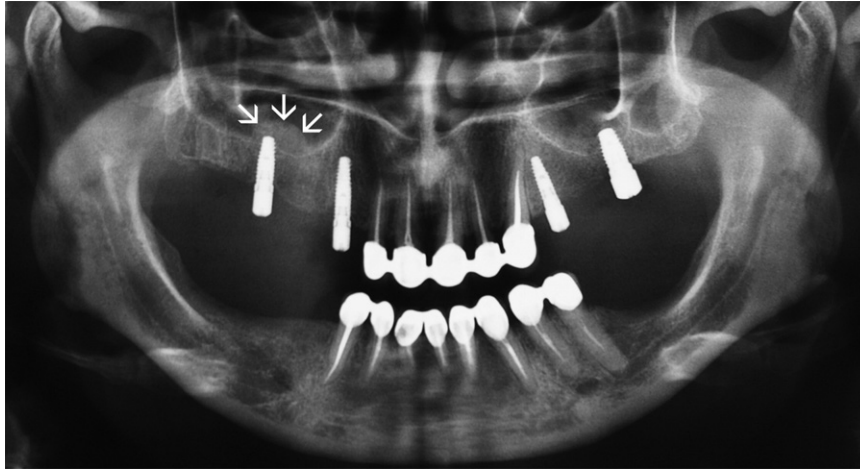


Fig. 6. White arrows indicate maxillary sinus pseudocyst 4 months after implant insertion in case 2.

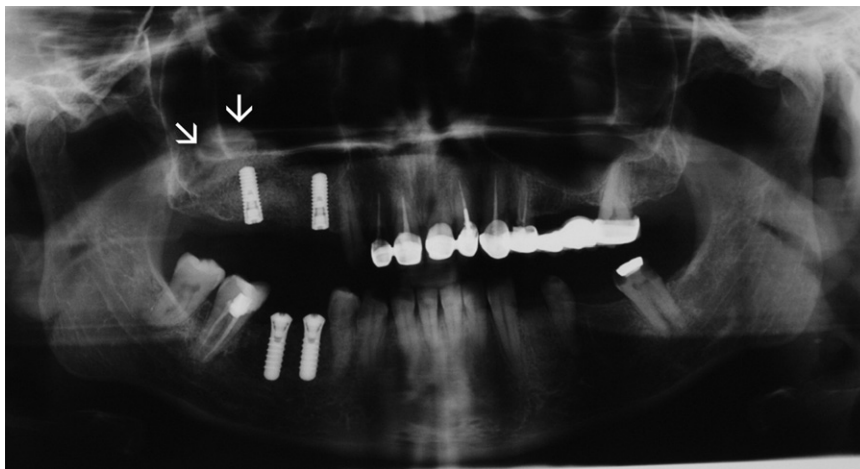


Fig. 7. White arrows indicate the reduced size of the maxillary sinus pseudocyst, 2 months after implant insertion in case 3.

ure.<sup>15</sup> Previously, the presence of an antral cystic lesion has been considered to be a contraindication for maxillary sinus floor augmentation and is recommended to be treated before the surgery.<sup>16</sup> The Caldwell-Luc operation or endoscopic sinus surgery has been recommended as the optimal treatment, and complete removal of the sinus lining is advocated to avoid recurrences. At least 6 months of healing time after antral cystic lesion removal was suggested before a sinus augmentation is performed.<sup>15</sup> However, recent studies have reported that antral pseudocysts are not a contraindication for sinus floor augmentation procedures.<sup>11,12</sup> In their clinical study, Mardinger et al.<sup>11</sup> performed 129 maxillary sinus floor augmentation in patients with a significant antral pseudocyst on radiographs. Only 6 patients developed postoperative sinusitis, which was treated with

antibiotics and all patients showed successful healing with well-functioning implants. Perfetti et al.<sup>17</sup> also reported successful results for sinus lift procedures in patients with sinus mucoceles. Kara et al.<sup>12</sup> reported maxillary sinus floor augmentation in 2 patients with antral pseudocysts. In one of the cases, the authors observed bone and membrane perforation caused by an antral pseudocyst. They closed the perforation with a collagen membrane and augmented the sinus floor with bone grafts. The implants osseointegrated successfully.

A clinical differential diagnosis of cysts and pseudocysts arising within the mucosa of the maxillary sinus would include polyps, hyperplasia of the sinus lining as a result of infection, maxillary sinusitis, and neoplasms arising within the antral lining.<sup>14</sup> Retention cysts and mucoceles can also be confused with pseudocysts. Re-

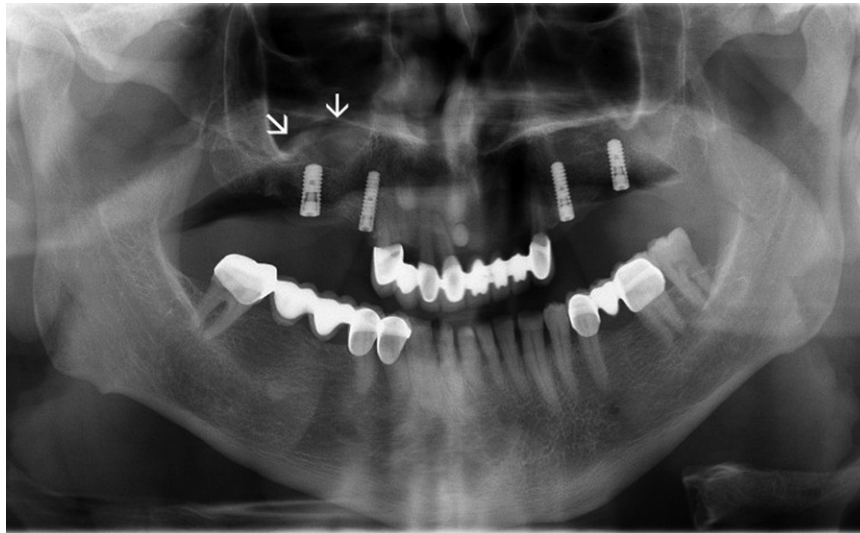


Fig. 8. White arrows indicate maxillary sinus pseudocyst after implant insertion in case 4.

tention cysts seldom become large enough to be evident on radiographs<sup>11</sup> and they are commonly encountered around the ostium. Mucocèles are differentiated from pseudocysts, as they cause opacification of the affected sinus and expand into the adjacent structures.<sup>18</sup> In the literature, it is proposed that dental and CT scans are required in the presence of radiopaque lesions of the maxillary sinus<sup>11,17</sup> when implants are to be placed to the posterior alveolar maxilla. Perfetti et al.<sup>17</sup> reported that sinus augmentation procedures could be carried out without complications when the mucocèle is no larger than 18 mm.<sup>17</sup> In 2 of our cases, because the vertical diameters of the pseudocysts were 18 mm or smaller, and the relationship between the pseudocyst and the ostium of the maxillary sinus were obvious on the panoramic radiographs, CT scans were not obtained.

To our knowledge, the crestal technique related to an antral pseudocyst has not been reported in the literature. Internal sinus lift procedure has proven to be successful and has become popular. The advantage of the internal sinus augmentation technique is that it is a less invasive technique with a lower risk of complications both during and following surgery.<sup>3</sup> In 2 of our patients who had antral pseudocysts, because there was sufficient bone for primary stabilization of the implants, the crestal approach was preferred to augment the maxillary sinus floor. No complications were encountered during follow-up periods in these patients and all implants are functioning successfully.

In conclusion, a sinus augmentation procedure of the maxillary sinus using either a crestal or lateral approach seems to be safe and predictable in the presence of an

antral pseudocyst in asymptomatic patients. The technique reduces the time for healing for the implants, eliminating the need for surgical treatment of the pseudocyst. It also reduces the risk of complications arising from multiple surgeries. A meticulous clinical and radiographic examination regarding the pathologic variations of the maxillary sinus (sinusitis, cysts, tumors, and so forth) is essential before maxillary sinus floor augmentation procedures.

## REFERENCES

1. Summers RB. A new concept in maxillary implant surgery: the osteotome technique. *Compend Contin Educ Dent* 1994;15: 152-62.
2. Trombelli L, Minenna P, Franceschetti G, Minenna L, Itró A, Farina R. Minimally invasive technique for transcresal sinus floor elevation: a case report. *Quintessence Int* 2010;41:363-9.
3. Woo I, Le BT. Maxillary sinus floor elevation: review of anatomy and two techniques. *Implant Dent* 2004;13:28-32.
4. Boyne P, James RA. Grafting of the maxillary sinus floor with autogenous marrow and bone. *J Oral Maxillofac Surg* 1980; 17:113-6.
5. Garg AK. Augmentation grafting of the maxillary sinus for placement of dental implants: anatomy, physiology and procedures. *Implant Dent* 1999;8:36.
6. Rosen MD, Sarnat BG. Change of volume of the maxillary sinus of the dog after extraction of adjacent teeth. *Oral Surg Oral Med Oral Pathol* 1955;8:420.
7. Chanavaz M. Maxillary sinus: Anatomy, physiology, surgery, and bone grafting related to implantology—eleven years of surgical experience (1979-1990). *J Oral Implantol* 1990; 16:199.
8. Kasabah S, Kruk J, Simunek A, Lecaro MC. Can we predict maxillary sinus mucosa perforation? *Acta Med* 2003;46:19-23.
9. Katranji A, Fotek P, Wang HL. Sinus augmentation complications: etiology and treatment. *Implant Dent* 2008;17: 3339-446.

10. Gardner DG. Pseudocyst and retention cyst of the maxillary sinus. *J Oral Surg* 1984;58:561-7.
11. Mardinger O, Manor I, Mijiritsky E, Hirshberg A. Maxillary sinus augmentation in the presence of antral pseudocyst: a clinical approach. *Oral Surg Oral Med Oral Pathol Oral Radiol Endod* 2007;103:180-4.
12. Kara IM, Küçük D, Polat S. Experience of maxillary sinus floor augmentation in the presence of antral pseudocysts. *J Oral Maxillofac Surg* 2010;68:1646-50.
13. May M, Sobol SM, Korzec K. The location of the maxillary os and its importance to the endoscopic sinus surgeon. *Laryngoscope* 1990;100:1037-42.
14. Regezi JA, Sciubba JJ, Jordan RCK, editors. *Oral pathology: clinical pathologic correlations*, 5th ed. St.Louis: W. B. Saunders; 2008. p 182-3.
15. Beaumont C, Zafropoulos GG, Rohmann K, Tatakis DN. Prevalence of maxillary sinus disease and abnormalities in patients scheduled for sinus lift procedures. *J Periodontol* 2005;76:461-7.
16. Garg AK, Mugnolo GM, Saskaen H. Maxillary antral mucocele and its relevance for maxillary sinus augmentation grafting: a case report. *Int J Oral Maxillofac Implants* 2000;15:287-90.
17. Perfetti G, Rossi F, Massei G, Raffaelli L, Manicone PF, Paolantonio M, et al. Sinus augmentation procedure of the jaw sinus in patients with mucocele. *Int J Immunopathol Pharmacol* 2008;21:243-6.
18. Franklin ML, Nelson LCB, Castle CJT. Differentiating sinonasal cyst and cyst-like entities. *Clin Update* 2006;28:6.

*Reprint requests:*

Zeynep Burcin-Gonen, DDS  
Erciyes University  
Faculty of Dentistry  
Department of Oral and Maxillofacial Surgery  
38039 Melikgazi  
Kayseri, Turkey  
[zburcin@gmail.com](mailto:zburcin@gmail.com)