Indian Journal of Orthopaedics
https://doi.org/10.1007/s43465-025-01638-5

ORIGINAL ARTICLE

Intrapelvic Landmarks Are Highly Unreliable in Acetabular Cup Positioning Through Direct Anterior and Posterolateral Approaches: A Cadaveric Study

Fatih Yildiz[1] · Mustafa Alper Incesoy[1] · Ahmet Can Erdem[1] · Cemil Burak Demirkiran[2] · Asena Ayca Ozdemir[3] · Ibrahim Tuncay[4]

Received: 24 May 2025 / Accepted: 23 November 2025
© Indian Orthopaedics Association 2025

Abstract

Background Accurate acetabular cup placement is crucial for the long-term success of total hip arthroplasty (THA). This cadaveric study investigated the reliability of intrapelvic landmarks for cup positioning in conventional THA, examining the influence of surgeon experience, surgical approach (direct anterior and posterolateral), and pelvic positioning.

Methods 108 conventional THA procedures were performed on 24 hips of 12 lower extremity cadavers by nine surgeons with different surgical experiences (Group I: high volume, group II: intermediate volume and group III: low volume) through a posterolateral (PL) or direct anterior approach (DAA). The anteversion and inclination of the acetabular cups were measured using an image-based robotic arm system. Outliers were defined according to Lewinnek's and Callanan's safe zones and the groups were compared.

Results In groups I, II and III, the percentages of cups within the safe zone of Lewinnek for the combined versions were 38.9, 33.3, and 27.8 for DAA ($p = 0.12$); and 16.7, 27.8, and 16.7 for PL ($p = 0.633$) approaches, respectively, while the percentage of cups within the safe zone of Callanan for the combined versions was 27.8, 27.8, and 16.7 for DAA ($p = 0.667$); and 11.1, 16.7, and 11.1 for PL ($p = 0.849$) approaches, respectively.

Conclusion This study demonstrates the unreliability of intrapelvic landmarks for accurate acetabular cup placement in conventional THA, irrespective of surgeon experience. The absence of the trunk in the cadaveric model may have affected pelvic tilt, underscoring the importance of intraoperative pelvic positioning in achieving optimal cup placement. These findings suggest that reliance on intrapelvic landmarks alone may not be sufficient for accurate cup positioning and highlight the potential benefits of alternative techniques, such as robotic-assisted THA.

Keywords Total hip arthroplasty (THA) · Acetabular cup accuracy · Robotic-assisted THA · Safe zone · Surgeon experience · Cadaveric study

✉ Mustafa Alper Incesoy
alperincesoy@gmail.com; incesoyalper@yahoo.com

1 Department of Orthopedics, Bezmialem Vakif University Faculty of Medicine, Iskender Pasa District Adnan Menderes Boulevard, Fatih, 34093 Istanbul, Turkey

2 Department of Orthopedics, Tekirdag Saray State Hospital, Ayaspaşa, Kumardere Sokak No: 2/B, Saray, 59610 Tekirdağ, Turkey

3 Department of Biostatistics and Medical Informatics and Department of Medical Education, Faculty of Medicine, Mersin University, 33110 Mersin, Turkey

4 Department of Orthopedics, Acibadem University Faculty of Medicine, Darüşşafaka, Büyükdere Cd. No: 40, Sarıyer, 34457 Istanbul, Turkey

Introduction

Total hip arthroplasty (THA) is a highly effective surgery in the treatment of symptomatic hip osteoarthritis [1]. However, advancements in the surgical techniques, designs and quality of the implants have continued to increase patient satisfaction and implant survival and to decrease the rate of complications, re-operations and revisions. Moreover, a successful THA might be considered if more than 20 years of implant survival is achieved. Several factors which affect long-term implant survival have been identified and one of them is component positioning. There is no doubt that the accuracy of the implant placement is important for decreasing complications, revisions, and re-operations, and

Published online: 02 December 2025

therefore long-term implant survival after a successful THA [2–13].

In acetabular component placement during total hip arthroplasty, precise orientation is paramount. Surgeons aim to position the acetabular cup with optimal inclination and anteversion, parameters collectively defined by Lewinnek and Callaghan as the "safe zone" [2, 14]. Accurate cup placement is therefore contingent upon the combined anteversion and inclination falling within this established safe zone. Consequently, numerous surgical methodologies have been developed to enhance the precision of cup placement within the desired three-dimensional spatial orientation [15–18].

Many factors can affect a surgeon's orientation during acetabular reaming and cup placement: surgeons' experience, patients' phenotypes, surgical approach, spinopelvic conditions, contractures, bony deformities or patient positioning on the operative table may have a role in obtaining correct acetabular cup positioning. Some authors suggest that surgeons' level of experience and the surgical approaches play more important roles in the accuracy of acetabular cup placement [19–21]. For this reason, robotic THA has been developed to provide precision of implant placement by potentially eliminating all those surgeons or patient-related factors [22–25].

We hypothesized that in posterolateral (PL) or direct anterior approaches (DAA), the level of surgical experience does not affect the accuracy of acetabular cup positioning if only intraoperative landmarks such as the transverse acetabular ligament, acetabular walls, anterior inferior iliac spine, are used during its placement. The aim of this study was to investigate the accuracy of cup positioning in the conventional THA technique on cadavers, with respect to surgeons' level of experiences, surgical approaches, and pelvic positioning.

Methods

Cadaveric Tests

This cadaveric study was approved by the Institutional Review Board and the Ethical Committee of Bezmialem University. The investigation was performed at the cadaveric laboratory of Koç University (Rahmi M. Koç Academy of Interventional Medicine, Education, and Simulation). All body donors, or their closest living relatives, provided consent for their bodies to be stored and utilized for research purposes before the donors passed away.

A total of nine investigators (six orthopedic surgeons and three senior residents) were divided into three groups according to their level of experience in THA. Group I: high-volume surgeons, who perform more than 50 THA per year. Group II: intermediate-volume surgeons who perform 11–50 THA per year. In addition, group III: low-volume surgeons (senior residents), who have performed 10 or fewer THA per year.

In 12 fresh-frozen, lower extremity cadavers, a total of 108 acetabular cup placement procedures were performed through DAA ($n=6$) or PL ($n=6$) approaches by three groups of surgeons. They did not have any prior surgical intervention to their pelvises.

Since we used the MAKO™ robotic arm (MAKOplasty® total hip application; MAKO™ Surgical Corporation, Ft. Lauderdale, FL, USA) to measure final acetabular component positions, all fresh-frozen, lower extremity cadavers underwent computerized tomography (CT) scans for the preoperative *3-dimensional* planning of the MAKO™ robotic hip system. CT landmarks and the operative plan were conducted using the MAKO software and reviewed by all surgeons for each cadaver.

For DAA, lower extremity cadavers were placed supine and their pelvises were fixed to the operative table with a special clamp (Fig. 1). For the placement of the pelvic array, three 3.2 mm half-pins were inserted into the opposite iliac crest. A Hueter approach was then used, involving about a 10 cm incision made longitudinally, starting 2 cm distal and posterior to the anterior superior iliac spine. After a T-shaped incision was made in the joint capsule, the femoral neck was cut and taken out. Finally, the acetabular checkpoint was positioned near the supra-acetabular region, and the registration process was successfully completed and confirmed. The acetabulum was reamed with the appropriate size using the robotic arm by another surgeon who did not participate in component positioning and the test surgeons were blinded to acetabular reaming. Then, each surgeon was asked to position the trial acetabular cup in 40° of abduction

Fig. 1 A cadaver in the supine position underwent total hip arthroplasty of the right hip via a direct anterior approach

and 20° of anteversion. At this step, the cup was attached to the robotic arm, the robotic arm was in its free mode and the surgeon was not able to see the monitor of the robotic system which shows the instant position of the cup (Fig. 2). When the surgeon kept the cup in the final position, the Mako Product Specialist (MPS) captured anteversion and abduction degrees of the trial and noted.

For the PL approach, the lower extremity cadavers were placed in the lateral decubitus position and fixed to the table (Fig. 3). The hip was dislocated using a standard PL approach, the neck was cut, and the registration process was completed. Similar to the DAA group, the acetabulum was reamed with the robotic arm by a surgeon who did not participate in the tests and then each surgeon who was blinded to acetabular reaming placed the trial cup in the acetabulum aiming for 20° of anteversion and 40° of inclination, using the robotic arm in its free mode without watching the monitor. MPS collected the data for each test.

After recording the final degrees of anteversion and inclination of each test, the groups were compared for the mean values, and for the % of cups being in the safe zones of Lewinnek and Callaghan.

Fig. 2 The acetabular component was attached to the robotic arm, which was in its free mode, and the surgeon was unable to visualize the robotic system's monitor displaying the real-time position of the component

Fig. 3 A cadaver in the lateral decubitus position underwent total hip arthroplasty of the left hip via a posterolateral approach

Statistical Analysis

Normality control of continuous variables was evaluated with the Shapiro–Wilk test. Variables showing normal distribution were analyzed with parametric methods, and those not showing normal distribution were analyzed with non-parametric methods. Independent Sample *t* test and Mann–Whitney *U* test were used in independent two group comparisons. Data analysis was done in IBM SPSS 21 program. The study was designed to compare the successful cup placement status of three groups in anteversion, inclination and combined measurements. For this purpose, it was found appropriate to make a total of 108 measurements with a 3×2 Chi-square order of 0.30 (medium level) effect size, 80% power and 5% type I error for the difference between the success rates among three independent groups. Accordingly, in order for the participants in the groups to make homogeneous measurements, each participant was allowed to make a total of 12 trials for each measurement. For these purposes, cup accuracy measurements could be made on 12 cadavers, while placement successes were recorded for each participant in anteversion and inclination angles and a homogeneous measurement order was provided.

Results

The cadavers were similar in terms of their ages ($p = 0.478$), heights ($p = 0.674$), and weights ($p = 0.197$). The mean, minimum, and maximum, and standard deviations of anteversion and inclination for each group are given in Table 1. The mean inclinations were similar between the groups for DAA ($p = 0.087$) and PL ($p = 0.116$) approaches. The mean anteversions were also similar between the groups for the PL approach. For DAA, the only difference was found to be between group II and group III ($p = 0.014$) (Table 1).

In groups I, II and III, % of cups within the safe zone of Lewinnek for the anteversions were 72.2, 88.9 and 55.6 for DAA ($p = 0.083$); and 50, 50 and 44.4 for PL ($p = 0.929$) approaches, respectively (Fig. 4). For the inclination, they were 61.1, 38.9 and 61.1 in DAA ($p = 0.148$); and 38.9, 50 and 55.6 in PL ($p = 0.595$) groups, respectively (Fig. 4). % of cups within the safe zone of Callanan for the anteversion were the same as that of Lewinnek. For the inclination, they were found to be 50, 33.3 and 44.4 in DAA ($p = 0.589$); and 33.3, 38.9 and 33.3 in PL ($p = 0.922$) groups, respectively (Fig. 4). In groups I, II and III, the percentage of cups within the safe zone of Lewinnek for the combined versions were 38.9, 33.3, and 27.8 for DAA ($p = 0.12$); and 16.7, 27.8, and 16.7 for PL ($p = 0.633$) approaches, respectively (Fig. 4), while the percentage of cups within the safe zone of Callanan for the combined versions were 27.8, 27.8, and 16.7 for DAA ($p = 0.667$); and 11.1, 16.7, and 11.1 for PL ($p = 0.849$) approaches, respectively (Fig. 4).

Discussion

The most important finding of the present study was that according to Lewinnek's and Callaghan's safe zones, the rates of outliers in the anteversion and/or inclination of the acetabular cups positioned using only anatomical landmarks of the pelvis and the acetabulum are too high. Another important finding is that surgical experience or case volume did not have an effect to reduce the outliers on the cadaveric models. There may be several reasons for these unexpected findings. However, considering the results of the current study, the accuracy of the acetabular cup positioning in the conventional technique should be criticized even in the experienced hands.

Table 1 Values of anteversion and inclination for each group

Anteversion	DAA		PL	
	Mean ± SD	Min–max	Mean ± SD	Min–max
Group 1	15.33 ± 7.65	0–29	26.28 ± 10.67	5–51
Group 2	14.17 ± 7.45	0–35	26.33 ± 6.89	15–42
Group 3	21.50 ± 8.20	2–35	28.00 ± 6.72	16–39
p-value	0.014*		0.779	
Inclination				
Group 1	32.50 ± 8.81	20–49	33.28 ± 13.31	12–59
Group 2	27.94 ± 10.47	8–47	34.39 ± 12.58	10–51
Group 3	35.06 ± 9.26	21–56	41.50 ± 11.91	19–56
p-value	0.087		0.116	

*Group 2 and Group 3 were found to be significantly different

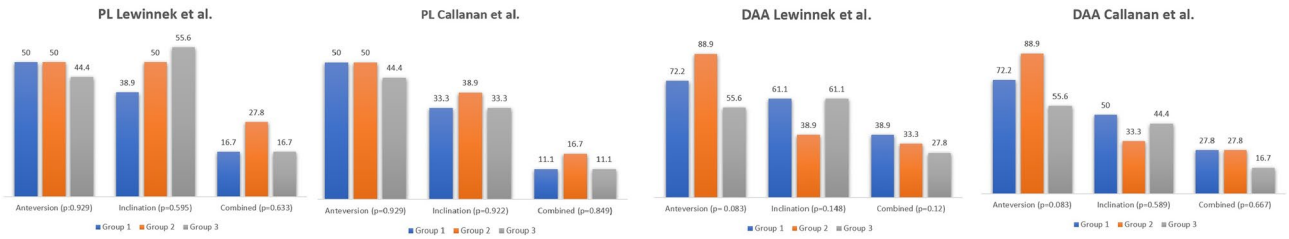

Fig. 4 The clustered column charts illustrate the distribution of three groups within the Lewinnek et al.'s and Callanan et al.'s safe zones for acetabular component positioning in the posterolateral and the direct anterior approach

There is no doubt that acetabular cup positioning is related to some of the major complications of THA and its survival [2–14]. Therefore, a proper cup placement is paramount to provide long-term implant survival and satisfactory clinical outcomes. Achieving this goal sometimes can be difficult and there may be a mismatch between the preoperative plan and the surgeon's execution, which is usually surprisingly seen on the postoperative X-rays. In conventional THA, surgeons use different methods to find accurate anteversion and inclination of the cup during its insertion [26]. However, many factors such as patients' weight, especially the abdominal obesity, intraoperative pelvic position, its obliquity or tilt, position of the shoulder or trunk, transverse acetabular ligament, contractures or bony deformities may affect a surgeon's orientation and cause unintended cup position [2, 4, 27–29].

Lewinnek et al. [14] established specific ranges for optimal acetabular cup placement, defining a "safe zone" with an inclination between 30° and 50° and an anteversion from 5° to 25°. Callanan et al. [2] proposed a refined "safe zone," maintaining the anteversion range of 5°–25° but narrowing the inclination to between 30° and 45°. In our cadaveric study, in the PL approach group, < 28% and 17% of the cups for all surgical experience levels were positioned within the safe zones of Lewinnek et al. and Callanan et al., respectively. They were found to be a little bit higher (39% and 28%, respectively) but still too low for the DAA approach. The percentages of the cups being in the safe zones were too low even for the experienced surgeon groups. This unexpected result could be caused by several factors. As shown in some studies, decreased accuracy observed in cup placement may be attributed to the limitations of relying solely on intrapelvic anatomical landmarks during its positioning [29, 30]. The absence of the trunk above the pelvis in the cadavers used in this study may have impacted the pelvic tilt and positioning during the surgical procedure. Surgeons, regardless of their levels of experience, need to be aware of several challenges during surgery: anatomical landmarks that might be unclear or altered, changes in pelvic tilt and positioning during the operation, the limitations of standard alignment tools, and individual patient factors such as obesity [31–33]. For this reason, robotic-assisted THA has emerged as a potential solution, with studies suggesting superior cup positioning compared to the conventional techniques [34–36].

Numerous studies have investigated the impact of a surgeon's experience on the accurate placement of the acetabular cup during total hip arthroplasty (THA). Cumulative evidence suggests a substantial correlation between surgeon expertise and improved outcomes in cup positioning [14, 37, 38]. Experienced surgeons tend to demonstrate greater precision in interpreting anatomical landmarks, achieving desired inclination and anteversion angles, and adapting to variations in patient anatomy. Suhardi et al. found that fellows demonstrated a higher level of accuracy in cup placement compared to residents, and the precision of cup placement showed a positive correlation with the participants' level of training, indicating that individuals with more years of training exhibited greater accuracy in placing the cup during the procedure [19]. Contrary to expectations, the experience of surgeons did not significantly alter the rate of outliers in the current cadaver study, and this lack of change may be attributed to the positions of the cadavers' pelvis and lower extremities on the operative table. Research has also shown that even experienced surgeons can produce outliers, resulting in radiographic anteversion and inclination measurements varying by as much as ± 20° [24, 39, 40]. Following the acquisition of proficiency in robot-assisted THA, the surgeon may demonstrate a statistically significant improvement in achieving optimal cup positioning using the robotic technique compared to their own conventional technique [41].

Several potential limitations should be considered when interpreting the results of this study. First, the trunk above the pelvis was missing in the cadavers. In our cadaveric study investigating acetabular positioning during conventional THA, the absence of the trunk above the pelvis may have caused errors due to non-replication of anatomical landmarks other than intrapelvic landmarks. On the other hand, this was an advantage to show that intrapelvic landmarks are unreliable and body position is important to achieve acceptable cup positioning. Second, we used the robotic system to measure final cup positions and we assumed that its measurement is correct. However, from the literature, we know that its accuracy is too high. Alternatively, we could make measurements on the AP X-rays taken after implant placements. However, this method also could cause difficulties in having standard pelvic positions and subsequent errors in measurements of inclinations and anteversions. Lastly, a control group using robotic-assisted surgery was not included, which could be beneficial to show differences in the results between conventional and robotic systems in the same cadavers.

In conclusion, this cadaveric study revealed that intrapelvic landmarks are unreliable for the orientation of a surgeon during acetabular cup placement through PL or DAA. High-volume hip surgeons are also prone to make severe malpositioning of the cups in the cadaveric models. Therefore, we emphasize that intraoperative pelvic position is important to achieve a desirable cup position.

Acknowledgements We thank Vahdet UCAN, MD, Murat SARIKAS, MD, Hakan Batuhan KAYA, MD, and Nurzat ELMALI, MD for their valuable contributions to the acquisition and collection of the cadaveric data.

Author Contributions Mustafa Alper Incesoy conceived the idea of the study and supervised the IRB proposal, study design, collection of data and wrote the first and edited subsequent drafts. Vahdet Ucan, Ahmet Can Erdem, Murat Sarıkas, Cemil Burak Demirkiran and Hakan Batuhan Kaya worked in the collection of the data. Asena Ayca Ozdemir worked in the analysis of the data. Ibrahim Tuncay, Fatih Yıldız and Nurzat Elmalı participated in study design and edited the subsequent drafts.

Funding The cadavers utilized in this research were provided by Stryker.

Data Availability The datasets generated during and/or analyzed during the current study are available from the corresponding author on reasonable request.

Declarations

Conflict of interest Fatih Yildiz and Ibrahim Tuncay have financial relationships with Stryker. They are paid by Stryker to give presentations and provide consulting services.

Ethical Approval and Consent to Participate This study was conducted in accordance with the ethical standards of the Bezmialem Vakıf University Review Board and the 1964 Helsinki Declaration and its later amendments or comparable ethical standards. Consent for the storage and use of the cadavers for research purposes was obtained by all body donors prior to death or from their next of kin.

References

1. Learmonth, I., Young, C., & Rorabeck, C. (2007). The operation of the century: Total hip replacement. *Lancet, 370*(9597), 1508–1519. https://doi.org/10.1016/S0140-6736(07)60457-7
2. Callanan, M., Jarrett, B., Bragdon, C., Zurakowski, D., Rubash, H., Freiberg, A., & Malchau, H. (2011). The John Charnley Award: Risk factors for cup malpositioning: Quality improvement through a joint registry at a tertiary hospital. *Clinical Orthopaedics and Related Research, 469*(2), 319–329. https://doi.org/10.1007/s11999-010-1487-1
3. Shon, W., Baldini, T., Peterson, M., Wright, T., & Salvati, E. (2005). Impingement in total hip arthroplasty a study of retrieved acetabular components. *The Journal of Arthroplasty, 20*(4), 427–435. https://doi.org/10.1016/j.arth.2004.09.058
4. Widmer, K., & Zurfluh, B. (2004). Compliant positioning of total hip components for optimal range of motion. *Journal of Orthopaedic Research, 22*(4), 815–821. https://doi.org/10.1016/j.orthres.2003.11.001
5. Yamaguchi, M., Akisue, T., Bauer, T., & Hashimoto, Y. (2000). The spatial location of impingement in total hip arthroplasty. *The Journal of Arthroplasty, 15*(3), 305–313. https://doi.org/10.1016/s0883-5403(00)90601-6
6. Ali Khan, M., Brakenbury, P., & Reynolds, I. (1981). Dislocation following total hip replacement. *Journal of Bone and Joint Surgery. British Volume, 63-B*(2), 214–218. https://doi.org/10.1302/0301-620X.63B2.7217144
7. Biedermann, R., Tonin, A., Krismer, M., Rachbauer, F., Eibl, G., & Stöckl, B. (2005). Reducing the risk of dislocation after total hip arthroplasty: The effect of orientation of the acetabular component. *The Journal of Bone and Joint Surgery. British Volume, 87*(6), 762–769. https://doi.org/10.1302/0301-620X.87B6.14745
8. De Haan, R., Pattyn, C., Gill, H., Murray, D., Campbell, P., & De Smet, K. (2008). Correlation between inclination of the acetabular component and metal ion levels in metal-on-metal hip resurfacing replacement. *The Journal of Bone and Joint Surgery. British Volume, 90*(10), 1291–1297. https://doi.org/10.1302/0301-620X.90B10.20533
9. Gallo, J., Havranek, V., & Zapletalova, J. (2010). Risk factors for accelerated polyethylene wear and osteolysis in ABG I total hip arthroplasty. *International Orthopaedics, 34*(1), 19–26. https://doi.org/10.1007/s00264-009-0731-3
10. Kennedy, J., Rogers, W., Soffe, K., Sullivan, R., Griffen, D., & Sheehan, L. (1998). Effect of acetabular component orientation on recurrent dislocation, pelvic osteolysis, polyethylene wear, and component migration. *The Journal of Arthroplasty, 13*(5), 530–534. https://doi.org/10.1016/s0883-5403(98)90052-3
11. Leslie, I., Williams, S., Isaac, G., Ingham, E., & Fisher, J. (2009). High cup angle and microseparation increase the wear of hip surface replacements. *Clinical Orthopaedics and Related Research, 467*(9), 2259–2265. https://doi.org/10.1007/s11999-009-0830-x
12. Morrey, B. (1997). Difficult complications after hip joint replacement. Dislocation. *Clinical Orthopaedics and Related Research, 344*, 179–187.
13. Murphy, S., & Ecker, T. (2007). Evaluation of a new leg length measurement algorithm in hip arthroplasty. *Clinical Orthopaedics and Related Research, 463*, 85–89. https://doi.org/10.1097/BLO.0b013e318126c08f
14. Lewinnek, G., Lewis, J., Tarr, R., Compere, C., & Zimmerman, J. (1978). Dislocations after total hip-replacement arthroplasties. *The Journal of Bone and Joint Surgery. American Volume, 60*(2), 217–220.
15. Anjiki, K., Kamenaga, T., Hayashi, S., Hashimoto, S., Kuroda, Y., Nakano, N., Fujishiro, T., Hiranaka, T., Niikura, T., Kuroda, R., & Matsumoto, T. (2022). Effectiveness of an accelerometer-based portable navigation for intraoperative adjustment of leg length discrepancy in total hip arthroplasty in the supine position. *Journal of Orthopaedic Science, 27*(1), 169–175. https://doi.org/10.1016/j.jos.2020.11.003
16. Constantinescu, D. S., Costello, J. P., Dalling, A. D., Wagner, J. D., Al-Hardan, W., & Carvajal, J. A. (2022). The efficacy of patient specific instrumentation (PSI) in total hip arthroplasty (THA): A systematic review and meta-analysis. *Journal of Orthopaedics, 34*, 404–413. https://doi.org/10.1016/j.jor.2022.10.001
17. Sakai, T. (2018). Patient-specific surgical guide for total hip arthroplasty. *Advances in Experimental Medicine and Biology, 1093*, 307–314. https://doi.org/10.1007/978-981-13-1396-7_23
18. Beamer, B. S., Morgan, J. H., Barr, C., Weaver, M. J., & Vrahas, M. S. (2014). Does fluoroscopy improve acetabular component placement in total hip arthroplasty? *Clinical Orthopaedics and Related Research, 472*(12), 3953–3962. https://doi.org/10.1007/s11999-014-3944-8
19. Suhardi, V. J., Chiu, Y.-F., Sculco, P. K., & Gonzalez Della Valle, A. (2021). Accuracy of acetabular cup placement positively correlates with level of training. *International Orthopaedics, 45*(11), 2797–2804. https://doi.org/10.1007/s00264-021-05165-4
20. Kobayashi, H., Homma, Y., Baba, T., Ochi, H., Matsumoto, M., Yuasa, T., & Kaneko, K. (2016). Surgeons changing the approach for total hip arthroplasty from posterior to direct anterior with fluoroscopy should consider potential excessive cup anteversion and flexion implantation of the stem in their early experience. *International Orthopaedics, 40*(9), 1813–1819. https://doi.org/10.1007/s00264-015-3059-1
21. Takada, R., Jinno, T., Miyatake, K., Hirao, M., Yagishita, K., Yoshii, T., & Okawa, A. (2019). Supine versus lateral position for accurate positioning of acetabular cup in total hip arthroplasty using the modified Watson-Jones approach: A randomized single-blind controlled trial. *Orthopaedics & Traumatology, Surgery & Research, 105*(5), 915–922. https://doi.org/10.1016/j.otsr.2019.05.004

22. Gupta, A., Redmond, J., Hammarstedt, J., Petrakos, A., Vemula, S., & Domb, B. (2015). Does robotic-assisted computer navigation affect acetabular cup positioning in total hip arthroplasty in the obese patient? A comparison study. *The Journal of Arthroplasty, 30*(12), 2204–2207. https://doi.org/10.1016/j.arth.2015.06.062
23. Domb, B., Redmond, J., Louis, S., Alden, K., Daley, R., LaReau, J., Petrakos, A. E., Gui, C., & Suarez-Ahedo, C. (2015). Accuracy of component positioning in 1980 total hip arthroplasties: A comparative analysis by surgical technique and mode of guidance. *The Journal of Arthroplasty, 30*(12), 2208–2218. https://doi.org/10.1016/j.arth.2015.06.059
24. Barrack, R., Krempec, J., Clohisy, J., McDonald, D., Ricci, W., Ruh, E., & Nunley, R. M. (2013). Accuracy of acetabular component position in hip arthroplasty. *The Journal of Bone and Joint Surgery. American Volume, 95*(19), 1760–1768. https://doi.org/10.2106/JBJS.L.01704
25. Elson, L., Dounchis, J., Illgen, R., Marchand, R., Padgett, D., Bragdon, C., & Malchau, H. (2015). Precision of acetabular cup placement in robotic integrated total hip arthroplasty. *Hip International, 25*(6), 531–536. https://doi.org/10.5301/hipint.5000289
26. Sai Sathikumar, A., Jacob, G., Thomas, A. B., Varghese, J., & Menon, V. (2023). Acetabular cup positioning in primary routine total hip arthroplasty—A review of current concepts and technologies. *Arthroplasty, 5*(1), 59. https://doi.org/10.1186/s42836-023-00213-3
27. Otero, J. E., Fehring, K. A., Martin, J. R., Odum, S. M., & Fehring, T. K. (2018). Variability of pelvic orientation in the lateral decubitus position: Are external alignment guides trustworthy? *The Journal of Arthroplasty, 33*(11), 3496–3501. https://doi.org/10.1016/j.arth.2018.07.021
28. Vigdorchik, J. M., Sculco, P. K., Inglis, A. E., Schwarzkopf, R., & Muir, J. M. (2021). Evaluating alternate registration planes for imageless, computer-assisted navigation during total hip arthroplasty. *The Journal of Arthroplasty, 36*(10), 3527–3533. https://doi.org/10.1016/j.arth.2021.05.037
29. Meermans, G., Van Doorn, W. J., Koenraadt, K., & Kats, J. (2014). The use of the transverse acetabular ligament for determining the orientation of the components in total hip replacement: A randomised controlled trial. *The Bone & Joint Journal, 96-B*(3), 312–318. https://doi.org/10.1302/0301-620X.96B3.32989
30. Yoon, B.-H., Ha, Y.-C., Lee, Y.-K., Jo, W.-L., Lee, K.-M., & Koo, K.-H. (2016). Is transverse acetabular ligament a reliable guide for aligning cup anteversion in total hip arthroplasty?: A measurement by CT arthrography in 90 hips. *Journal of Orthopaedic Science, 21*(2), 199–204. https://doi.org/10.1016/j.jos.2015.11.007
31. Gosthe, R. G., Suarez, J. C., McNamara, C. A., Calvo, C., & Patel, P. D. (2017). Fluoroscopically guided acetabular component positioning: Does it reduce the risk of malpositioning in obese patients? *The Journal of Arthroplasty, 32*(10), 3052–3055. https://doi.org/10.1016/j.arth.2017.04.045
32. Kayani, B., Konan, S., Ayuob, A., Ayyad, S., & Haddad, F. S. (2019). The current role of robotics in total hip arthroplasty. *EFORT Open Reviews, 4*(11), 618–625. https://doi.org/10.1302/2058-5241.4.180088
33. Ha, Y., Yoo, J., Lee, Y., Kim, J., & Koo, K. (2012). Acetabular component positioning using anatomic landmarks of the acetabulum. *Clinical Orthopaedics and Related Research, 470*(12), 3515–3523. https://doi.org/10.1007/s11999-012-2460-y
34. Buchan, G., Hecht, C., Liu, D., Mokete, L., Kendoff, D., & Kamath, A. (2023). Improved accuracy of a novel fluoroscopy-based robotically assisted THA system compared to manual THA. *Journal of Robotic Surgery, 17*(5), 2073–2079. https://doi.org/10.1007/s11701-023-01623-w
35. Kunze, K., Huddleston, H., Romero, J., Chiu, Y., Jerabek, S., & McLawhorn, A. (2022). Accuracy and precision of acetabular component position does not differ between the anterior and posterior approaches to total hip arthroplasty with robotic assistance: A matched-pair analysis. *Arthroplasty Today, 18*, 68–75. https://doi.org/10.1016/j.artd.2022.08.004
36. Incesoy, M. A., Yildiz, F., Pulatkan, M. A., Yesiller, O. F., Toluk, O., Erdem, A. C., & Tuncay, I. (2023). CT-based, robotic-arm assisted total hip arthroplasty (Mako) through anterior approach provides improved cup placement accuracy but no difference in clinical outcomes when compared to conventional technique. *Technology and Health Care*. https://doi.org/10.3233/THC-231111
37. Kelley, S. S., Lachiewicz, P. F., Hickman, J. M., & Paterno, S. M. (1998). Relationship of femoral head and acetabular size to the prevalence of dislocation. *Clinical Orthopaedics and Related Research, 355*, 163–170. https://doi.org/10.1097/00003086-199810000-00017
38. Bosker, B. H., Verheyen, C. C. P. M., Horstmann, W. G., & Tulp, N. J. A. (2007). Poor accuracy of freehand cup positioning during total hip arthroplasty. *Archives of Orthopaedic and Trauma Surgery, 127*(5), 375–379. https://doi.org/10.1007/s00402-007-0294-y
39. Beverland, D. E., O'Neill, C. K. J., Rutherford, M., Molloy, D., & Hill, J. C. (2016). Placement of the acetabular component. *The Bone & Joint Journal, 98-B*(1 Suppl A), 37–43. https://doi.org/10.1302/0301-620X.98B1.36343
40. Hill, J. C., Gibson, D. P., Pagoti, R., & Beverland, D. E. (2010). Photographic measurement of the inclination of the acetabular component in total hip replacement using the posterior approach. *The Journal of Bone and Joint Surgery. British Volume, 92*(9), 1209–1214. https://doi.org/10.1302/0301-620X.92B9.24476
41. Kong, X., Yang, M., Jerabek, S., Zhang, G., Chen, J., & Chai, W. (2020). A retrospective study comparing a single surgeon's experience on manual versus robot-assisted total hip arthroplasty after the learning curve of the latter procedure—A cohort study. *International Journal of Surgery, 77*, 174–180. https://doi.org/10.1016/j.ijsu.2020.03.067

Publisher's Note Springer Nature remains neutral with regard to jurisdictional claims in published maps and institutional affiliations.

Springer Nature or its licensor (e.g. a society or other partner) holds exclusive rights to this article under a publishing agreement with the author(s) or other rightsholder(s); author self-archiving of the accepted manuscript version of this article is solely governed by the terms of such publishing agreement and applicable law.