

## Foldable iris-fixated phakic intraocular lens implantation for the correction of myopia: Two years of follow-up

Yusuf Ozertürk, Anil Kubaloglu, Esin Sogutlu Sari, Arif Koytak<sup>1</sup>, Musa Capkin, Levent Akçay, Pinar Sorgun Evcili

**Purpose:** To evaluate the safety, efficacy and potential risks of Artiflex foldable iris-fixated phakic intraocular lens (pIOL) implantation for the management of myopia. **Materials and Methods:** Seventy-eight eyes of 40 consecutive patients with a mean spherical refraction of  $-11.70 \pm 3.77$  diopters (D; range  $-5.50$  to  $-17.5$  D) were included in this prospective, noncomparative, interventional case series. Main parameters assessed were uncorrected visual acuity (UCVA), best-spectacle corrected visual acuity (BSCVA), corneal topography (Orbscan II, BauchandLomb, Rochester, NY, USA), manifest and cycloplegic refractive errors, endothelial cell density (ECD) and applanation tonometry. **Results:** After 2 years, BSCVA was 20/40 or better in 82% of the eyes and UCVA was 20/40 or better in 84% of the eyes. After 1 month, 1 year, and 2 years, 51.3% (37 of 72 eyes), 58.9% (46 of 78 eyes) and 76.0% (38 of 50 eyes) of eyes gained 1 line or more of BSCVA, respectively. Compared to preoperative values, the mean endothelial cell loss was 2.6% at 1 month, 4.9% at 1 year and 7.4% at 2 years. Pigmented or non-pigmented precipitates were observed in 17 eyes (21.7%) which were treated with topical corticosteroids. At the second postoperative year, pigmented precipitates persisted in nine eyes. However, this was not associated with a loss of BSCVA. **Conclusion:** The implantation of Artiflex pIOL is an effective surgical option for the management of high myopia. The most common complication observed within 2 years of follow-up was accumulation of pigmented precipitates with no effect on the final BSCVA.

**Key words:** Myopia, phakic refractive intraocular lens, refractive surgery

Refractive surgery techniques including corneal ablation [e.g., laser-assisted *in situ* keratomileusis (LASIK), photorefractive keratectomy] and phakic intraocular lens (pIOL) implantation aim to correct spherical and cylindrical refractive errors in myopic patients dissatisfied with the quality of vision provided by spectacles and contact lenses.<sup>[1,2]</sup> LASIK has gained popularity as a relatively safe and effective surgical method for the correction of myopia. However, as they have a potential risk of subsequent keratectasia, patients with high myopia or thin corneas are subject to some restrictions for LASIK surgery.<sup>[3-5]</sup> Moreover, a high amount of laser ablation may lead to deterioration of superior intrinsic corneal optical performance.<sup>[4,5]</sup>

Currently, pIOLs are offering a promising alternative for the management of moderate to high myopia.<sup>[6,7]</sup> Several lens designs have been developed for this purpose, including angle-supported pIOLs, posterior chamber pIOLs, and iris-fixated pIOLs.<sup>[2,8,9]</sup> In 1986, Worst *et al.* first designed a negatively biconcave iris-fixated pIOL to correct high myopia. This lens design was then modified into a convex-concave shape known as the Worst myopia claw lens. Since then, the rigid polymethyl methacrylate (PMMA) model (Artisan, Ophtec, Groningen, The Netherlands; Verisyse, AMO, Santa Ana, CA, USA) has received Food and Drug Administration approval in the United States

in 2004 and several published studies have demonstrated the efficacy of Artisan pIOLs.<sup>[10-12]</sup>

Modern refractive surgery with a sutureless, small corneal incision provides less corneal distortion, less postoperative inflammation, lower postoperative astigmatism and faster visual rehabilitation, allowing patients to return to their daily lives within a shorter time. The Artiflex pIOL (Ophtec BV, Groningen, The Netherlands) is a foldable version of the Artisan pIOL with a similar convex-concave lens design and has two opposed haptics to enable fixation on the midperipheral iris. This foldable Artiflex pIOL has the advantage over PMMA Artisan pIOL in that it can be inserted through a sutureless, small corneal incision. The safety and efficacy of the Artiflex pIOL was recently demonstrated by a multicenter international clinical trial.<sup>[13]</sup> In this prospective study, we evaluated the visual and refractive results, the effects on corneal endothelium and intraocular pressure (IOP), as well as the surgical complications of Artiflex pIOL implantation for the management of myopia.

### Materials and Methods

Seventy-eight eyes of 40 consecutive patients who underwent Artiflex pIOL implantation for the treatment of myopia between March 2006 and December 2007 were included in this prospective, noncomparative, interventional case series. Inclusion criteria were patient age of 18 or more, stable refraction for at least a year, lack of patient satisfaction with the correction provided by spectacles or contact lenses, an anterior chamber depth (ACD) more than 2.9 mm, mesopic pupil size less than 7.0 mm, endothelial cell count more than 2000 cells/mm<sup>2</sup>, normal iris and pupil configuration, no history of glaucoma and retinal detachment, retinal tear or hole. Patients who had a simultaneous or consecutive additional

#### Access this article online

##### Website:

www.ijo.in

##### DOI:

10.4103/0301-4738.91340

#### Quick Response Code:



Kartal Training and Research Hospital, Istanbul, <sup>1</sup>Department of Ophthalmology, Bezmialem University, Istanbul, Turkey

**Correspondence to:** Dr. Esin Sogutlu Sari, Bulgurlu mah., Baglar cad., Detay 2 sit., E blok, D:10, Istanbul, Turkey. E-mail: dresinsogutlu@hotmail.com

**Manuscript received:** 04.01.11; **Revision accepted:** 10.09.11

refractive surgical procedure were excluded. All patients were verbally informed about the procedure, its advantages and disadvantages. A written informed consent was obtained from all patients in accordance with the Declaration of Helsinki. The study was approved by the local ethics committee of Kartal Training and Research Hospital, Istanbul.

Eyes were examined before the surgery and at 1 day, 1 week, 1 month, 3 months, 6 months, 12 months and 24 months after the surgery, including uncorrected visual acuity (UCVA), best-spectacle corrected visual acuity (BSCVA), corneal topography (Orbscan II, BauchandLomb, Rochester, NY, USA), manifest and cycloplegic refraction to calculate the spherical equivalent (SE), endothelial cell density (ECD), slit-lamp examination, applanation tonometry and indirect ophthalmoscopy. UCVA and BSCVA were measured in decimal Snellen and converted to the logarithm of the minimum angle of resolution (logMAR) for statistical analysis. Corneal endothelium was photographed and evaluated using a Topcon SP 2000P noncontact specular microscope (Topcon Corp., Tokyo, Japan) and images of the central corneal window were reviewed by the same observer (E.S.). At each visit, four photographs were obtained and analyzed for this purpose. The mean of these readings was recorded for the each visit.

Intraocular lens power calculation was performed by (Ophtec, Groningen, The Netherlands) using van der Heijde formula, which employs the mean corneal curvature, adjusted ACD, and manifest SE of the subjective refractive error at a vertex distance of 12 mm.

Before the surgery, all eyes received a miotic eye drop (pilocarpine HCl 2%, Pilosed, Bilim Medicine, Istanbul, Turkey) in order to ease lens fixation and reduce the risk of crystalline lens touch during implantation. Surgeries were performed by two experienced ophthalmic surgeons (A.Ku. and L.A.) under topical (proparacaine HCl 0.5%; Alcaine, Alcon Laboratories, Inc., Fort Worth, TX, USA) and intracameral (lidocaine HCl 1%) anesthesia or subtenon anesthesia. A 3.2-mm clear corneal incision was performed at 12 o'clock, and two vertical paracentesis were located at 10 o'clock and 2 o'clock. After an intracameral injection of acetylcholine (Miochol-E, Novartis Pharma AG, Basel, Switzerland) and viscoelastic material (Healon GV, Abbott Medical Optics, Santa Ana, CA, USA), the pIOL was introduced into the anterior chamber using a specially designed implantation device (Operaid Artiflex Implantation Spatula, Ophtec, Groningen, The Netherlands) and thereafter rotated 90° into a horizontal position from 3 o'clock to 9 o'clock. After pIOL positioning, the iris tissue was grasped and enclavated into the haptics with the aid of Operaid Artiflex Enclavation Needle. A peripheral iridotomy was made surgically at 12 o'clock and the viscoelastic material was washed out with balanced salt solution. The watertight self-sealing tunnel incision was left without suture or a safety suture was placed to prevent wound leakage if needed. The surgery was finalized with intracameral injection of 1 mg/0.1 ml of cefuroxime sodium (Zinnat, Glaxo Smithkline, Victoria, Australia). After surgery, all patients received topical lomefloxacin 0.3% (Okacin; Novartis Pharma AG, Basel, Switzerland) and dexamethasone 0.1% (Maxidex, Alcon Laboratories, Inc., Fort Worth, TX, USA) eye drops four times daily for a month.

All data were entered into a spreadsheet and statistical

analyses were performed using SPSS for Windows software (version 11.5, SPSS Inc., Chicago, IL, USA). Preoperative and postoperative mean outcome measurements were compared using paired *t* test (when data were normally distributed) or Wilcoxon signed-rank test (when data were not distributed normally). A two-tailed probability of 5% or less was considered statistically significant.

## Results

Twenty-six female and 14 male patients with a mean age of  $28.7 \pm 7.1$  years (range 19–46 years) were enrolled in this prospective study. All patients completed at least 12 months of follow-up. Preoperative and operative patient data are given in Table 1. Preoperatively, the mean spherical refraction was  $-11.70 \pm 3.77$  diopters (D, range  $-5.50$  to  $-17.50$  D), the mean cylindrical refraction was  $-1.25 \pm 1.11$  D (range  $-4.00$  to  $0.00$  D) and the mean SE was  $-11.85 \pm 4.72$  D (range  $-6.00$  to  $-18.00$  D). The mean ACD was  $3.41 \pm 0.33$  mm (range 2.90–4.15 mm) and the mean refractive power of pIOL was  $-11.28 \pm 3.42$  D (range  $-6.00$  D to  $-14.50$  D).

## Safety

The mean preoperative logMAR BSCVA was  $0.25 \pm 0.21$  (range 0–1). The mean BSCVA was  $0.17 \pm 0.16$  (range  $-0.1$  to  $0.5$ ,  $P < 0.05$ ) at the first month,  $0.16 \pm 0.17$  (range  $-0.1$  to  $0.5$ ,  $P < 0.05$ ) at the first year and  $0.15 \pm 0.18$  (range  $-0.1$  to  $0.7$ ,  $P < 0.05$ ) at the second year after the operation. At the end of the second year, BSCVA was decreased 2 or more lines in two eyes (2.5%). After 1 month, 1 year, and 2 years, 51.3% (37 of 72 eyes), 58.9% (46 of 78 eyes) and 76.0% (38 of 50 eyes) of eyes gained 1 line or more of BSCVA, respectively. BSCVA was 20/40 or better in 81%, 75% and 82% of the eyes at the first month, and at the first and second years, respectively [Fig. 1]. The safety index (the ratio of mean postoperative Snellen BSCVA to mean preoperative Snellen BSCVA) was 1.03 ( $n = 72$ ), 1.10 ( $n = 78$ ) and 1.12 ( $n = 50$ ) after 1 month, 1 year and 2 years, respectively.

## Efficacy

The mean preoperative logMAR UCVA of  $1.36 \pm 0.41$  (range 0.7–2) was improved to  $0.28 \pm 0.27$  (range  $-0.1$  to  $1$ ,  $P < 0.001$ ) after 2 years. UCVA was 20/40 or better in 77%, 73% and 84%

**Table 1: Preoperative and operative data of the patients who underwent Artiflex phakic intraocular lens implantation (Ophtec BV, Groningen, The Netherlands)**

Parameters	
Patient/eye (n)	40/78
Age (years)	$28.7 \pm 8.1$
Male/female (n)	14/26
UCVA (logMAR)	$1.36 \pm 0.41$
BSCVA (logMAR)	$0.25 \pm 0.21$
SE (D)	$-11.8 \pm 4.7$
ECD (cells/mm <sup>2</sup> )	$3023 \pm 422$
ACD (mm)	$3.4 \pm 0.3$
pIOL power (D)	$-11.2 \pm 3.4$

LogMAR: Logarithm of the minimum angle of resolution, UCVA: Uncorrected visual acuity, BSCVA: Best-spectacle corrected visual acuity, SE: Spherical equivalent, ECD: Endothelial cell density, ACD: Anterior chamber depth, pIOL: Phakic intraocular lens, D: Diopters

of eyes after 1 month, 1 year and 2 years, respectively [Fig. 2]. The efficacy index (the ratio of mean postoperative Snellen UCVA to the mean preoperative Snellen BSCVA) was 0.68 (n = 72), 0.77 (n = 78) and 0.79 (n = 50) at the first month, and at the first and second years, respectively.

**Predictability**

The deviation of the achieved SE correction from the desired refractive SE correction was calculated. At the first month, 69.4% (50 of 72 eyes) of the eyes were within  $\pm 0.5$  D of the desired refraction, while 84.7% (61 of 78 eyes) and 90% (45 of 50 eyes) of the eyes were within that range at the first and second years, respectively. After 1 month, 1 year and 2 years, 90.2% (65 of 72 eyes), 92.3% (72 of 78 eyes) and 88% (44 of 50 eyes) of the eyes were within  $\pm 1.0$  D of the desired refraction, respectively. After 2 years, 96% (48 of 50 eyes) of the eyes were within 2.0 D of the desired refraction [Fig. 3].

**Stability**

The mean preoperative SE was  $-11.85 \pm 4.72$  D. The mean SE

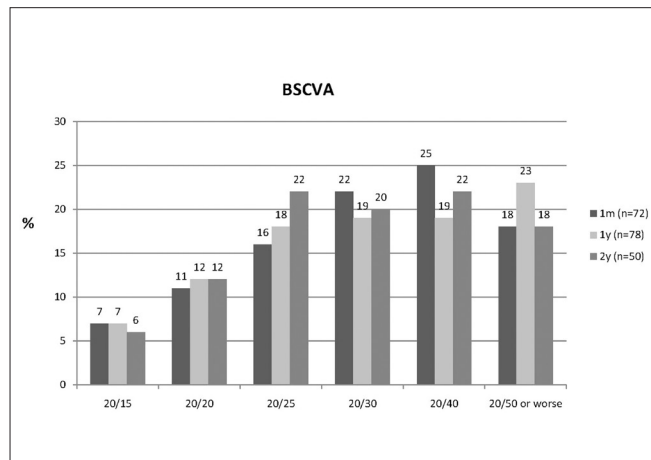
improved to  $-0.73 \pm 0.82$  D (range  $-2.50$  to  $1.00$  D) after 1 month, to  $-0.94 \pm 0.78$  (range  $-2.50$  to  $1.00$  D) after 1 year, and to  $-1.04 \pm 0.75$  D (range  $-2.50$  to  $0.50$  D) after 2 years. No significant difference was found between mean SE values of the first month and the first year, and the mean SE values of the first and the second years ( $P > 0.05$ ) [Fig. 4].

**Endothelial cell density**

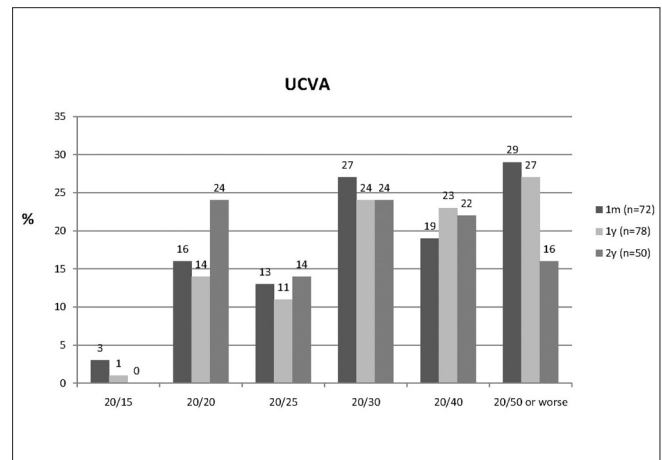
The mean preoperative ECD was  $3023 \pm 422$  cells/mm<sup>2</sup> (range 2300–4220 cells/mm<sup>2</sup>). A month after surgery, the mean ECD was  $2944 \pm 434$  cells/mm<sup>2</sup> (range 1745–4108 cells/mm<sup>2</sup>; n = 72). At the first and second year visits, the mean ECD was  $2872 \pm 353$  cells/mm<sup>2</sup> (range 1645–4012 cells/mm<sup>2</sup>; n = 78) and  $2797 \pm 457$  cells/mm<sup>2</sup> (range 1612–3998 cells/mm<sup>2</sup>; n = 50), respectively. The mean endothelial cell loss after 1 month, 1 year and 2 years was 2.6% (n = 72), 4.9% (n = 78) and 7.4% (n = 50), respectively. Fig. 5 shows the mean ECD before and after the surgery.

**Complications**

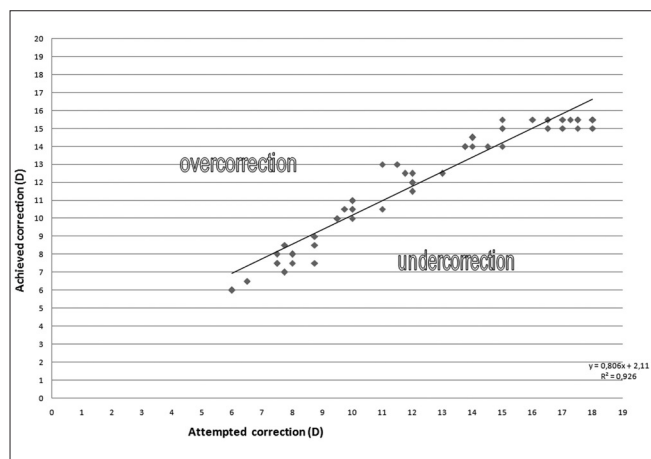
There were no intraoperative complications. IOP was found



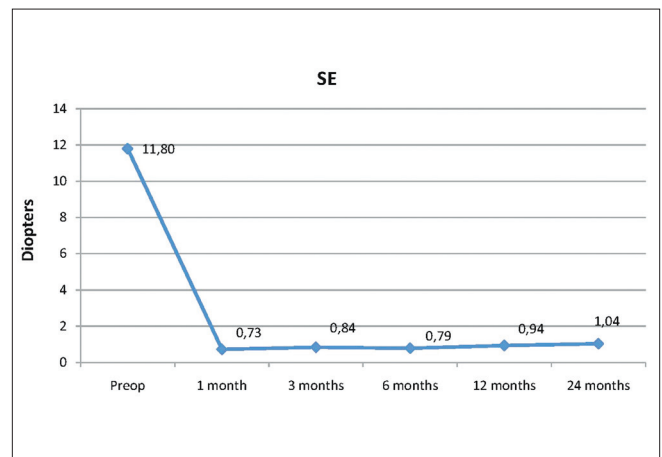
**Figure 1:** Bar graph showing the best-spectacle corrected visual acuity at 1 month (m), 1 year (y) and 2 years after Artiflex phakic intraocular lens implantation (Ophtec BV, Groningen, The Netherlands)



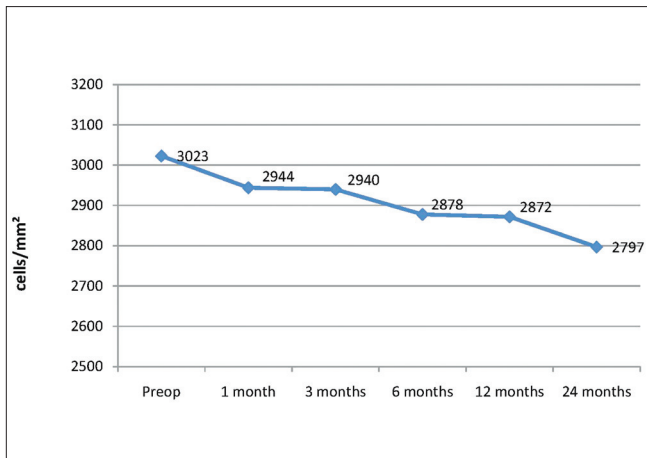
**Figure 2:** Bar graph showing the uncorrected visual acuity at 1 month (m), 1 year (y) and 2 years after Artiflex phakic intraocular lens implantation (Ophtec BV, Groningen, The Netherlands)



**Figure 3:** Scatterplot demonstrating the spread of achieved against intended correction in spherical equivalent 2 years after Artiflex phakic intraocular lens implantation (Ophtec BV, Groningen, The Netherlands)



**Figure 4:** Bar graph showing the spherical equivalent refractive error preoperatively and at 1 month (m), 3 months, 6 months, 1 year (y) and 2 years after Artiflex phakic intraocular lens implantation (Ophtec BV, Groningen, The Netherlands)



**Figure 5:** Bar graph showing the endothelial cell density preoperatively and at 1 month (m), 3 months, 6 months, 1 year (y) and 2 years after Artiflex phakic intraocular lens implantation (Ophtec BV, Groningen, The Netherlands)

to be increased in two eyes, 1 and 3 months after the surgery. Both eyes responded well to topical antiglaucoma drops. After 1 year, choroidal neovascular membrane was observed in one eye. Complications are summarized in Table 2.

In cases of poor pIOL centration and fixation observed intraoperatively, the pIOL was re-enclavated and repositioned for accurate centration. Glare and halos were observed in six eyes (7.6%) of 3 patients. Moderate glare was reported for one eye (1.2%) and mild glare was reported in five eyes (6.4%). Glare and halos were explained by poor centration of the phakic IOL in four eyes and a large scotopic pupil size in two eyes. Non-pigmented deposits on the pIOL surface were observed in eight eyes (10.2%) and pigmented deposits were found in nine eyes (11.5%). These eyes were treated with topical corticosteroid agents, but pigment precipitates persisted in nine eyes. These eyes, however, did not have a loss of visual acuity.

## Discussion

Phakic IOLs are able to correct high levels of myopia and hyperopia, and provide immediate improvement in visual acuity while preserving the accommodation.<sup>[14]</sup> The implantation of iris-fixated pIOLs has been shown to be an effective surgical option for the treatment of refractive errors, offering an optical quality claimed to be superior to that of corneal refractive surgeries.<sup>[15-17]</sup> The efficacy and safety of the Artisan iris-claw lens has been demonstrated in several multicenter studies.<sup>[9,16,18,19]</sup> However, a 6.2-mm corneal incision was needed for the implantation of the Artisan iris-claw lens made of rigid PMMA material. The Artiflex lens has been developed based on the Artisan concept, with the haptics and optic almost identical to the conventional Artisan myopia lens. The added value of the flexible Artiflex over the Artisan is that it can be inserted through a 3.2-mm small corneal incision. In this study, we evaluated the effectiveness, predictability, and potential risks of the implantation of Artiflex foldable iris-fixated phakic IOLs for the management of myopia.

Efficacy and predictability of the iris-fixated lenses by using the rigid PMMA model have been previously reported. In their study comprising 264 phakic eyes, Alexander *et al.*<sup>[17]</sup> reported

**Table 2: Complications after Artiflex phakic intraocular lens implantation (Ophtec BV, Groningen, The Netherlands)**

	n	%
Increament of intraocular pressure	2	2.5
Choroidal neovascular membran	1	1.2
Pigment and nonpigment cells	17	21.7
Glare and halos	6	7.6

a significant improvement of BCVA with 100% of patients achieving 20/40 or better, 72% gaining 1 or more lines while 22% gaining 2 or more lines. When considering predictability, in the European multicenter study<sup>[18]</sup> with Artisan lenses, 57.1% of the eyes were within  $\pm 0.5$  D of the intended correction and 78.8% were within  $\pm 1.0$  D after 3 years. Similarly, in the Food and Drug Administration study,<sup>[16]</sup> 55% of the eyes were within  $\pm 0.5$  D of the intended correction and 76% of the eyes were within  $\pm 1.0$  D after 6 months. In 2005, Tehrani and Dick<sup>[15]</sup> reported the first clinical study describing the performance of a foldable iris-fixated lens for the correction of myopia in phakic eyes. Their results demonstrated that this lens is a predictable, stable, and efficient option for the correction of myopia. In their study, UCVA was improved in all eyes at the sixth month and 76% of the eyes gained 1 or 2 lines of BSCVA. Successful visual outcomes of Artiflex pIOL implantation were also reported 4 years later, in the European multicenter study<sup>[13]</sup> in which 75.2% of the eyes were within  $\pm 0.5$  D of the desired correction and 94.3% of the eyes were within  $\pm 1.0$  D after 2 years. In the present study, we concluded that the implantation of the foldable iris-fixated Artiflex intraocular lens corrected high myopia with a high degree of predictability and stability, and provided improvement in both UCVA and BSCVA after a 2-year follow-up period. UCVA and BSCVA were 20/40 or better in 84% and 82% of the eyes, respectively. The predictability of the procedure was found satisfactory, with 90% of the treated eyes within  $\pm 0.50$  of the desired correction and 88% of the eyes within  $\pm 1.00$  D of the desired correction.

Damage to the anterior chamber structures, particularly to the corneal endothelium, has been a major concern about anterior chamber intraocular lenses. It is a well-known phenomenon that the ECD decreases with age. Additionally, a shallow anterior chamber, extensive eye rubbing, or IOL dislocation resulting from inadequate iris enclavation are among several factors that may cause significant endothelial cell loss in eyes with iris-fixated pIOL.<sup>[20]</sup> Progressive endothelial damage may be associated with potential mechanical contacts between the pIOL and corneal endothelium. Several studies have reported short- and long-term complications related to these lenses. Tahzib *et al.*<sup>[21]</sup> found that there was no long-term corneal endothelial cell loss over time. On the contrary, their study group showed a relative increase in ECD, 1 year and 10 years after the procedure. Pop and Payette<sup>[10]</sup> have not observed a decline in ECD in 765 eyes up to 2 years following implantation of the Artisan myopia lens. On the other hand, Landesz *et al.*<sup>[22]</sup> reported a progressive endothelial cell loss of 5.5% at 6 months, 7.21% at 12 months, and 9.1% at 2 years after surgery. Similarly, Saxena *et al.*<sup>[23]</sup> showed a significant drop in ECD after 3 years and a significant negative correlation between endothelial cell loss and ACD. Based on this finding, they recommend caution while operating on young patients

who narrowly meet the inclusion criteria for ACD and ECDs. Also, Tehrani<sup>[15]</sup> advocates the injection of a bolus of a high-viscosity ophthalmic viscosurgical device while inserting the lens into the anterior chamber and before enclavation, in order to ensure added protection to the endothelium. Although the foldable feature of the Artiflex lens with a potentially mobile optic may decrease the tolerance of the endothelium, Couillet *et al.*<sup>[24]</sup> have found no differences in central endothelial cell densities after 1 year in Artisan- and Artiflex-treated eyes. Also, using Scheimpflug photography, Kohnen<sup>[25]</sup> demonstrated that the Artiflex lens has a significantly greater distance to the endothelium than the Artisan lens, possibly providing better safety against endothelial cell loss. In the multicenter European study with Artiflex lenses, the mean endothelial cell loss was 0.05%, 1.79%, and 1.07% at 6 months, 1 year and 2 years, respectively. However, another study showed a slight loss of endothelial cells (2.3%), 6 months after Artiflex pIOL implantation. In the present study, mean postoperative endothelial cell losses were found to be 2.6% at the first month, 4.9% at the first year and 7.4% at the second year. Further investigations with longer follow-up are needed to evaluate the tolerance of the endothelium against Artiflex in the long term.

Although multiple factors influence the complication profile of pIOLs, the majority of complications are attributable to the design and position of the pIOL. Iris-fixated pIOLs have been associated with several surgical complications such as elevation of IOP, cataracts, pigment deposits, pupil ovalization and chronic anterior segment inflammation.<sup>[20]</sup> In this study, elevation of IOP was observed in three eyes, all of which have responded well to topical antiglaucoma drops. Glaucoma may be related to the design of pIOL or elevation of IOP may be associated with chronic anterior segment inflammation caused by iris-fixated pIOLs. Also, myopes, in particular, are prone to the development of different types of chronic open-angle glaucoma.<sup>[26]</sup>

The silicon optic material that is used in Artiflex might be increasing the incidence of pigment deposits postoperatively.<sup>[13]</sup> Recent studies investigated pigment dispersion and chronic inflammatory reactions related to the Artisan pIOL and the authors suggested that these reactions may be due to an abnormal pressure on the iris which is sandwiched between the crystalline lens and the pIOL.<sup>[27,28]</sup> Another study<sup>[29]</sup> hypothesized that the decreased vault between the optic-haptic junction of the lens and the iris plane may result in mechanical irritation of the iris tissue during pupillary constriction. Short-term usage of topical corticosteroids was recommended in order to decrease the incidence of precipitates. Also, some authors used an intraoperative subconjunctival corticosteroid depot injection.<sup>[13]</sup> In the present study, non-pigmented or pigmented precipitates were observed in 17 eyes. All were treated with topical corticosteroid agents. In the second postoperative year, the pigment dispersion was still present in nine eyes; however, none of these eyes had a loss of visual acuity caused by this. Close and frequent contact between Artiflex lens and the iris tissue may be the cause of pigment dispersion. In order to minimize the risk, the surgeon should eliminate unnecessary manipulations within the eye during the implantation procedure and avoid excessive enclavation of the iris tissue to the claws of the pIOL.

In this study, we conclude that the implantation of the

Artiflex pIOL is an effective surgical option for the management of high myopia. Complications occur, but uncommonly lead to a loss of BSCVA. Further long-term studies are needed, however, to evaluate the safety profile of this pIOL.

## References

1. Pesudovs K, Garamendi E, Elliott DB. A quality of life comparison of people wearing spectacles or contact lenses or having undergone refractive surgery. *J Refract Surg* 2006;22:19-7.
2. Alió JL, de la Hoz F, Pérez-Santonja JJ, Ruiz-Moreno JM, Quesada JA. Phakic anterior chamber lenses for the correction of myopia: A 7-year cumulative analysis of complications in 263 cases. *Ophthalmology* 1999;106:458-66.
3. Seiler T, Koufala K, Richter G. Iatrogenic keratectasia after laser *in situ* keratomileusis. *J Refract Surg* 1998;14:312-7.
4. Stulting RD, Carr JD, Thompson KP, Waring GO 3rd, Wiley WM, Walker JG. Complications of laser *in situ* keratomileusis for the correction of myopia. *Ophthalmology* 1999;106:13-20.
5. Malecaze FJ, Hulin H, Bierer P, Fournié P, Grandjean H, Thalamas C, *et al.* A randomized paired eye comparison of two techniques for treating moderately high myopia: LASIK and Artisan phakic lens. *Ophthalmology* 2002;109:1622-30.
6. Perez-Santonja JJ, Bueno JL, Zato MA. Surgical correction of high myopia in phakic eyes with Worst-Fechner myopia intraocular lenses. *J Refract Surg* 1997;13:268-81; discussion 281-4.
7. Senthil S, Reddy KP, Ravisankar, Srilakshmi. A retrospective analysis of the first Indian experience on Artisan phakic intraocular lens. *Indian J Ophthalmol* 2006;54:251-5.
8. Dejaco-Ruhswurm I, Scholz U, Pieh S, Hanselmayer G, Lackner B, Italon C, *et al.* Long-term endothelial changes in phakic eyes with posterior chamber intraocular lenses. *J Cataract Refract Surg* 2002;28:1589-93.
9. Fechner PU, Strobel J, Wichmann W. Correction of myopia by implantation of a concave Worst-iris claw lens into phakic eyes. *Refract Corneal Surg* 1991;7:286-98.
10. Pop M, Payette Y. Initial results of endothelial cell counts after Artisan lens for phakic eyes: An evaluation of the United States Food and Drug Administration Ophtec Study. *Ophthalmology* 2004;111:309-17.
11. Guell JL, Vazquez M, Gris O. Adjustable refractive surgery: 6-mm Artisan lens plus laser *in situ* keratomileusis for the correction of high myopia. *Ophthalmology* 2001;108:945-52.
12. el Danasoury MA, el Maghraby A, Gamali TO. Comparison of iris-fixed Artisan lens implantation with Excimer laser *in situ* keratomileusis in correcting myopia between -9.00 and -19.50 diopters: A randomized study. *Ophthalmology* 2002;109:955-64.
13. Dick HB, Budo C, Malecaze F, Güell JL, Marinho AA, Nuijts RM, *et al.* Foldable Artiflex phakic intraocular lens for the correction of myopia: Two-year follow-up results of a prospective European multicenter study. *Ophthalmology* 2009;116:671-7.
14. Kohnen T. Searching for the perfect phakic intraocular lens. *J Cataract Refract Surg* 2000;26:1261-2.
15. Tehrani M, Dick HB. Short-term follow-up after implantation of a foldable iris-fixated intraocular lens in phakic eyes. *Ophthalmology* 2005;112:2189-95.
16. Maloney RK, Nguyen LH, John ME. Artisan phakic intraocular lens for myopia: Short-term results of a prospective, multicenter study: The Artisan Lens Study Group. *Ophthalmology* 2002;109:1631-41.
17. Alexander L, John M, Cobb L, Noblitt R, Barowsky RT. US clinical investigation of the Artisan myopia lens for the correction of high myopia in phakic eyes: Report of the results of phases 1 and 2, and interim phase 3. *Optometry* 2000;71:630-42.
18. Budo C, Hessloehl JC, Izak M, Luyten GP, Menezo JL, Sener BA,

- et al.* Multicenter study of the Artisan phakic intraocular lens. *J Cataract Refract Surg* 2000;26:1163-71.
19. Dick HB, Alió J, Bianchetti M, Budo C, Christiaans BJ, El-Danasoury MA, *et al.* Toric phakic intraocular lens: European multicenter study. *Ophthalmology* 2003;110:150-62.
  20. Dick HB, Tehrani M. Phakic intraocular lenses: Current status and limitations [in German]. *Ophthalmologie* 2004;101:232-45.
  21. Tahzib NG, Nuijts RM, Wu WY, Budo CJ. Long-term study of Artisan phakic intraocular lens implantation for the correction of moderate to high myopia: Ten-year follow-up results. *Ophthalmology* 2007;114:1133-42.
  22. Landes M, van Rij G, Luyten G. Iris-claw phakic intraocular lens for high myopia. *J Refract Surg* 2001;17:634-40.
  23. Saxena R, Boekhoorn SS, Mulder PG, Noordzij B, van Rij G, Luyten GP. Long-term follow-up of endothelial cell change after Artisan phakic intraocular lens implantation. *Ophthalmology* 2008;115:608-13.
  24. Couillet J, Guëll JL, Fournié P, Grandjean H, Gaytan J, Arné JL, *et al.* Iris-supported phakic lenses (rigid vs foldable version) for treating moderately high myopia: Randomized paired eye comparison. *Am J Ophthalmol* 2006;142:909-16.
  25. Kohnen T, Cichocki M, Koss MJ. Position of rigid and foldable iris-fixated myopic phakic intraocular lens models evaluated by Scheimpflug photography. *J Cataract Refract Surg* 2008;34:114-20.
  26. Lefrancois A. Myopie forte et glaucome. In: Mondon H, Metge P, eds. *La Myopie Forte*. Paris: De Masson, 1994;27:413-46.
  27. Alió JL, Mulet ME, Shalaby AM. Artisan phakic iris claw intraocular lens for high primary and secondary hyperopia. *J Refract Surg* 2002;18:697-707.
  28. Baïkoff G, Bourgeon G, Jodai HJ, Fontaine A, Lellis FV, Trinquet L. Pigment dispersion and Artisan phakic intraocular lenses: Crystalline lens rise as a safety criterion. *J Cataract Refract Surg* 2005;31:674-80.
  29. Tahzib NG, Eggink FA, Frederik PM, Nuijts RM. Recurrent intraocular inflammation after implantation of the Artiflex phakic intraocular lens for the correction of high myopia. *J Cataract Refract Surg* 2006;32:1388-91.

**Cite this article as:** Ozertürk Y, Kubaloglu A, Sari ES, Koytak A, Capkin M, Akçay L, *et al.* Foldable iris-fixated phakic intraocular lens implantation for the correction of myopia: Two years of follow-up. *Indian J Ophthalmol* 2012;60:23-8.

**Source of Support:** Nil. **Conflict of Interest:** None declared.