

Appearance of Recurrent Cardiac Myxofibrosarcoma on FDG PET/CT

Ezgi Basak Erdoğan, MD,* Sertac Asa, MD,† Sabire Yilmaz Aksoy, MD,† Meftune Ozhan, MD,† and Metin Halac, MD†

Abstract: Primary cardiac sarcomas are extremely rare tumors. In this case report, we presented the condition of a 37-year-old male patient diagnosed with myxofibrosarcoma after histopathologic evaluation of the left atrium mass excision. FDG PET/CT was performed and showed recurrent hyper-metabolic lesions in the left atrial wall and right anterior mediastinal region.

Key Words: cardiac myxofibrosarcoma, FDG, PET/CT

(*Clin Nucl Med* 2014;39: 559–560)

Received for publication July 11, 2013; revision accepted January 28, 2014.

From the *Department of Nuclear Medicine, Bezmialem Vakif University; and †Department of Nuclear Medicine, Istanbul University, Cerrahpasa Medical Faculty, Istanbul, Turkey.

Conflicts of interest and sources of funding: none declared.

Reprints: Ezgi Basak Erdoğan, MD, Department of Nuclear Medicine, Bezmialem Vakif University, Adnan Menderes street, 34093 Fatih Istanbul, Turkey.

E-mail: erdogan_ezgi@yahoo.com.tr.

Copyright © 2014 by Lippincott Williams & Wilkins

ISSN: 0363-9762/14/3906-0559

REFERENCES

- Burke AP, Cowan D, Virmani R. Primary sarcomas of the heart. *Cancer*. 1992;69:387–395.
- Mentzel T, Calonje E, Wadden C, et al. Myxofibrosarcoma. Clinicopathologic analysis of 75 cases with emphasis on the low-grade variant. *Am J Surg Pathol*. 1996;20:391–405.
- Higashiyama S, Kawabe J, Hayashi T, et al. Effectiveness of preoperative PET examination of huge angiosarcoma of the heart. *Clin Nucl Med*. 2009;34:99–102.
- Ak I, Ciftçi OD, Ustünel Z, et al. Atrial angiosarcoma imaged by F-18 FDG PET/CT. *Anadolu Kardiyol Derg*. 2011;11:E17.
- Zhang M, Li B, Jiang X. PET/CT imaging in a case of cardiac liposarcoma. *J Nucl Cardiol*. 2008;15:473–478.
- Makis W, Hickeson M, Derbekyan V. Myeloid sarcoma presenting as an anterior mediastinal mass invading the pericardium: serial imaging with F-18 FDG PET/CT. *Clin Nucl Med*. 2010;35:706–715.
- Babatasi G, Massetti M, Agostini D, et al. Recurrent left-sided heart leiomyosarcoma: should heart transplantation be legitimate? *J Heart Lung Transplant*. 1998;17:1133–1141.
- Goto T, Ohte N, Tani T, et al. Malignant nature of cardiac liposarcoma revealed by fluorine-18 fluorodeoxyglucose positron emission tomographic imaging. *Intern Med*. 2012;51:1367–1370.
- Tan H, Jiang L, Gao Y, et al. ¹⁸F-FDG PET/CT imaging in primary cardiac angiosarcoma: diagnosis and follow-up. *Clin Nucl Med*. 2013;38:1002–1005.
- Gheysens O, Cornillie J, Voigt JU, et al. Left atrial myxoma on FDG-PET/CT. *Clin Nucl Med*. 2013;38:e421–e422.
- Liu Q, Zuo C, Lv T, et al. Pulmonary embolism caused by right atrial myxoma on FDG PET/CT. *Clin Nucl Med*. 2013;38:928–930.
- Lopci E, Monti L, Balzarini L, et al. Cardiac and acoustic metastases in relapsing melanoma. *Clin Nucl Med*. 2013;38:e85–e88.
- Pinnamaneni N, Muthukrishnan A. Left ventricular myocardium metastasis in a patient with primary renal cell carcinoma detected by ¹⁸F-FDG PET/CT. *Clin Nucl Med*. 2012;37:e181–e183.
- Wang Q, Lin SH, Dai D, et al. Primary pericardial osteosarcoma on FDG PET/CT. *Clin Nucl Med*. 2013;38:e326–e328.
- Aga F, Yamamoto Y, Norikane T, et al. A case of primary pericardial mesothelioma detected by ¹⁸F-FDG PET/CT. *Clin Nucl Med*. 2012;37:522–523.
- Dong A, Dong H, Wang Y, et al. (18)F-FDG PET/CT in differentiating acute tuberculous from idiopathic pericarditis: preliminary study. *Clin Nucl Med*. 2013;38:e160–e165.

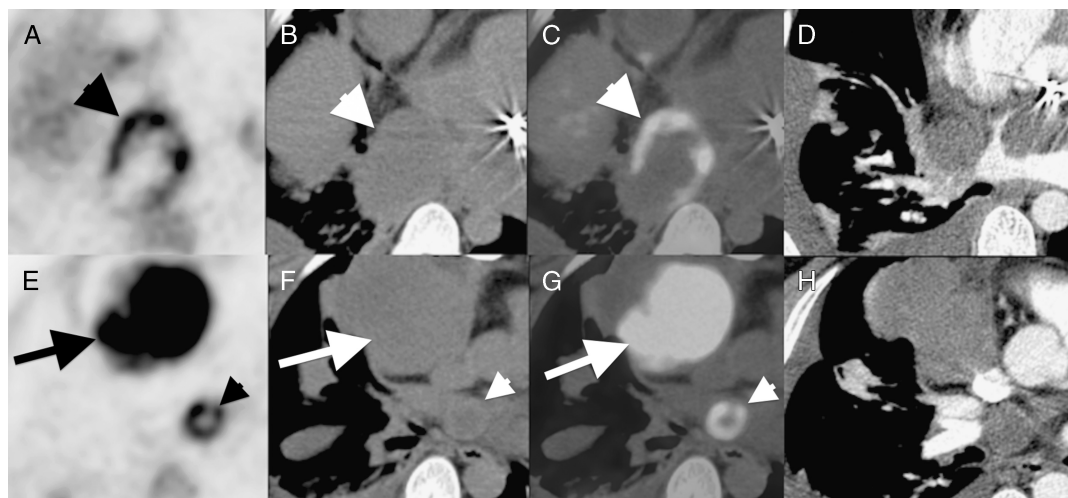


FIGURE 1. The condition of a 37-year-old male patient was diagnosed with myxofibrosarcoma after histopathologic evaluation of the left atrium mass excision, cardiac graft, and mitral valve replacement. The patient's surgical margins were tumor positive, and he refused chemoradiotherapy. The patient presented with dyspnea, cough, and hemoptysis 5 months later. The patient underwent FDG PET/CT for restaging. After a 12-hour fasting period, 17.7 mCi FDG was administered intravenously. Axial PET (A), CT (B), fusion PET/CT (C), and contrast-enhanced CT (D) images demonstrated a mass lesion measuring 5.5×6 cm with heterogeneously intense FDG accumulation (SUV_{max} 12.1), which extends from the inferior vena cava below to the infrahilar region by invading the right atrium (thick arrowhead). In addition, contrast-enhanced CT images (D) demonstrated a mass lesion with 4.5 cm in diameter in the left atrium, and no FDG accumulation at the lumen of the left atrium was seen (A and C), and it was considered as a thrombus (thin arrow). There was also hypermetabolic lesion approximately 2 cm in diameter with heterogeneously increased FDG uptake at the left atrial wall (thin arrowhead) on axial PET (E), CT (F), fusion (G), and contrast-enhanced CT (H) images. In addition, an intensely hypermetabolic mass measuring 7.5×6.5 cm (SUV_{max} 16.8) at the right anterior mediastinal region was noted (thick arrow; E-H).

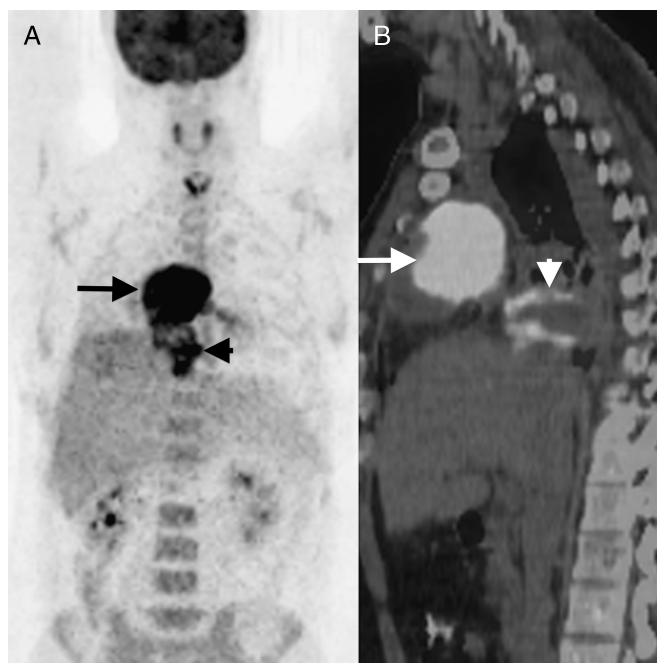

FIGURE 2. Maximum intensity projection PET (A) and sagittal PET/CT fusion (B) images showed recurrent hypermetabolic masses (arrows). Primary cardiac tumors are rare tumors, and approximately 25% of them were malignant. They consist of sarcoma (95%) and lymphoma (5%).¹ The most common primary cardiac sarcomas, which have poor prognosis, are angiosarcoma and rhabdomyosarcoma. Myxofibrosarcomas, which originated from myofibroblast, are nonvascular tumors and considered as myxoid variant of malignant fibrous histiocytoma.² In literature, there are a few case reports about FDG PET imaging of primary cardiac tumors. Mild FDG uptake was reported in benign primary cardiac tumors. Primary and secondary cardiac tumors showed increased FDG uptake.³⁻¹³ In addition, pericardial tumors and pericarditis had increased FDG uptake.¹⁴⁻¹⁶