

## A case of multi-drug-resistant, intracranial tuberculomas, presenting with headache

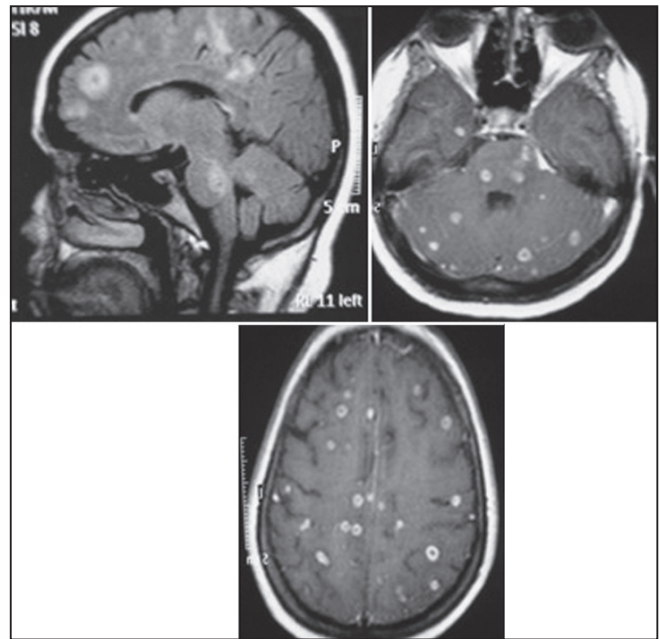
Sir,

We report a rare, multi-drug-resistant case who developed headache initially without systemic symptoms of tuberculosis with multiple intracranial tuberculomas (ICTs). ICT is a rare entity and multi-focal tuberculosis represents 10% of extrapulmonary tuberculosis, with a mortality rate of 16–25% that may rise to 33% in immunocompromised patients.<sup>[1]</sup> In this paper, we aimed to present a case of resistant intracranial tuberculoma, who initially developed headache without any symptoms of tuberculosis and had multiple lesions on brain imaging.

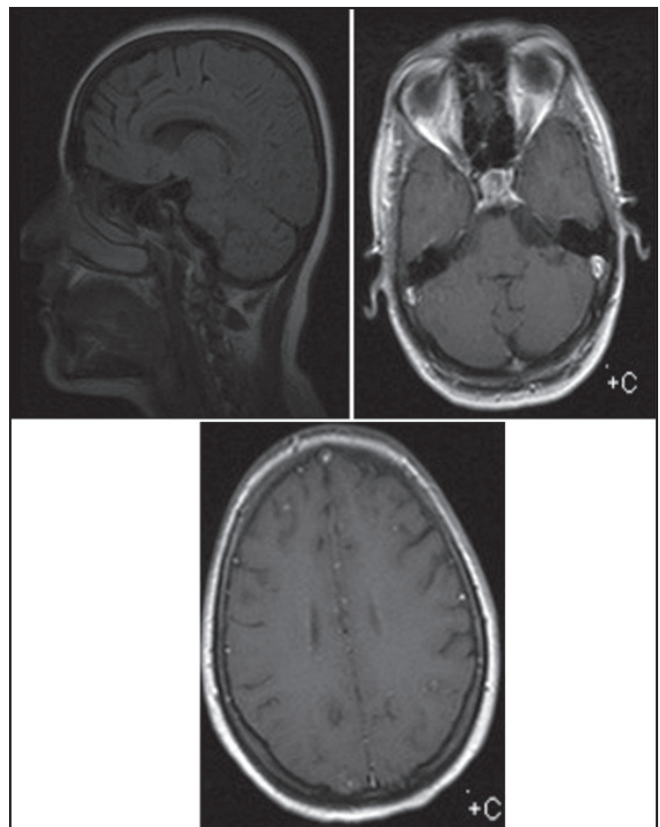
A 26-year-old female patient had presented to a neurologist with headache 2 months ago before she admitted to our clinic, and amitriptyline and analgesic treatment had been initiated for the diagnosis of tension-type headache based on the normal findings in the neurological examination. The patient had not benefited

from the treatment and she developed nausea, weakness, blurred and double vision in addition to the headache. In the direct examination of the cerebrospinal fluid (CSF), 10 erythrocytes were observed and no leukocytes were found. Analysis of CSF revealed the following protein 97 mg/dl, sodium 134 mmol/L, chlorine 125 mmol/L, glucose 48 mg/dl). In the cranial magnetic resonance imaging (MRI), multiple nodular lesions with extensive circular contrast enhancement were observed in the pons, cerebellum, right mesencephalon, basal cisternae, at the level of basal ganglia and in the periventricular white matter areas [Figure 1]. Thoracic tomography revealed suspicious miliary lesions. Thereupon, a sample of fasting gastric juice was obtained and analyzed and staining revealed AFB and after approximately three weeks, *Mycobacterium tuberculosis* grew on the culture. Antibiogram results revealed that it was resistant to isoniazid and rifampicin and susceptible to ethambutol and streptomycin. A quadruple anti-tuberculosis treatment was prescribed consisting of ethambutol, streptomycin, ofloxacin and pyrazinamide. A marked improvement was observed in the neurological symptoms of the patient. Control MRI scans performed at regular intervals after the anti-tuberculosis treatment was completed revealed that after approximately 3 years the ICTs were disappeared [Figure 2].

ICT has a more challenging clinical presentation compared to meningitis. Its clinical diagnosis is more difficult than the clinical diagnosis of other space-occupying lesions. Meningeal irritation findings and headache usually show a slow progression and cranial nerve involvement, neurological deficits, and progressive changes in mental status appear after several weeks.<sup>[2]</sup> Tuberculosis cases with CNS involvement in the absence of immunodeficiency are less common.<sup>[3]</sup> Similarly, in our case, headache was the first symptom and subsequently focal neurological deficit and bilateral papilledema developed, followed by lateral gaze limitation of the right eye. Again, there were no systemic signs of tuberculosis such as fever, weight loss and night sweats and no findings of immunodeficiency. Another feature of our case was that the CSF examinations were normal. Since there are not always bacilli in the CSF, systemic infection findings may be absent and test results may be negative. Therefore, the diagnosis of tuberculosis cannot be completely excluded based on negative test results.<sup>[4]</sup> One of the first important finding in this case was direct smear positivity of AFB in gastric lavage, and the diagnosis of tuberculosis disease was considered according to this result. However false positive results may occur due to the saprophytic AFB. Therefore isolation of AFB in gastric lavage is more precious than positive direct smear.<sup>[5]</sup> In presented case, *M. tuberculosis* yielded in gastric lavage so that the diagnosis was confirmed. Interestingly again we found isoniazid and rifampicin resistance in our case. The number of resistant cerebral tuberculoma cases in the literature is quite low.<sup>[6]</sup> In conclusion, we found this case quite interesting because of its some features. Firstly there are multiple tuberculomas which represent a less common form of intracranial tuberculosis, secondly the initial symptom was only headache without systemic findings of tuberculosis, thirdly the *Mycobacterium tuberculosis* strain was resistant to isoniazid



**Figure 1:** In sagittal and axial cross sections of magnetic resonance imaging, gadolinium revealed multiple, well-defined, ring-enhancing lesions throughout the cerebral hemispheres, cerebellum, and brain stem was observed



**Figure 2:** In magnetic resonance imaging, lesions, as described in Figure 1, were disappeared after 3 years

and rifampicin, fourthly tuberculomas were regressed over a long period of time.

**Vedat Ali Yurekli, Onur Kaya<sup>1</sup>, Fidan Incekara Aydın,  
Hacı Ahmet Bircan<sup>2</sup>, Süleyman Kutluhan,  
Mustafa Kayan<sup>3</sup>, İbak Gonen<sup>1</sup>**

Departments of Neurology, <sup>1</sup>Infectious Diseases and Clinical Microbiology, <sup>2</sup>Chest Diseases and <sup>3</sup>Radiology, Süleyman Demirel University, Isparta, Turkey

**Address for correspondence:**

Vedat Ali Yurekli, Department of Neurology,  
Süleyman Demirel University, Isparta - 322 60, Turkey.  
E-mail: vedatyurekli@yahoo.com

## REFERENCES

1. Suslu HT, Bozbuga M, Bayindir C. Cerebral tuberculoma mimicking high grade glial tumor. *TurkNeurosurg* 2011;21:427-9.
2. Basta M, Lydakakis C, Daskalogiannaki M, Schiza S, Siafakas NM. Multifocal tuberculosis with multiple intracranial tuberculomas in a non-immunocompromised patient. *Respir Med* 2001; 95:841-3.
3. Mazodier K, Bernit E, Faure V, Rovey C, Gayet S, Seux V, *et al.* Central nervous tuberculosis in patients non-VIH: Seven case reports. [Article in French]. *Rev Med Interne* 2003;24:78-85.
4. Sonmez G, Ozturk E, Sildiroglu HO, Mutlu H, Cuce F, Senol MG, *et al.* MRI findings of intracranial tuberculomas. *Clin Imaging* 2008;32:88-92.
5. Rizvi N, Rao NA, Hussain M. Yield of gastric lavage and bronchial wash in pulmonary tuberculosis. *Int J Tuberc Lung Dis* 2000;4:147-51.
6. Lee WY, Ling M, Anderson G, Achawal S, Thaker HK. Isoniazid-resistant intracranial tuberculoma treated with a combination of moxifloxacin and first-line anti-tuberculosis medication. *J Med Microbiol* 2011;60:1550-2.

Access this article online	
Quick Response Code:	Website:
	<a href="http://www.ijpmonline.org">www.ijpmonline.org</a>
	DOI:
	<a href="https://doi.org/10.4103/0377-4929.125407">10.4103/0377-4929.125407</a>