

Our Experience with a Double-Layer Surgical Technique for Preventing Fistula Development in Children and Young Adults with Hypospadias

Aslan Demir Mert Ali Karadağ Kürşat Çeçen Mehmet Uslu Ömer Erkam Arslan

Kafkas University, School of Medicine, Urology Department, Kars, Turkey

Key Words

Hypospadias · Double-layer · Fistula prevention

Abstract

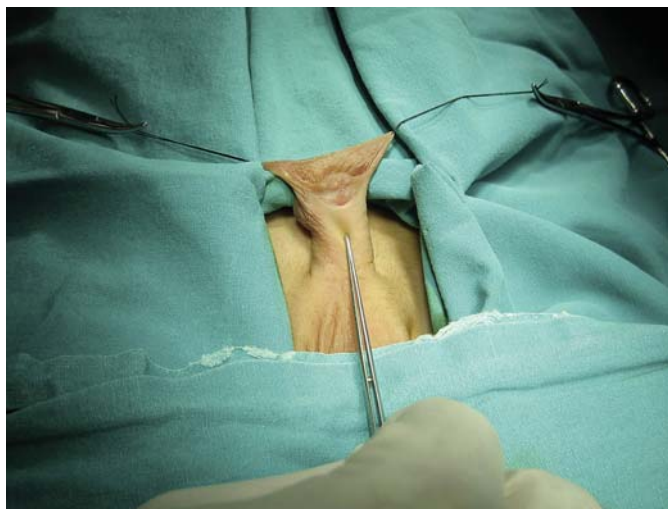Introduction: In this study, we describe a new approach called the double-layer on and prepuccial flap technique in order to prevent fistula or fissure development. **Material and Method:** Twenty-seven patients with subcoronal hypospadias were enrolled. The prepared prepuccial flap was divided into two equal parts. A double-layer flap was formed and used for reinforcing of the neourethra. Uroflowmetric analysis was used for evaluating the urethral stricture at the end of the first year. A blinded urologist and the patients' themselves evaluated the aesthetic appearance. **Results:** The mean age was 12.17 ± 2.79 . All cases were primary. All evaluated parameters were at the end of the first year. Only three (3/27, 11.1%) of the patients had minimal external meatal stricture that managed with urethral dilatation. None of them had any fistula, fissure, or dehiscence as well as infection and hematoma. The mean Q_{max} value was 17 ml/s and the Q_{ave} value was 9 ml/s. The mean scores with standard deviations with regard to the appearance of the patients' penis before and after operations were 3.08 ± 0.77 and 8.25 ± 0.73 , respectively and this difference was statistically significant ($p < 0.001$). **Conclusion:** The double-layer dartos flap technique is a candidate to be the least risky technique to prevent complications as well as to increase the aesthetic appearance up to satisfactory levels. © 2015 S. Karger AG, Basel

Introduction

Hypospadias (Hp) in boys is an abnormal ventral opening of the urethral meatus, which may be located anywhere from the ventral aspect of the glans penis to the perineum; it is sometimes characterized by abnormal ventral curvature of the penis and a deficient foreskin ventrally [1]. Hp is the second most common congenital malformation in males, and its incidence is 1/1,000 to 1/100; it changes according to the literature due to differences of ethnic origin and countries. Etiologic reasons for its development is the environmental factors of child and mother, the endocrine and genetic background of the child, principally gonadal steroid synthesis, and the genes of the phallic development [2, 3].

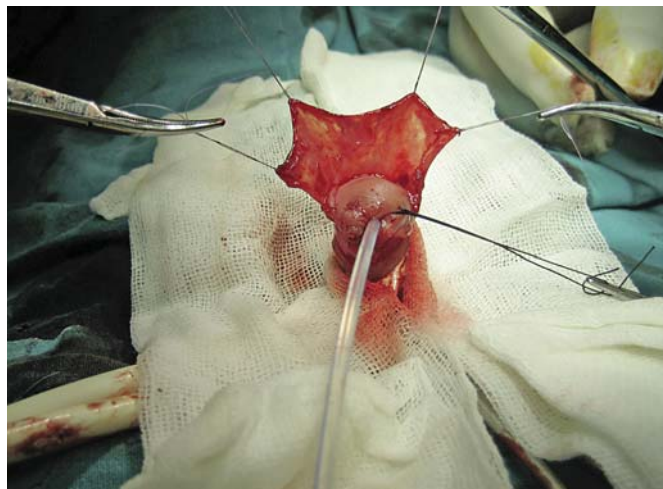
Various surgical techniques for correction of Hp have been developed that depend on the localization of the urethral meatus. The Snodgrass technique has been frequently used and was recently defined as the tubularized incised-plate urethroplasty (TIPU) [4]. The aim of Hp surgery is to provide the functional and cosmetic reconstruction of the urethra to make it suitable for coitus (especially in far proximal cases) and allow urination in the standing position [3, 4]. But, surgical correction is still difficult to deal with the complications.

Typical complications of Hp repair are fistula or fissure, meatal stenosis or urethral stricture, dehiscence, recurrent ventral curvature, diverticulum, and hematoma



Color version available online

Fig. 1. The appearance of subcoronal Hp.



Color version available online

Fig. 2. The dartos flap prepared from the dorsal prepuce and shaft skin by preserving its vascularization.

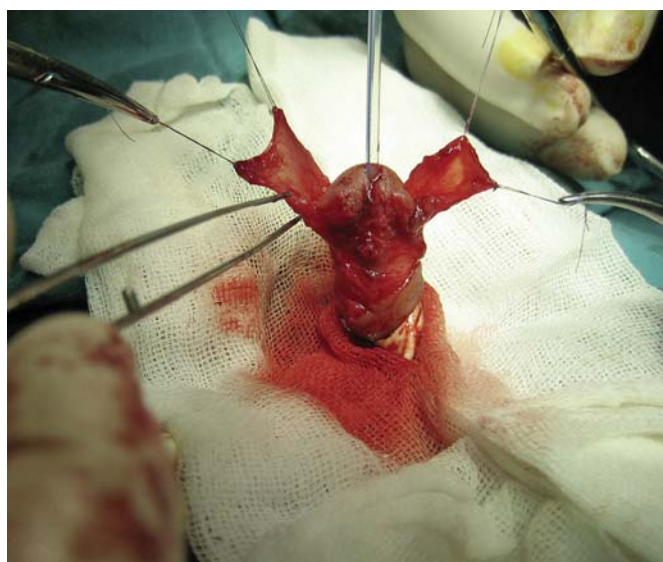[3, 4]. In this report, we describe a new approach called the double-layer on and prepucial flap technique in order to prevent fistula or fissure development.

Material and Methods

This study was designed as a nonrandomized prospective study and was approved by the local ethics committee of our institution; it was performed in accordance with the Helsinki Declaration of the World Medical Association. Informed consent was obtained from all patients prior to operation. A total of 27 patients who were admitted to our outpatient clinic between June 2012 and January 2014 with Hp were examined physically. All cases were subcoronal Hp (fig. 1). Preoperative testosterone was not given to any patients. A vasoconstrictive agent was not used during the surgery. Hemostasis was provided a penrose dren that is placed to the radix penis. A bipolar coher was used for coherisation when needed.

Surgical Technique

Surgery was performed under general anesthesia by the same surgeon (A.D.), and prophylactic antibiotics were given. A traction suture is placed, and tubularized incision of the urethral plate (TIPU) technique was performed as described by Snodgrass till dartos flap is prepared. The circumscribing incision was made about 2–3 mm below hypospadiatic meatus, and then the penis degloved totally. Ventral chordie was checked by artificial erection using isotonic solution via a butterfly needle. The visible junction of glans wings to the urethral plate was marked with a surgical marker. The midline incision of the urethral plate extended from within the hypospadiatic meatus to the end of the plate. A silicon foley catheter, whose size depends on the patient's age, was placed in the bladder. Then, urethral plate tubularization was provided with 6/0 vicryl. After tubularization, the neourethra was formed as standard the TIPU technique. The dartos flap was pre-



Color version available online

Fig. 3. The dartos flap fixed from its lateral upper edges, and then divided into two equal parts.

pared from the dorsal prepuce and shaft skin by preserving its vascularization (fig. 2). The dartos flap was fixed from its lateral upper edges, and then divided into two equal parts (fig. 3). Following this step, one of the parts of the dartos flap was carried laterally and placed onto the neourethra in order to cover it as a first layer (fig. 4). The upper edge of this part of the dartos flap was sutured to the glans wing at the opposite side with a 6/0 vicryl suture material. Also, the lateral edge of the dartos flap was sutured to the corpora cavernosa by the same suture material. After completing this procedure, the other part of the dartos flap was carried out laterally onto the first layer of the dartos flap in order to rein-

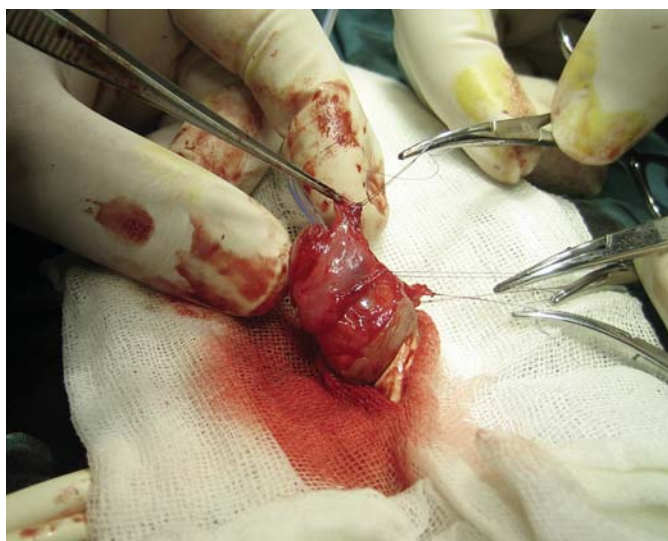

Fig. 4. One of the parts of the dartos flap carried laterally and placed onto the neourethra in order to cover it as a first layer.

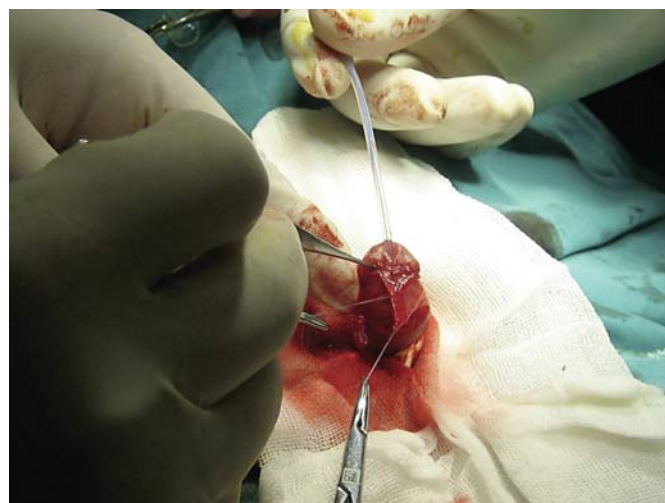


Fig. 5. The other part of the dartos flap carried out laterally onto the first layer of the dartos flap in order to reinforce the layers.

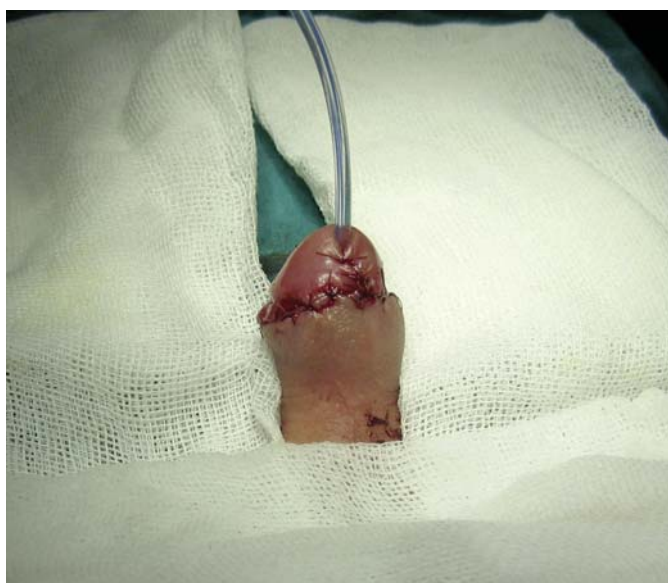

Fig. 6. Glans and skin closure.

force the layers (fig. 5). The upper edge of this part of the dartos flap was sutured to the glans wing at the opposite side with the same suture material. Glans and skin closure was then performed in the same way as with the TIPU procedure (fig. 6). Also, a suit-compressed dressing was applied.

Follow-Up Procedure

All cases were reexamined during the following year periodically (i.e. every 3 months) by conducting physical examination and uroflowmetric analysis in order to understand the early urethral structure and fistula or fissura. Also, the aesthetic appearance was

evaluated by a blinded urologist 1 year later. The main criterion in the evaluation of the cosmetic result was whether the glans penis was free or covered with the rest of the skin. The independent urologist was Ö.E.A.; he has been working in the outpatient clinic of our department. The children were referred to him for checking the cosmetic result. We did not prefer to ask the parents about the cosmetic result, because we would like to get a standardized result by using a blinded urologist. In addition to this, we also asked the patients to dapple from 0 to 10 points on a scale with straight line the appearance of their penis before and after operation according to the normal penis appearance at the end of the first year. The difference between the scores was analyzed.

Statistical Analysis

Data were analyzed using SPSS 16.0 for Windows (SPSS, Inc., Chicago, Ill., USA). Differences between the results in terms of preoperative and postoperative scores for the patients' penis appearance were analyzed using paired samples Student t-tests. Results are presented as mean \pm standard deviation.

A comparative statistical analysis with regard to uroflowmetric parameters and complications was not used because only one surgical technique was performed. Some parameters including age, maximum flow rate (Q_{max}), and average flow rate (Q_{ave}) were calculated as a mean value. Also, the aesthetic appearance satisfaction percent that was realized by the blinded urologist was calculated.

Results

The mean age of the children was 12.17 ± 2.79 (range 9–19). All cases were primary and their localizations were subcoronal location. All evaluated parameters were at the end of the first year. Only three (3/27, 11.1%) of the pa-

Table 1. The demographic characteristics with the study results

| Parameters | Values |
|-------------------------|------------|
| Age, mean | 12.17 |
| Q _{max} , ml/s | 17 |
| Q _{ave} , ml/s | 9 |
| Stricture | 3/27 11.1% |
| Fistula | 0/27 |
| Infection or hematoma | 0/27 |

tients have minimal external meatal stricture that managed with urethral bougie dilatation. None of them have any fistula, fissure, or dehiscence as well as infection and hematoma. The mean Q_{max} value was 17 ml/s, and the Q_{ave} value was 9 ml/s (table 1). All children's aesthetic appearance satisfaction achieved a good level and their glans penis were free with the rest of skin according to the blinded urologist. The mean scores with standard deviations with regard to the appearance of the patients' penis before and after operations were 3.08 ± 0.77 and 8.25 ± 0.73 , respectively and this difference was statistically significant ($p < 0.001$).

Discussion

Hp is one of the most frequently observed birth anomalies of the urogenital system, with an incidence of about 0.2 to 0.4%. Most cases are distally located. Although there are over 300 surgical methods described for Hp surgery, there is no consensus on the optimal surgical technique [5]. The main purpose of this research was to generally deal with the complications of Hp surgery, such as urethrocutaneous fistula, fissure, dehiscence or urethral stricture, as well as infection and hematoma. Based on the age group of this patient population, these complications are especially important due to the fact that the effect of the re-operations on the children's psychological status. For that reason, the surgeon should be focused to repair as long as it is possible at one step for Hp, because the postoperative process can be challenging for both the surgeon and patients, most of whom are children, when complications occur.

The incidence of urethrocutaneous fistula has changed from 4 to 20% in larger studies. Factors such as stricture throughout the new urethra, tissue ischemia, and postoperative infection can cause fistula after Hp repair. The frequency of fistula formation can be decreased by the surgeons' experience, improvement in technique, use of ap-

propriate suture materials and instruments, and coverage of the operation area with well-vascularized tissue [6]. The role of catheter or a stent in Hp repair was investigated in order to prevent some complications such as fistula, stenosis or a stricture. But the response is still controversial. According to Xu's et al. study, there was no increased risk of fistula, meatal stenosis, or urethral stricture formation with non-catheter repair [7]. Ardel et al. presented their clinical outcome of Hp repair by Barcat and Duckett using the GRACE (glandular resection and central embedding) modification technique. According to their results, for all GRACE repairs, cosmetic appearance was favorable regarding the meatal position, shape and overall appearance. In Barcat and Duckett repairs, urethrocutaneous fistulas occurred in 5 and 30.7%, urethral stricture in 3 and 20.8%, and meatal strictures in 5 and 25.3%, respectively [8]. Ding et al. presented their results, according to their method, which consist of a combined buccal mucosa graft and local flap for urethroplasty. Depending on their results, the rates of fistula and stricture were 5 and 1.8%, respectively [9]. None of our cases developed any urethrocutaneous fistula except minimal external meatal stricture in three of them (3/27, 11.1%).

Thomas et al. showed that in their prospective and randomized study the use of dartos flaps in Hp surgery offers no statistically significant advantage over flapless repair for complication rates [10]. Other studies, however, have reported that the use of the dartos flap is a good choice for preventing fistula [11, 12]. Many studies have begun to use the double-dartos flap in order to prevent the total formation of the fistula for both primary and failed Hp repair [13–16]. In our study, we also applied double-dartos flaps using a prepuccial flap by dividing the dorsal prepuccial flap into two equal parts for primary cases (fig. 3). According to our study, neither urethrocutaneous fistula nor urethral stricture throughout the neo-urethra except external meatal formed during the follow-up period of 1 year.

The aesthetic appearance of the new glans was also considered satisfactory by the blinded urologist as well as older children and the parents of younger children.

Limitations

One of the important limitations of our study is that our results have not been compared with those obtained from the standard technique that is performed by the same surgeon and in the same patient population. It would be better as a randomized comparative study with the standard one-layer technique. The other limitations are small number cases and short follow-up time.

Conclusion

Hp surgery, not only for the surgeons but also for the patients, is important because bothersome complications can occasionally occur. For that reason, the least risky technique to prevent fistula should be chosen. According to our results, the double-layer dartos flap technique is considered to be the least risky technique to prevent complications as well as to increase the levels of aesthetic appearance.

References

- 1 Mouriquand PD, Persad R, Sharma S: Hypospadias repair: current principles and procedures. *Br J Urol* 1995;76(suppl 3):9–22.
- 2 Demir A, Karadağ MA, Cecen K, Arslan OE: Hypospadias in three generations: is there a dominant responsible gene for hypospadias? *J Med Cases* 2014;5:152–154.
- 3 Tekgöl S, Riedmiller H, Dogan HS, Hoebeke P, Kocvara R, Nijman R, Radmayr Chr, Stein R: Hypospadias; in *Guidelines on Paediatric Urology*. European Association of Urology, 2014, pp 23–26.
- 4 Choi DS, Lee JW, Yang JD, Chung HY, Cho BC, Byun JS, Choi KY: Correction of problematic hypospadias with dartos fascia-reinforced flap and slanted incision of fistula. *Arch Plast Surg* 2013;40:766–772.
- 5 Wishart ED, Metcalfe PD: A modification of the TIP procedure for distal hypospadias: the burrowing technique. *Can Urol Assoc J* 2014;8:E425–E428.
- 6 Sunay M, Dadali M, Karabulut A, Emir L, Erol D: Our 23-year experience in urethrocutaneous fistulas developing after hypospadias surgery. *Urology* 2007;69:366–368.
- 7 Xu N, Xue XY, Wei Y, Li XD, Zheng QS, Jiang T, Huang JB: Outcome analysis of tubularized incised plate repair in hypospadias: is a catheter necessary? *Urol Int* 2013;90:354–357.
- 8 Ardeli PU, Cederquist M, Schoenthaler M, Miernik A, Frankenschmidt A: The glandular resection and central embedding modification (GRACE) in duckett and barcat hypospadias repair. *Urol Int* 2013;90:358–364.
- 9 Ding J, Li Q, Li S, Li F, Zhou C, Zhou Y, Hu J, Xie L, Cao Y, Zhang S: Ten years' experience for hypospadias repair: combined buccal mucosa graft and local flap for urethral reconstruction. *Urol Int* 2014;93:454–459.
- 10 Thomas DT, Karadeniz Cerit K, Yener S, Kandirici A, Dagli TE, Tugtepe H: The effect of dorsal dartos flaps on complication rates in hypospadias repair: a randomised prospective study. *J Pediatr Urol* 2015;11:23.e1–e4.
- 11 Djordjevic ML, Perovic SV, Vukadinovic VM: Dorsal dartos flap for preventing fistula in the Snodgrass hypospadias repair. *BJU Int* 2005;95:1303–1309.
- 12 Djordjevic ML, Perovic SV, Slavkovic Z, Djakovic N: Longitudinal dorsal dartos flap for prevention of fistula after a Snodgrass hypospadias procedure. *Eur Urol* 2006;50:53–57.
- 13 Abolyosr A: Snodgrass hypospadias repair with onlay overlapping double-layered dorsal dartos flap without urethrocutaneous fistula: experience of 156 cases. *J Pediatr Urol* 2010;6:403–407.
- 14 Cimador M, Pensabene M, Sergio M, Catalano P, de Grazia E: Coverage of urethroplasty in pediatric hypospadias: randomized comparison between different flaps. *Int J Urol* 2013;20:1000–1005.
- 15 Yildiz A, Bertozzi M, Akin M, Appignani A, Prestipino M, Dokucu AI: Feasibility of a tubularised incised-plate urethroplasty with double de-epithelised dartos flaps in a failed hypospadias repair: a preliminary report. *Afr J Paediatr Surg* 2012;9:8–12.
- 16 Kureel SN, Vasudeva P, Sinha SK, Dalela D: 'Limited' double dorsal dartos flap coverage. An effective alternative to conventional flap coverage of the neourethra following Mathieu repair for subcoronal hypospadias. *Int Urol Nephrol* 2008;40:569–572.

Acknowledgments

None.

Disclosure Statement

There are no conflicts of interest to declare.