

Occurrence of rhabdomyolysis, serotonin syndrome, and acute respiratory distress syndrome in a child secondary to ecstasy intoxication

Çocuk hastada ekstazi zehirlenmesine ikincil gelişen rabdomiyoliz, serotonin ve akut solunum sıkıntısı sendromu

Cite this article as: Yeşilbaş O, Uzuner S, Korkmaz Ç, Nurmammadova L, Doğan Demir A. Occurrence of rhabdomyolysis, serotonin syndrome, and acute respiratory distress syndrome in a child secondary to ecstasy intoxication. *Turk Pediatri Ars* 2019; 54(4): 281–3.

Dear Editor,

3,4-methylenedioxymethamphetamine, or ecstasy (the name used more commonly), is a derivative of amphetamine. In recent years, its use and addiction in adolescents has increased worldwide. Ecstasy abuse and intoxication is manifested by considerably different clinical conditions and may lead to morbidity and mortality (1–4). Here, we present a pediatric patient who developed rhabdomyolysis, serotonin syndrome (SS), and acute respiratory distress syndrome (ARDS) secondary to ecstasy intoxication with the objective of drawing pediatricians' attention to this issue.

A 13-year-old female patient was referred to our pediatric intensive care unit because of markedly increased body temperature (41.6°C), tachycardia, flushing, involuntary tremor, sweating and altered mental status. Her physical examination was as follows; heart rate was 160 b.p.m., blood pressure: 110/75 mm Hg, respiratory rate: 35/min, body temperature: 40.6°C, capillary refill time: 1–2 s. Agitation, anxiety, myoclonus, respiratory failure, mydriatic pupils that responded to bright light, horizontal nystagmus, and increased deep tendon reflexes were found. Lung auscultation revealed that breath sounds were diminished in the right lung compared with the left lung. An abdominal examination revealed no pathology except for extremely increased bowel sounds. Bod gas analysis revealed normal lactate level (0.8 mmol/L) and mild metabolic acidosis (pH: 7.34, CO₂: 38 mm Hg, HCO₃: 20.3 mmol/L, base excess: -5). The complete blood count was normal except for leukocytosis (24 800/mm³). The other laboratory findings were as follows: serum urea: 46 mg/dL, creatinine: 1.79 mg/dL, uric acid: 15.1 mg/dL, phosphorus: 7.2 mg/dL, lactate dehydrogenase (LDH): 507 U/L (120–300 U/L),

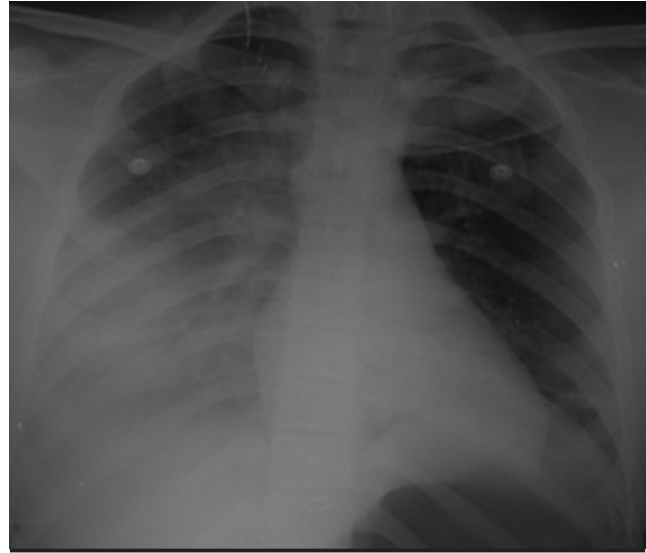


Figure 1. Chest X-ray at the time of the patient's presentation

creatinine kinase (CK): 1981 U/L (30–200 U/L), CK-MB: 37.2 ng/mL (0–3.4 ng/mL), and troponin: I 541.2 pg/mL (0–31 pg/mL). Other biochemical tests, electrolytes, and coagulation values were found to be within the normal limits. An electrocardiogram revealed sinus tachycardia, and chest X-ray revealed infiltration that was more prominent on the right side (Fig. 1). Echocardiographic measurements were within the normal limits. A short time after hospitalization, the patient stated that she ingested nine tablets of a medicine she had purchased and did not know its name. Amphetamine was found to be positive on toxicologic screening of urine and a diagnosis of SS secondary to ecstasy was made with the history, clinical findings, and laboratory findings.

Table 1. Renal functions tests and course of the hepatic, muscle and cardiac enzymes from the time of hospitalization of the patient

	0. day	1 st day	2 nd day	3 rd day	4 th day	5 th day
Urea (mg/dL)	46	30	30	32	29	18
Creatinine (mg/dL)	1.79	1.36	0.9	0.72	0.64	0.6
Uric acid (mg/dL)	15.1	9.2	5.4	3.9	3.6	3.2
CK (U/L)	1981	8 280	19 522	10 747	13 291	4 910
AST (U/L)	48	124	522	442	262	150
ALT (IU/L)	19	123	161	222	217	182
LDH (U/L)	507	379	618	521	498	293
CK-MB (ng/mL)	37.2	53.4	66.9	20.4	13.4	7.9
Troponin I (pg/mL)	541.2	500.1	478.5	263.6	29	15.2

ALT: Alanine aminotransferase; AST: Aspartate aminotransferase; CK: Creatinine kinase; CK-MB: Creatin kinase-MB; LDH: Laktate dehydrogenase

Respiratory support was initiated using a non-rebreathing oxygen mask with a reservoir bag. Five hundred milliliters of cold isotonic solution of sodium chloride was loaded and ibuprofen was given by nasogastric tube to the patient who was dehydrated and whose body temperature remained high despite paracetamol administration in the previous hospital. Intravenous midazolam and dexmedetomidine infusion was initiated for the treatment of tremor, anxiety, agitation, and SS. The ceftriaxone treatment that was initiated in the previous hospital was continued. Maintenance fluid (3500 mL/m²/day) and alkalinization treatment was initiated in terms of potential progression to rhabdomyolysis and prerenal renal failure. Allopurinol was added to the treatment for increased uric acid levels.

Pulse oxygen saturation regressed to 88% from the fourth hour of hospitalization under a non-rebreathing oxygen mask with a reservoir bag. Tremor, agitation, and anxiety continued despite midazolam and dexmedetomidine infusion. Her body temperature increased again (40.1°C) despite the antipyretics and cold application. It was observed that her liver enzymes and CK values were increasing rapidly (Table 1). She was intubated because of all these factors, rocuronium infusion was added to treatment, and invasive mechanical ventilation (MV) was initiated. N-acetylcysteine infusion (2500 mg/day) was added to the treatment for antioxidant properties. Oxygen saturation under invasive MV and lung radiography (Fig. 2) were compatible with moderate ARDS. Intravenous furosemide infusion and lung-protective MV strategy were initiated for ARDS treatment. Mechanical ventilation settings were weaned and her body temperature gradually decreased with these treatments. She was extubated on the second day of hospitalization. Renal function tests started to decrease a short while after hospitalization and her liver enzymes, CK, CK-MB, and troponin I values started to

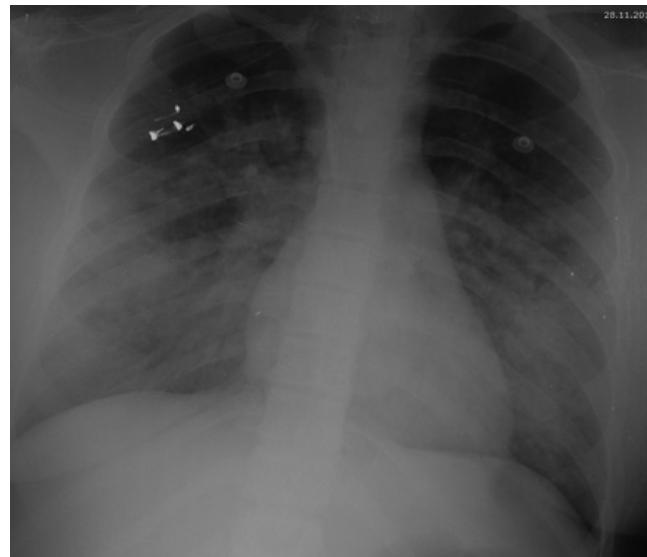


Figure 2. Chest X-ray performed four hours after hospitalization which is compatible with acute respiratory distress syndrome

decrease from the third day (Table 1). On the fourth day of hospitalization, she was transferred to the pediatric ward. In the pediatric ward, she received intravenous fluid and N-acetylcysteine treatment for five days. During this period, her liver enzymes, CK, CK-MB, and troponin I values gradually decreased and normalized. The patient was discharged after a total hospitalization time of 10 days in a healthy condition.

Ecstasy has a considerably high degree of structural similarity to serotonin in contrast to other traditional amphetamines, it increases the release of serotonin excessively and inhibits reuptake from relevant receptors. Therefore, it may lead to tachycardia, hypertension, hyperthermia, SS, and stimulation of the central nervous system (CNS) (agitation, anxiety and delirium). Seroto-

nin syndrome, which occurs as a result of extreme serotonin release, is characterized by autonomic dysfunction, abnormal neuromuscular activity, and inhibition of the CNS (4). Our patient had all findings that could occur in SS and she also had hypotension, which was secondary to autonomic dysfunction in our point of view. If hyperthermia that occurs secondary to SS cannot be controlled, it may lead to rhabdomyolysis and disseminated intravascular coagulation syndrome (4). Hyperthermia continued in our patient despite antipyretics and cold application. In addition, tremor, agitation, and anxiety could not be controlled completely, though partial improvement was observed in these symptoms with midazolam and dexmedetomidine, which were initiated as a sedative and anxiolytic. We had to intubate our patient whose rhabdomyolysis progressed and whose oxygen requirement was increased. Following intubation, we provided sedoanalgesia with midazolam and fentanyl and inhibited tremor and contractions completely with rocuronium infusion.

Cases of ecstasy-related hyperthermia and ecstasy-related ARDS (as part of multiorgan failure) have been reported in the literature. Oxidative injury secondary to hyperthermia has been indicated as the underlying physiopathology as in other ecstasy-related organ failures (5, 6).

Early recognition of the signs and symptoms of ecstasy including mainly SS by pediatricians and initiation of rapid treatment will prevent progression to multi-organ failure, morbidity, and mortality.

 Osman Yeşilbaş¹,  Selçuk Uzuner²,  Çiğdem Korkmaz²,  Lala Nurmammadova²,  Aysegül Doğan Demir²

¹Pediatric Intensive Care Unit, Bezmialem Foundation University Faculty of Medicine, İstanbul, Turkey

²Department of Pediatrics, Bezmialem Foundation University Faculty of Medicine, İstanbul, Turkey

Informed Consent: Written informed consent was obtained from patients' parents.

Peer-review: Externally peer-reviewed.

Author Contributions: Concept - O.Y., Ç.K., S.U.; Design - O.Y., S.U.; Supervision - A.D.D.; Funding - Ç.K., L.M., Ş.S.; Materials - H.N., G.E.; Data Collection and/or Processing - H.N., G.E., L.M.; Analysis and/or Interpretation - O.Y., S.U., A.D.D.; Literature Review- S.U., Ç.K.; Writer - O.Y.; Critical Review – A.D.D., S.U.

Conflict of Interest: The authors have no conflicts of interest to declare.

Financial Disclosure: The authors declared that this study has received no financial support.

Hasta Onamı: Yazılı hasta onamı hastanın ebeveynlerinden alınmıştır.

Hakem Değerlendirmesi: Dış bağımsız.

Yazar Katkıları: Fikir - O.Y., Ç.K., S.U.; Tasarım - O.Y., S.U.; Denetleme - A.D.D.; Kaynaklar - Ç.K., L.M., Ş.S.; Malzemeler - H.N., G.E.; Veri Toplanması ve/veya İşlenmesi - H.N., G.E., L.M.; Analiz ve/veya Yorum - O.Y., S.U., A.D.D.; Dizin Taraması - S.U., Ç.K.; Yazıyı Yazan - O.Y.; Eleştirel İnceleme - A.D.D., S.U.

Çıkar Çatışması: Yazarlar çıkar çatışması bildirmemişlerdir.

Mali Destek: Yazarlar bu çalışma için finansal destek almadıklarını beyan etmişlerdir.

References

- Palamar JJ, Kamboukos D. An examination of sociodemographic correlates of ecstasy use among high school seniors in the United States. *Subst Use Misuse* 2014; 49: 1774-83.
- Ogel K, Corapçioğlu A, Sir A, et al. Tobacco, alcohol and substance use prevalence among elementary and secondary school students in nine cities of Turkey. [Article in Turkish] *Turk Psikiyatri Derg* 2004; 15: 112-8.
- Uzun M, Karakaş B, Topaloğlu Ö, Taşkıran E, Akar H, Özdoğan Ö. Ekstazi intoksikasyonuna bağlı kötü bir kabus: ST segment elevasyonu. *FNG & Bilim Tıp Dergisi* 2015; 1: 94-7.
- Hoffman RJ. MDMA (ecstasy) intoxication. *UpToDate* 2017.
- Walubo A, Seger D. Fatal multi-organ failure after suicidal overdose with MDMA, 'ecstasy': case report and review of the literature. *Hum Exp Toxicol* 1999; 18: 119-25.
- Simpson DL, Rumack BH. Methylenedioxyamphetamine. Clinical description of overdose, death, and review of pharmacology. *Arch Intern Med* 1981; 141: 1507-9.

Address for Correspondence / Yazışma Adresi:

Osman Yeşilbaş E-mail/ E-posta: drosmanyesilbas@gmail.com

Received / Geliş Tarihi: 08.02.2019

Accepted / Kabul Tarihi: 05.03.2019

©Copyright 2019 by Turkish Pediatric Association - Available online at www.turkpediatriarsivi.com

©Telif Hakkı 2019 Türk Pediatri Kurumu

Derneği - Makale metnine

www.turkpediatriarsivi.com web adresinden ulaşılabilir.

DOI: 10.14744/TurkPediatriArs.2019.48265

