



## Beneficial effects of dexpanthenol on mesenteric ischemia and reperfusion injury in experimental rat model

Yasir Furkan Cagin, Yahya Atayan, Nurhan Sahin, Hakan Parlakpınar, Alaadin Polat, Nigar Vardi, Mehmet Emin Tagluk, Kevser Tanbek & Azibe Yildiz

To cite this article: Yasir Furkan Cagin, Yahya Atayan, Nurhan Sahin, Hakan Parlakpınar, Alaadin Polat, Nigar Vardi, Mehmet Emin Tagluk, Kevser Tanbek & Azibe Yildiz (2016) Beneficial effects of dexpanthenol on mesenteric ischemia and reperfusion injury in experimental rat model, *Free Radical Research*, 50:3, 354-365, DOI: [10.3109/10715762.2015.1126834](https://doi.org/10.3109/10715762.2015.1126834)

To link to this article: <https://doi.org/10.3109/10715762.2015.1126834>



Published online: 14 Jan 2016.



Submit your article to this journal [↗](#)



Article views: 582



View related articles [↗](#)



View Crossmark data [↗](#)



Citing articles: 2 View citing articles [↗](#)

ORIGINAL ARTICLE

## Beneficial effects of dexpanthenol on mesenteric ischemia and reperfusion injury in experimental rat model

Yasir Furkan Cagin<sup>a</sup>, Yahya Atayan<sup>a</sup>, Nurhan Sahin<sup>b</sup>, Hakan Parlakpınar<sup>c</sup>, Alaadin Polat<sup>d</sup>, Nigar Vardi<sup>e</sup>  
Mehmet Emin Tagluk<sup>f</sup>, Kevser Tanbek<sup>d</sup> and Azibe Yildiz<sup>e</sup>

<sup>a</sup>Department of Gastroenterology, Medical Faculty, Inonu University, Malatya, Turkey; <sup>b</sup>Department of Pathology, Medical Faculty, Inonu University, Malatya, Turkey; <sup>c</sup>Department of Pharmacology, Medical Faculty, Inonu University, Malatya, Turkey; <sup>d</sup>Department of Physiology, Medical Faculty, Inonu University, Malatya, Turkey; <sup>e</sup>Department of Histology and Embryology, Medical Faculty, Inonu University, Malatya, Turkey; <sup>f</sup>Department of Electrical and Electronics, Inonu University, Malatya, Turkey

### ABSTRACT

**Background and aim** It has been reported that intestinal ischemia–reperfusion (I/R) injury results from oxidative stress caused by increased reactive oxygen species. Dexpanthenol (Dxp) is an alcohol analogue with epithelization, anti-inflammatory, antioxidant, and increasing peristalsis activities. In the present study, the aim was to investigate protective and therapeutic effects of Dxp against intestinal I/R injury. **Materials and methods** Overall, 40 rats were assigned into five groups including one control, one alone Dxp, and three I/R groups (40-min ischemia; followed by 2-h reperfusion). In two I/R groups, Dxp (500 mg/kg, i.m.) was given before or during ischemia. The histopathological findings including apoptotic changes, and also tissue and serum biochemical parameters levels, were determined. Oxidative stress and ileum damage were assessed by biochemical and histological examination. In the control ( $n = 8$ ) and alone Dxp ( $n = 8$ ; 500 mg/kg, i.m. of Dxp was given at least 30 min before recording), groups were incised via laparotomy, and electrical activity was recorded from their intestines. In this experiment, the effect of Dxp on the motility of the intestine was examined by analyzing electrical activity. **Results** In ileum, oxidant levels were found to be higher, while antioxidant levels were found to be lower in I/R groups when compared with controls. Dxp approximated high levels of oxidants than those in the control group, while it increased antioxidant values compared with I/R groups. Histopathological changes caused by intestinal I/R injury and histological improvements were observed in both groups given Dxp. In the Dxp group, electrical signal activity markedly increased compared with the control group. **Conclusions** Here, it was seen that Dxp had protective and therapeutic effects on intestinal I/R injury and gastrointestinal system peristalsis.

### ARTICLE HISTORY

Received 12 October 2015  
Accepted 29 November 2015  
Published online 7 January 2016

### KEYWORDS

Dexpanthenol; ischemia–reperfusion; intestinal tissue; oxidative stress; rat

## Introduction

Small intestines are most sensitive organs to ischemia–reperfusion (I/R) injury among the other internal organs [1,2]. Enterocytes, the predominant cells in the small intestinal mucosa, are easily injured by episodes I/R, presumably because of their location at the end of the distribution of a central arteriole and a relative lack of collateral blood flow. This situation can also result in a lower PaO<sub>2</sub> in the distal enterocytes when compared with proximal enterocytes [1].

Acute disruptions in mesenteric blood flow due to any reason can cause ischemic lesions in association with adverse results that may result to death (45–85%) if early diagnosis and treatment would not be possible [3]. The injury and its seriousness depend on duration and severity of ischemia. Tissue injury caused by

ischemia primarily develops after reperfusion [4,5] which may be explained by a complex mechanism associated with ROS released from ischemic intestines as well as endothelial factors and neutrophils. Moreover, cytokines released (IL-1, IL-6, TNF- $\alpha$ , and IFN- $\gamma$ ) enhance tissue and organ injury through local and systemic responses [6]. Although oxidative stress is abolished immediately after reperfusion, inflammatory response may continue for a longer period, causing irreversible tissue damage [7]. Apoptosis induced by oxidative stress plays an important role in mesenteric ischemia. Intracellular fragments called apoptotic bodies are formed through degradation of nuclear chromatin and shrinkage of cytoplasm and nucleus, which activates the protein family of

caspace. Thus, caspace 3 is used as a marker for early apoptotic phase [8].

Dexpanthenol (Dxp) is an alcohol analogue of pantothenic acid (PA) [9] which is also known as pro-vitamin B5 [10]. It translates to PA in tissue when given by oral or parenteral route [11]. Both oral and parenteral Dxp are enzymatically (pantothetylalcohol dehydrogenase) oxidized to PA [12], and, therefore, causes an increase in reduced GSH, Co-enzyme A (CoA), and cellular ATP synthesis [13]. In this way, it exerts epithelization, anti-inflammatory, and antioxidant activities. As it is known that Dxp increases peristalsis on the gastrointestinal system (GIS), which may be engaged through increased acetylcholine synthesis [12].

In this experimental study, the aim was to investigate protective and therapeutic effects of Dxp with antioxidant and anti-inflammatory effects on mesenteric I/R injury and GIS peristalsis by biochemical, histopathological findings, and motility of the intestine via measured electrical activity.

## Materials and methods

### Animals

The study was approved by Ethics Committee of Inonu University on Experimental Animal Research (reference no. 2014/A-37). Totally, 40 female Wistar Albino rats (weighing 210–230 g, mean: 220 g) were used in the study. The rats were provided by Inonu University Experimental Animal Research Center. All rats were

housed under standard conditions with a temperature of  $21 \pm 2^\circ\text{C}$  and a humidity of  $60 \pm 5\%$  by maintaining 12-h dark–light cycle. They were fed by means of standard rat pellet and tap water with 12-hr fasting before experiment.

### Experimental protocol

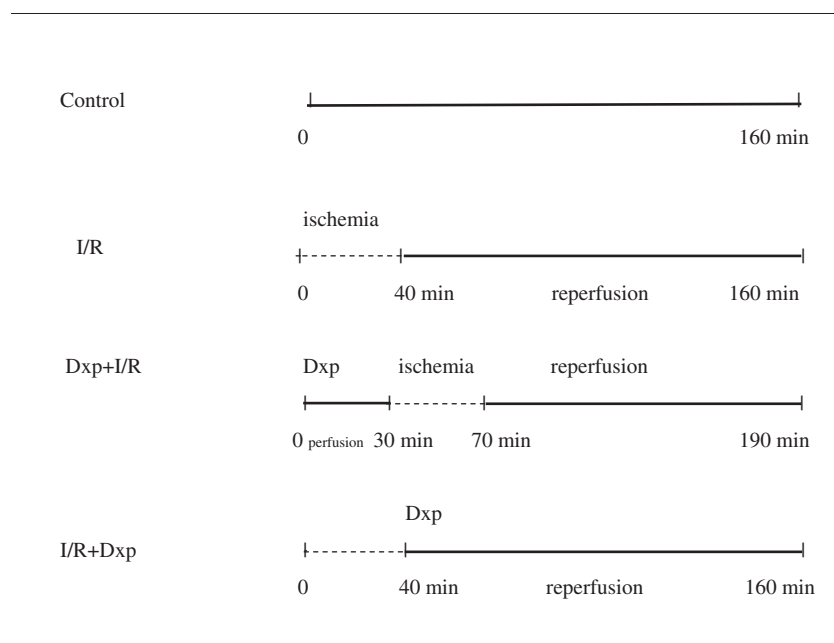
The rats were randomly divided into five groups ( $n = 8$ ) and housed separately throughout the experiment.

*Group I (Sham,  $n = 8$ ):* Superior mesenteric artery (SMA) was visualized at the level of origin from abdominal aorta but not ligated and the intestinal electrical activity was recorded.

*Group II (Ligation,  $n = 8$ ):* SMA was visualized at the level of origin from abdominal aorta. Then, it was clamped to occlude arterial blood flow by using atraumatic microvascular clamp. The clamp was removed after 40 min of ischemia, allowing reperfusion for 2 h.

*Group III (Dxp + Ligation,  $n = 8$ ):* Dxp (500 mg/kg; Bepanthen vial, 500 mg; Bayer Corp, Istanbul, Turkey) was given via intramuscular route 30 min before inducing ischemia. Then, SMA was clamped to achieve ischemia. After 40 min of ischemia, the clamp was removed, allowing reperfusion for 2 h.

*Group IV (Ligation + Dxp,  $n = 8$ ):* SMA was clamped to achieve ischemia. After 40 min of ischemia, the clamp was removed, allowing reperfusion for 2 h (Figure 1). At the end of ischemia period, Dxp (500 mg/kg, i.m.) was given before reperfusion.



**Figure 1.** Schematic representation of timing of ischemia, reperfusion, and administration of dexpanthenol (Dxp) in the experimental groups.

*Group V (Dxp, n = 8):* Dxp (500 mg/kg) was given via intramuscular route 30 min before recording electrical activity.

Note that the I/R periods and Dxp dose were determined based on the previous studies [3,12].

### **Surgical procedure**

Rats were anesthetized by using ketamine (70 mg/kg; i.m.) and xylazine (8 mg/kg; i.m.). Then, abdomen was shaved and prepared by using povidone iodine (Poviodex; Kim-Pa Corporation, Istanbul, Turkey). After preparation, the laparotomy was performed by using midline incision. SMA was exposed at the level of origin from abdominal aorta after abdominal exploration. Then, SMA was occluded by clamping at the level of origin to achieve 40 min of ischemia. After ischemia period, the clamp was removed, allowing reperfusion. Then, abdominal incision was closed by using 3/0 atraumatic silk suture. After 2 h of reperfusion, abdomen was exposed on the previous incision location. Blood (5 ml) was drawn by intracardiac route for aspartate aminotransferase (AST), alanine aminotransferase (ALT), lactate dehydrogenase (LDH), and creatine kinase (CK) measurements by using an auto-analyzer. Then, rats were sacrificed. In addition, full-thickness ileum specimens (4 cm in length) were taken at 2 cm proximal to terminal ileum. After washing with normal saline, tissue samples were placed into 10% formalin and liquid nitrogen. They were stored at  $-70^{\circ}\text{C}$  until assays. Oxidative stress (MDA, TOS, and OSI) and antioxidant system markers (GSH, GPX, SOD, CAT, and TAC) were analyzed after thawing tissue samples at room temperature. Tissue samples for histopathological examination were fixed in 10% formalin.

The rats (Groups I and V) were anesthetized and underwent laparotomy and the micro-electrodes were subserosally implanted into their small intestinal at ileum and ascending colon with a bipolar configuration; the interelectrode spacing was larger than 1 cm. The reference electrode was placed on the left leg. The intestinal myoelectrical activity was recorded for 4 min under anesthesia by a BIOPAC MP-100 A-CE data acquisition system (BIOPAC Systems, Goleta, CA). These records were taken as the reference or control signals. As the control recordings were finished, the rats under anesthesia were treated with Dxp. Later on, about an half hour after Dxp treatment, rats' intestinal myoelectrical activity that considered as the cause of contractile was measured in the same way as was taken during control measurements. The aim in measuring the myoelectrical signals in this way was to get signals from rats while they are alive, that is, without isolation of intestinal tissue.

Both control and Dxp guided signals were digitized with 500 Hz sampling frequency and transferred to a personal computer. The signals were then analyzed in Matlab (version 6, The Mathworks Inc, Natick, MA).

### **Histological method**

For light microscopic analysis, samples from ileum were fixed in 10% formalin for 48 h dehydrated in ascending alcohol series, and embedded in paraffin. Paraffin blocks were prepared for sectioning at  $4\mu\text{m}$  thickness by microtome. The sections obtained from paraffined blocks were stained with hematoxylin and eosin (H-E). Preparations were evaluated under light microscope and mucosal injury was rated according to classification systems described by Chiu et al.

For immunohistochemical analysis, sections were placed in antigen retrieval solution (citrate buffer, pH 6.0), boiled in a pressure cooker for 20 min, and cooled to room temperature for 20 min. Then the sections were washed with phosphate-buffered saline (PBS). After washing the sections, 3% hydrogen peroxide solution was applied to block endogenous peroxide for 15 min at room temperature and washed with PBS. Then protein block was applied to the sections. The sections were incubated with primary rabbit-polyclonal caspase-3 antibody (Neomarker, USA) for 60 min, and then they were rinsed in PBS and incubated with biotinylated goat antipolyvalent for 20 min and streptavidin peroxidase for 20 min at room temperature. Staining was completed with chromogen + substrate for 10 min, and slides were counter stained with Mayer's hematoxylin.

### **Biochemical analysis**

Two hundred milligrams of frozen ileum tissue was cut into pieces on dry ice and homogenized in 10 volumes of ice-cold Tris-HCl buffer with respect to tissue weight (50 mmol/L, pH 7.4) using a homogenizer (Ultra Turrax IKAT18 basic homogenization; Werke, Staufen, Germany) for 3 min at 6000 rpm. The supernatant solution was extracted with an equal volume of an ethanol/chloroform mixture (3/5, volume per volume [v/v]). After centrifugation at 3000 *g* for 30 min, the upper layer was used in the analysis of total tissue protein levels.

### **Determination of MDA**

The MDA contents of the homogenates were determined spectrophotometrically by measuring the presence of thiobarbituric acid reactive substances (TBARS) [14]. About 3 ml of 1% phosphoric acid and 1 ml 0.6% thiobarbituric acid solution were added to 0.5 ml of

homogenate pipetted into a tube. The mixture was heated in boiling water for 45 min. After the mixture cooled, the colored part was extracted into 4 ml of *n*-butanol. The absorbance was measured by spectrophotometer (UV-1601; Shimadzu, Kyoto, Japan) at 532 and 520 nm. The amount of lipid peroxides was calculated as TBARS of lipid peroxidation. The results were calculated in nmol/g tissue according to a prepared standard graph, which was prepared using the measurements of standard solutions (1,1,3,3-tetramethoxypropane).

#### **Determination of protein content**

Protein content of the samples was determined by the method of Lowry et al. [15] using bovine serum albumin as a standard.

#### **Determination of SOD activity**

Total SOD activity was determined based to the method of Sun et al. [16]. The principle of the method is the inhibition of nitrobluetetrazolium (NBT) reduction by the xanthine-xanthine oxidase system as a superoxide generator. One unit of SOD was defined as the enzyme amount causing 50% inhibition in the NBT reduction rate. SOD activity was given as units per milligram protein (U/mg protein).

#### **Determination of CAT activity**

CAT activity was determined according to Aebi's method [17]. The principle of the assay is based on the determination of the rate constant ( $k$ ,  $s^{-1}$ ) or the  $H_2O_2$  decomposition rate at 240 nm. Results are expressed as  $k$  per gram protein ( $k/g$  protein).

#### **Determination of GPX activity**

Determination of GPX activity was measured by the method of Paglia and Valentine [18]. An enzymatic reaction in a tube containing NADPH, GSH, sodium azide, and glutathione reductase was initiated by the addition of  $H_2O_2$ , and the change in absorbance at 340 nm was observed by a spectrophotometer. Activity was given in units per gram protein (U/g protein).

#### **Determination of GSH content**

The reduced GSH concentration in homogenate was measured spectrophotometrically according to the method of Ellman. The reduced GSH content in ileum tissue as non-protein sulfhydryls was analyzed with this described method [19]. Aliquots of tissue homogenate

were mixed with distilled water and 50% trichloroacetic acid in glass tubes and centrifuged at 3000 rpm for 15 min. The supernatants were mixed with Tris buffer (0.4 mol, pH 8.9) and 5,5'-dithiobis (2-nitrobenzoic acid) (DTNB, 0.01 mol) was added. After shaking the reaction mixture, its absorbance was measured at 412 nm within 5 min of the addition of DTNB against blank with no homogenate. The absorbance values were extrapolated from a glutathione standard curve and expressed as reduced GSH (micromol/g tissue).

#### **Determination of TAC**

TAC levels were determined using a novel automated colorimetric measurement method developed by Erel [20]. In this method, the hydroxyl radical, the most potent biological radical, is produced by the Fenton reaction and reacts with the colorless substrate *O*-dianisidine to produce the dianisyl radical, which is bright yellowish-brown in color. Upon the addition of sample, the oxidative reactions initiated by the hydroxyl radicals present in the reaction mix are suppressed by the antioxidant components of the sample, preventing the color change and thereby providing an effective measure of the total antioxidant capacity of the sample. The assay has excellent precision values, which are lower than 3%. The results were expressed as mmol Trolox equivalent/L.

#### **Determination of TOS**

TOS was determined using a novel automated measurement method, developed by Erel [20]. Oxidants present in the sample oxidize the ferrous ion-*O*-dianisidine complex to ferric ion. The oxidation reaction is enhanced by glycerol molecules, which are abundantly present in the reaction medium. The ferric iron makes a colored complex with xylenol orange in an acidic medium. The color intensity, which can be measured spectrophotometrically, is related to the total amount of oxidant molecules present in the sample. The assay was calibrated with hydrogen peroxide and the results were expressed in terms of  $\mu$ mol  $H_2O_2$  equivalent/L.

#### **Measurement of OSI**

The percent ratio of the TOS to TAC was accepted as the OSI, an indicator of the degree of oxidative stress [20]. OSI value was calculated from the following formula: OSI (arbitrary unit) = TOS/TAC. The OSI value of the ileum samples was also calculated as an OSI (arbitrary unit).

### Electrophysiological analysis

The raw (unprocessed) signals, because of being very random, did not show any satisfactory indicators showing the effect of Dxp on the myoelectrical activity and consequently motility of the intestine of rats. The signals were filtered with a passband filter (0.5–48 Hz) to exclude both extremely low frequencies caused by mechanical movements of the rats and 50 Hz electric line frequency. With the filtered individual intestine electrical signals, it was not possible to make a sensible decision being common to all the subjects in the group. Then we decided to transfer these signals to frequency domain for the assessment of the spectral content of myoelectrical activity, in another point of view. A typical intestine's electrical signal and its spectrum from each group are shown in Figures 2 and 3, respectively. This individual signals showed that Dxp increased the electrical power of the signal. However, in order to achieve a valuable correlation between myoelectrical activity and the intestinal motility common to all subjects, these myoelectrical signals were further processed. Benefiting from the very common signal processing literature, a formula given by Equation (1) was developed to achieve an associative or a correlative spectrum (CS) among the members of the group. The process given by Equation (1) provides information regarding common rhythmic events emerging in the spectral content of intestine (Figure 4). This electrical activity can directly stimulate the intestinal muscles and hence cause intestinal motility. From this information, it can be deduced that (a) the highest power, the highest motility, and (b) the emergence of some spectral peaks in CS graphs show the regularity of motility

$$CS(f) = \left[ \prod_{n=1}^N s_n(t) \exp(-i2\pi ft) dt \right]^{\frac{1}{N}} \quad (1)$$

where  $N$  is the number of subjects employed in the experiment.

### Histological analysis

The preparations were stained by HE and evaluated by a blinded pathologist under light microscope. Mucosal changes induced by ischemia were rated by a pathologist according to the classification system described by Chiu et al. [21] as follows:

Grade 0: Normal mucosa.

Grade 1: Subepithelial spaces at villus top due to capillary congestion.

Grade 2: Expansion of subepithelial space with moderate lifting of epithelial layer.

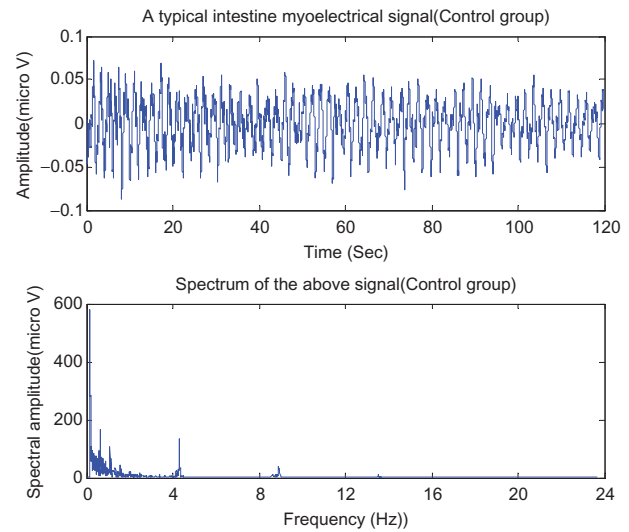


Figure 2. A typical intestine signal and its spectrum (control group).

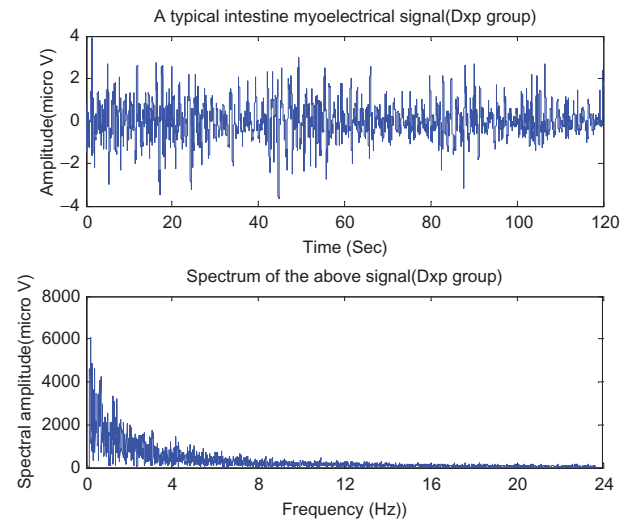


Figure 3. A typical intestine signal and its spectrum (Dxp group).

Grade 3: Massive epithelial detachment with a few destructed villi.

Grade 4: Destructed villi with dilated capillaries.

Grade 5: Disintegration of lamina propria, ulceration, and hemorrhage.

The expression of caspase-3 was assessed as follows: no expression, 0; minimal expression (0–25% involvement), 1; moderate expression (26–50% involvement), 2; and severe expression (more than 50% involvement), 3. For this analysis, 10 fields were examined in  $\times 20$  objective magnification. All sections were evaluated using a Leica DFC280 light microscope and a Leica Q Win Image Analysis system (Leica Micros Imaging Solutions Ltd., Cambridge, UK).

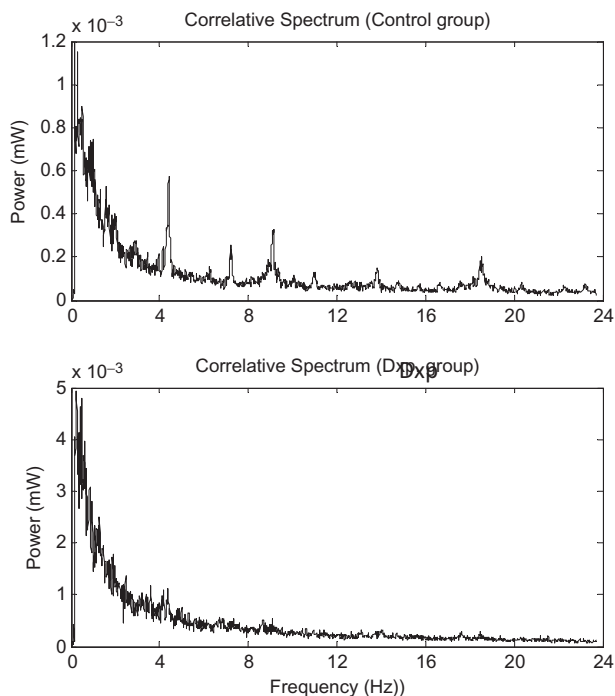


Figure 4. The correlative spectrum for the control and the Dxp groups.

### Statistical analysis

The data were expressed as either median (min–max) values or mean  $\pm$  standard deviation (SD) depending on the overall variable distribution. Normality was assessed using the Shapiro–Wilk test. The normally distributed data were analyzed by one-way ANOVA followed by the Tukey *post-hoc* test. The non-normally distributed data were compared by the Kruskal–Wallis H test among the groups. When significant differences were determined, multiple comparisons were carried out using the Mann–Whitney *U* test with Bonferroni correction.  $p < 0.05$  values were considered as significant IBM SPSS statistics version 22.0 (SPSS Inc., Chicago, IL) for Windows was used for statistical analyses.

## Results

### Biochemical results

Table I presents results of pro-oxidant and antioxidant biochemical markers measured from ileum samples. Briefly, it was found that there was significant increase in MDA levels in the I/R group when compared with the control group ( $p < 0.0001$ ). Also, a significant difference was found in MDA levels between the I/R and the Dxp plus I/R group ( $p < 0.05$ ). Significant differences were observed in SOD, CAT, and GPX levels between I/R and control groups ( $p < 0.001$ ,  $p < 0.001$ , and  $p < 0.001$ , respectively). When Dxp plus I/R and I/R plus Dxp

groups were compared, insignificant improvements were observed in these parameters. However, there are not differences proved by statistical analyses (Table I). When I/R and control groups were compared in terms of GSH, TOS, TAC, and OSI levels, it was seen that there was significant difference in GSH, TAC, and OSI levels ( $p < 0.05$ ,  $p < 0.026$ , and  $p < 0.05$ , respectively) but not in TOS levels.

When the I/R group was compared with Dxp plus I/R and I/R plus Dxp groups in terms of GSH, TOS, TAC, and OSI levels, it was seen that there were significant differences in TAC and OSI levels but not in GSH and TOS levels ( $p < 0.05$ ,  $p < 0.05$ ,  $p < 0.05$ , and  $p < 0.05$ ). There were no significant differences between Dxp plus I/R and I/R plus Dxp groups ( $p > 0.05$ , Table I).

When I/R and control groups were compared in terms of ALT, AST, CK, and LDH levels, it was seen that there was a significant difference in AST, CK, and LDH levels ( $p < 0.01$ ,  $p < 0.01$ , and  $p < 0.01$ , respectively) but not in the ALT level. When the I/R group was compared with Dxp plus I/R and I/R plus Dxp groups, the only significant difference was observed in LDH levels (Table II).

### Electrophysiological results

From the electrophysiological point of view, both temporal and spectral signals given in Figures 2 and 3 as well as the correlative spectrum (CS) shown in Figure 4 demonstrated that Dxp increased the total spectral electrical power delivered by the intestines. As can be seen from these figures that while temporal intestine electrical activity for the control group fluctuates between  $+0.05$  and  $-0.05 \mu\text{V}$ , electrical activity for the Dxp group fluctuates almost between  $+2$  and  $-2 \mu\text{V}$ . That is, the signal's voltage (in average) increases from 0.05 to 2 with the administration of Dxp. Similarly, the CS spectral signals showed that with Dxp treatment signal power peaks to 3.4 mW which was only 1.2 mW for the control group. This can mean that an increase in electrical activity of intestine, which we consider to cause an increase in the motility of the intestine, occurs with Dxp treatment. For the control group, it was observed that Dxp also caused to diminish the distinguishable rhythmic electrical events, which are occurred in the format of several successive small peaks in CS of the control group, as shown in Figure 3 (the upper pattern). This result can mean that with the Dxp treatment the intestine experiences an unformatted (no spectral successive peaks) high electrical stress which may cause unformatted (no rhythmic events) high motility in the intestine.

Table I. Ileum oxidant and antioxidant parameters levels in different groups.

Groups (n = 8)	MDA(nmol/g tissue, median (min-max))	SOD(U/mg protein), median (min-max)	CAT(k/g protein), median (min-max)	GPX (U/g protein), median (min-max)	GSH (μmol/g tissue), median (min-max)	TOS (μmol/g tissue), median (min-max)	TAC (trolax Eq/L), median (min-max)	OSI (arbitrary unit), median (min-max)
Control	7.05 (5.62-7.59)	0.78 (0.67-0.86)	2.68 (2.46-3.88)	269.22 (218.67-322.18)	4.67 (3.30-5.74)	1.94 (1.13-2.24)	1.08 (0.91-1.44)	1.538 (1.045-2.053)
I/R	40.91 (30.99-52.59)*	0.21 (0.13-0.63)*	1.50 (1.22-1.87)*	139.97 (91.54-199.60)*	3.18 (2.52-5.20)*	2.22 (1.94-4.27)	0.63 (0.40-1.00)*	4.33 (6.78-1.43)*
Dxp + I/R	8.60 (6.55-9.62)**	0.72 (0.62-0.78)**	2.40 (1.96-3.88)**	243.19 (182.34-290.17)**	4.23 (3.88-5.12)	1.78 (1.13-2.80)	1.18 (0.76-1.87)**	1.43 (0.84-2.56)**
I/R + Dxp	7.81 (7.10-10.88)**	0.70 (0.46-0.83)**	2.83 (1.03-3.77)**	233.37 (200.94-300.03)**	4.55 (3.52-5.35)	1.79 (1.11-2.50)	1.12 (0.85-1.87)**	1.63 (0.84-2.86)**
p Value	<0.001	<0.001	<0.001	<0.001	<0.05	>0.05	<0.001	<0.001

I/R, ischemia-reperfusion; Dxp, dexpanthenol.

\*p &lt; 0.05 versus the control group, \*\*p &lt; 0.05 versus the I/R group.

## Histological results

In histopathological examination, grade 2-5 morphological changes were observed in the I/R group while grade 1-3 changes were observed in the Dxp plus I/R group. In addition, grade 1 and 2 changes were observed in the I/R plus Dxp group. Higher grades of ischemic intestinal injury was observed in the Dxp plus I/R group when compared with the I/R plus Dxp group but lower grades were observed when compared with the I/R group (Table III and Figure 5).

It was observed that, on one hand, the caspase 3 expression was minimum in the tissue sections of the rats in the control groups, whereas it was increased in the sections of IR in the surface epithelial cells (Figure 6A). Additionally, caspase 3 expression was recognized in the gland cells in these groups (Figure 6B). On the other hand, caspase 3 expression was reduced in Dxp administrated groups (Figure 6C and D). However, significant differences were not found between the Dxp + IR and the IR + Dxp group in terms of caspase 3 expression. The amount of caspase 3 expression measured in each group is given in Table III.

## Discussion

The incidence of intestinal ischemia is 8.6:100,000 people in general population while it is 1-2:1000 cases among hospitalized patients [22]. In humans, diagnosis of mesenteric ischemia is delayed due to the lack of specific and functional markers that may consent to early detection. Despite advances in medicine, mesenteric ischemia has no specific therapy [23] and its management remains to be challenging. Previously, many drugs have been studied as regard treatment [23].

In addition, many antioxidant and anti-inflammatory agents have been tested in mesenteric I/R experimental studies with the hope for a novel perspective [24]. For this purpose, we tested Dxp in the mesenteric I/R model induced by clamping superior mesenteric artery.

In the present study, it was confirmed that MDA was increased in intestinal tissue due to I/R when compared with the control group. MDA is one of the most significant markers of oxidative stress, and it is increased through lipid peroxidation. It is suggested that the primary mechanism underlying tissue damage is lipid peroxidation regardless of ROS source. Therefore, blocking lipid peroxidation can be a basic strategy in order to prevent tissue injury. A marked reduction was observed in MDA levels when Dxp was given before or after I/R. This finding suggests that Dxp decreased I/R-related harmful effects, and thus oxidative stress (Table I). When Dxp given at the end of ischemia period was compared

**Table II.** The serum biochemical parameters among the different groups.

Groups (n = 8)	ALT (U/L), median (min–max)	AST (U/L), median (min–max)	LDH (U/L), median (min–max)	CK(U/L), median (min–max)
Control	50.0 (35.00–91.00)	106.50 (82.00–172.00)	1222.00 (869.00–1506.00)	1545.00 (1188.00–1620.00)
I/R	62.50 (32.00–103.00)	284.50 (145.00–416.00)*	2035.50 (1276.00–3082.00)*	4249.50 (1328.00–9647.00)*
Dxp + I/R	46.00 (38.00–100.00)	197.00 (144.00–369.00)*	1337.50 (1046.00–2401.00)	2227.00 (1504.00–3343.00)*
I/R + Dxp	50.50 (39.00–70.00)	176.50 (132.00–274.00)*	1253.50 (985.00–1751.00)**	2752.50 (1892.00–4204.00)*
p Value	<0.674	<0.003	<0.003	<0.004

I/R, ischemia–reperfusion; Dxp, dexpanthenol; ALT, alanine aminotransferase; AST, aspartate aminotransferase; LDH, lactate dehydrogenase; CK, creatine kinase. \* $p < 0.05$  versus the control group, \*\* $p < 0.05$  versus the I/R group.

**Table III.** Histopathological scores of the different groups.

Groups (n = 8)	Grade 0	Grade 1	Grade 2	Grade 3	Grade 4	Grade 5	Caspase 3
Control	8/8	–	–	–	–	–	0.83 ± 0.53
IR	–	–	2/8	2/8	2/8	2/8	2.23 ± 0.68 <sup>a</sup>
Dxp + IR	–	3/8	2/8	3/8	–	–	1.17 ± 0.70 <sup>b</sup>
IR + Dxp	–	4/8	4/8	–	–	–	1.50 ± 0.57 <sup>b</sup>

<sup>a</sup>Statistically significant increase when compared with the control group ( $p = 0.000$ ).

<sup>b</sup>Statistically significant decrease when compared with the IR group ( $p = 0.000$ ).

with the Dxp plus I/R group, it was seen that extent of MDA reduction was higher. However, the difference did not reach statistical significant. Our findings are in agreement with the results of the study by Etensel et al. [25] who reported increased lipid peroxidation in testicular I/R injury.

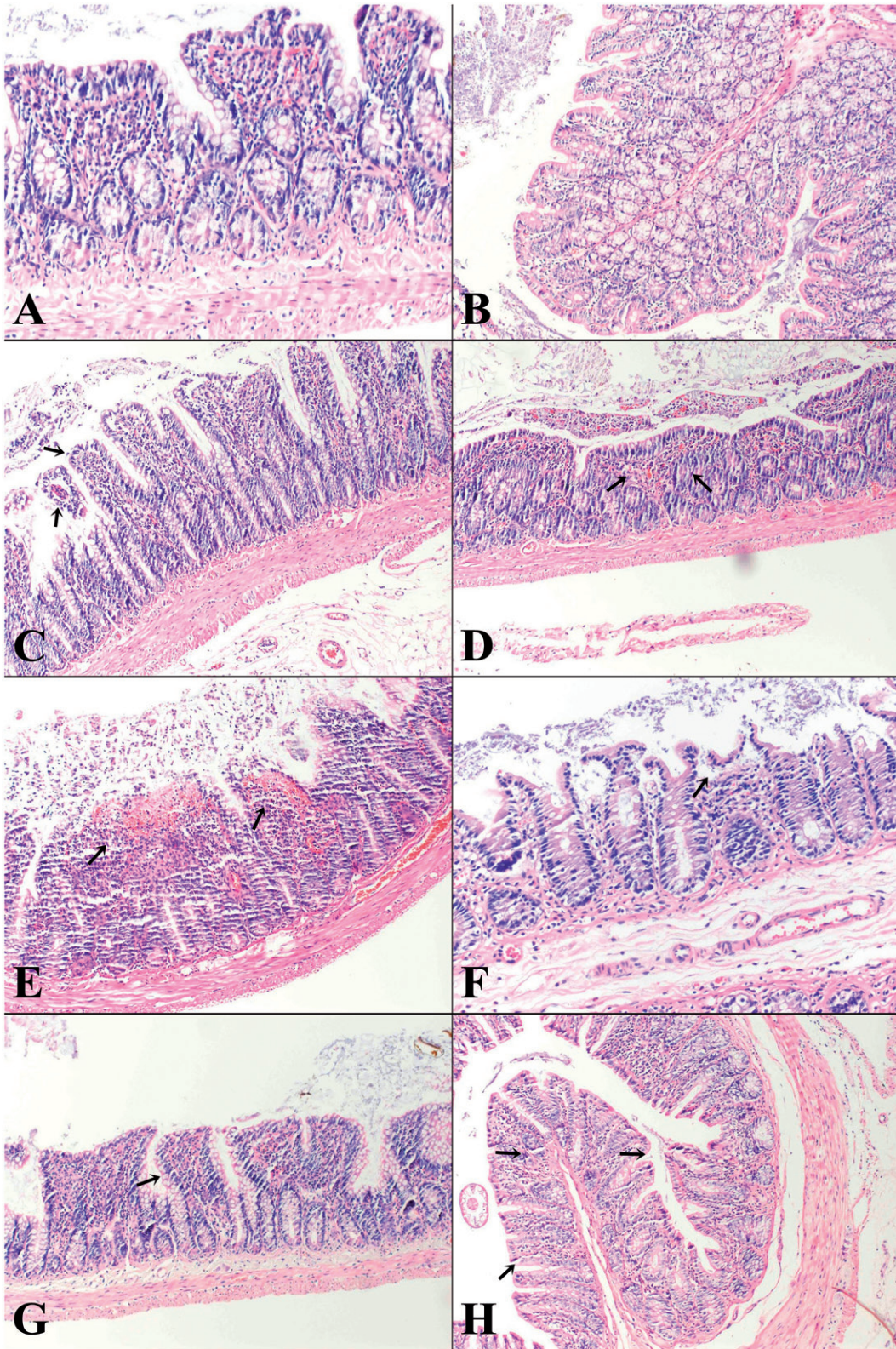
When the I/R group was compared with the control group, a significant decrease was observed in SOD and CAT levels. The elevated levels of these enzymes protect intestinal mucosa during I/R [26]. In the previous studies, it was reported that SOD and CAT levels are changed due to altered mRNA levels during I/R [27]. When the groups given Dxp before and after ischemia period were compared with the I/R group, it was seen that there were marked increases in SOD and CAT levels.

GSH cycle is the most important intracellular antioxidant defense mechanism. It maintains cell integrity and cellular metabolism. It is also used as a substrate for activities of several antioxidant enzymes such as GPX [27,28]. In the present study, it was observed that intestinal I/R caused reduction in GSH and GPX levels. When groups given Dxp were compared with the I/R group, it was seen that there were marked increases in GSH and GPX levels. The increase of GPX was higher in the Dxp plus I/R group, whereas the increase of GSH was higher in the I/R plus Dxp group. However, there was no significant difference in the extent of GSH and GPX levels between groups given Dxp. Again, in the study by Sylshenkov et al. [29], it was confirmed that Dxp inhibits ROS production and exerts antioxidant activity in liver tissue. Also, our findings are in agreement with studies by Marzacco et al. [30] and Omar et al. [31] who showed increased oxidative stress together with decreased enzymatic and non-enzymatic antioxidant levels.

As a result, Dxp is an alcohol analogue of PA. PA is the precursor of CoA. PA translates to CoA by several enzymes in the hepatocyte. CoA is a molecule essential for enzymatic reactions in mitochondria. CoA is also required for both the oxidation of fatty acids and cholesterol, fatty acid biosynthesis. The excess cellular CoA collection is precluded by a feedback inhibition by pantothenate kinase [32]. It was shown that PA increased hepatic GSH levels in cells [33]. Therefore, the cytoprotective effect of PA likely increased due to CoA and GSH levels.

In the present study, OSI level was increased while TAC level was decreased in the I/R group, when compared with the control group. There is no statistical significance between control and I/R groups in terms of TOS levels. In fact, we could not explain it clearly. However, there are some reports [34–36] in the literature supporting our results. One of the explanations of this result may be that although in individual oxidant parameters such as MDA end product of lipid peroxidation is changed, the total oxidant status could not be changed. However, significant decrease was observed in TOS and OSI levels while no significant increase was observed in TAC level in groups given Dxp, when compared with the I/R group. This finding demonstrated that I/R increased oxidative stress while Dxp decreased oxidative stress [29].

In addition, it was seen that serum ALT, LDH, AST, and CK levels were increased in the I/R group. It is known that serum ALT, AST, LDH, and CK levels are increased in acute mesenteric ischemia but these increases are not specific to acute mesenteric ischemia. It may occur at late phase where intestinal necrosis occurs [37,38]. It was seen that these parameters were



**Figure 5.** (A) and (B) normal intestinal mucosa in the control group (H&E,  $\times 100$ ,  $\times 200$ ); (C) subepithelial lifting (grade 2) in the I/R group (H&E,  $\times 100$ ) (arrows); (D) destroyed villi with dilated capillaries (grade 4) in the I/R group (H&E,  $\times 100$ ) (arrows); (E) disintegration of lamina propria, ulceration, and hemorrhage (grade 5) in the I/R group (H&E,  $\times 100$ ) (arrows); (F) expansion of subepithelial space with moderate lifting of epithelial layer (grade 2) in the Dxp plus I/R group (H&E,  $\times 200$ ) (arrows); (G) almost normal intestinal mucosa (grades 0 and 1) in the I/R plus Dxp group (H&E,  $\times 100$ ) (arrow); (H) almost normal intestinal mucosa in the I/R plus Dxp group (H&E,  $\times 100$ ) (arrows).

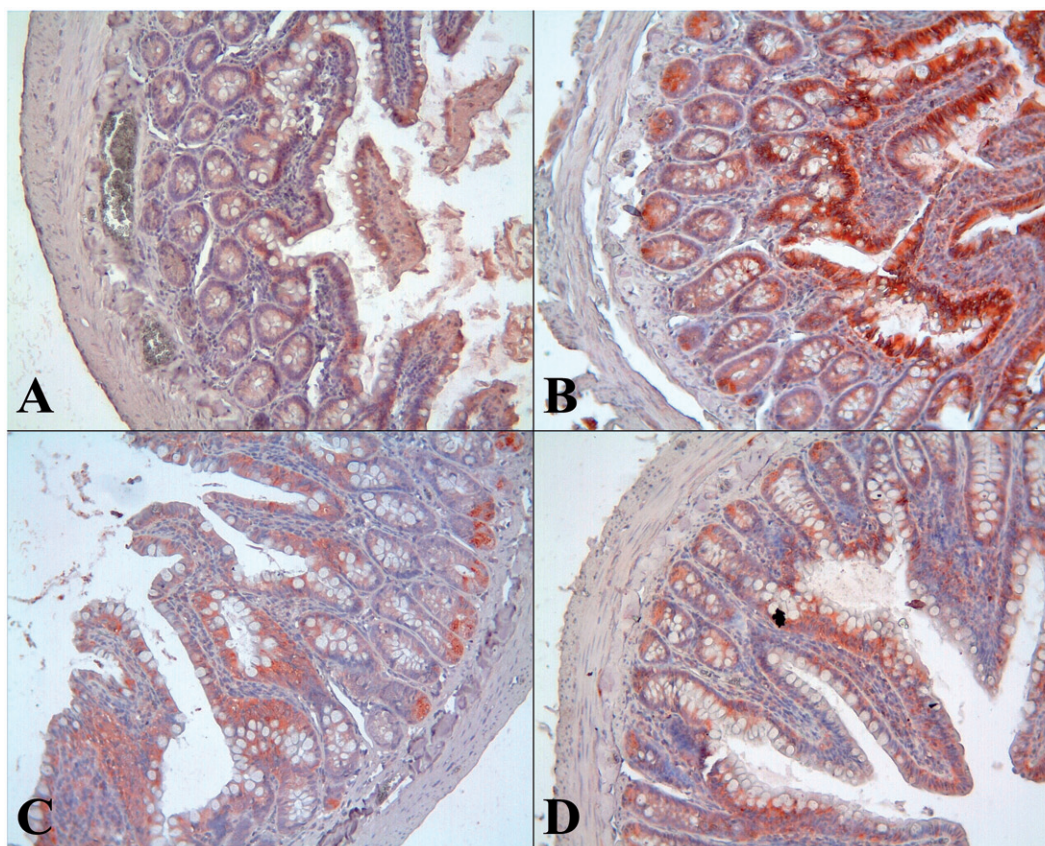


Figure 6. Caspase 3 expression for each group. (A) Control group, (B) I/R group, (C) Dxp + I/R group ( $\times 20$ ), and (D) I/R + Dxp group.

decreased in groups given Dxp, when compared with the I/R group. However, only significant difference was observed in the LDH level in I/R plus Dxp.

In histopathological examination, grade 2–5 lesions were noted in the I/R group. This finding was in parallel to biochemical parameters, supporting oxidative stress. Grade 1–3 lesions were observed in the Dxp plus I/R group whereas grades 1 and 2 lesion in the I/R plus Dxp group. It emphasizes that Dxp significantly improved or prevented ischemic intestinal injury. In the Dxp plus I/R group, there were higher grades of ischemic intestinal injury when compared with the I/R plus Dxp group. However, ischemic intestinal injury in this group was less severe when compared with the I/R group. In the studies by Kuenzler et al. [39] and Jacob et al. [40], the role of apoptosis was shown in the development of intestinal injury. In our study, we assessed apoptosis by caspase-3 activity. Markedly increased caspase-3 activity in the I/R group compared with control group and significant decrease in Dxp plus I/R and I/R plus Dxp groups compared with the I/R group can be interpreted that Dxp has anti-apoptotic and protective effects. The histopathological and biochemical results found in this study were consistent.

As mentioned earlier, the effect of Dxp on intestine motility was searched through the electrical activity of intestines recorded for half an hour after the administration of Dxp. It was considered that after Dxp treatment, intestinal colic might do happen. Patients with intestinal colic usually complain for blockage of air bubbles as not able to pass. An episode of intestinal colic can start with a sensation of sharp twiggling in the abdomen [41]. Such complaints may be systematically linked with the increase of intestinal unformatted electrical signal's power mentioned before. Another issue is the effect of Dxp on the obstruction of the intestine due to paralysis of the intestinal muscles, the so-called paralytic ileus [42,43]. The obtained electrophysiological result showed that Dxp may cause an increase in electrical power (Figure 4), and consequently increase in voluntary muscular power. Interestingly, Demirci et al. have shown that Dxp improves diabetic cardiovascular function and cardiac performance by regulating total oxidant and antioxidant status [44]. This verdict may also be explained within the context of the increase of myoelectrical power within the vascular system due to Dxp intake.

In our study, we assessed physiological roles of Dxp on the GIS, such as contraction. Markedly increased

electrical signal activity in the Dxp group compared with the control group. Hereof, there are different results in various studies [41–43]. However, the results of the study by Hanck et al. confirm our consequences [41].

## Conclusion

Dxp was proven to decrease oxidation, while enhancing motility in the intestine and antioxidant system. Also Dxp is inexpensive, safe, and available. Therefore, we believe that it can be used as a treatment option in acute mesenteric ischemia and constipation. However, this subject needs further research to make a robust decision for using Dxp in routine treatments.

## Declaration of interest

The authors have no conflicts of interest to disclose.

## References

- [1] Takeyoshi I, Zhang S, Nakamura K, Ikoma A, Zhu Y, Starzl TE, Todo S. Effect of ischemia on the canine large bowel: a comparison with the small intestine. *J Surg Res* 1996;62:41.
- [2] Sasaki M, Joh T. Oxidative stress and ischemia–reperfusion injury in gastrointestinal tract and antioxidant, protective agents. *J Clin Biochem Nutr* 2007;40:1.
- [3] Schneider TA, Longo WE, Ure T, Vernava IIIAM. Mesenteric ischemia. *Dis Colon Rectum* 1994;37:1163–1174.
- [4] Granger D, Höllwarth M, Parks D. Ischemia–reperfusion injury: role of oxygen-derived free radicals. *Acta Physiologica Scand Suppl* 1986;548:47.
- [5] Sağrıoğlu T, Oğuz S, Sağrıoğlu G, Çopuroğlu E, Yalta T, Sayhan MB, Yağcı MA. The effects of apelin on mesenteric ischemia and reperfusion damage in an experimental rat model. *Balkan Med J* 2012;29:148.
- [6] Grace P. Ischaemia–reperfusion injury. *Br J Surg* 1994;81:637–647.
- [7] De Groot H, Rauen U. Ischemia–reperfusion injury: processes in pathogenetic networks: a review. *New York: Elsevier*; 2007:481–484.
- [8] Shah KA, Shurey S, Green CJ. Apoptosis after intestinal ischemia–reperfusion injury: a morphological study. *Transplantation* 1997;64:1393–1397.
- [9] Ermis H, Parlakpınar H, Gulbas G, Vardi N, Polat A, Cetin A, et al. Protective effect of dexpanthenol on bleomycin-induced pulmonary fibrosis in rats. *Naunyn-Schmiedeberg's Arch Pharmacol* 2013;386:1103–1110.
- [10] Akdeniz Y, Tarhan OR, Barut İ. Can dexpanthenol prevent peritoneal adhesion formation? An experimental study. *TJTES* 2007;13:94–100.
- [11] Slyshenkov VS, Omelyanchik SN, Moiseenok AG, Trebukhina RV, Wojtczak L. Pantothenol protects rats against some deleterious effects of gamma radiation. *Free Radic Biol Med* 1998;24:894–899.
- [12] Ceylan H, Yapici S, Tutar E, Ceylan NO, Tarakçıoğlu M, Demiryurek AT. Protective effects of dexpanthenol and y-27632 on stricture formation in a rat model of caustic esophageal injury. *J Surg Res* 2011;171:517–523.
- [13] Slyshenkov VS, Piwocka K, Sikora E, Wojtczak L. Pantothenic acid protects jurkat cells against ultraviolet light-induced apoptosis. *Free Radic Biol Med* 2001;30:1303–1310.
- [14] Uchiyama M, Mihara M. Determination of malonaldehyde precursor in tissues by thiobarbituric acid test. *Anal Biochem* 1978;86:271–278.
- [15] Lowry OH, Rosebrough NJ, Farr AL, Randall RJ. Protein measurement with the Folin phenol reagent. *J Biol Chem* 1951;193:265–275.
- [16] Sun Y, Oberley LW, Li Y. A simple method for clinical assay of superoxide dismutase. *Clin Chem* 1988;34:497–500.
- [17] Aebi H, Suter H. Catalase. In: *Methods of enzymatic analysis*. 1969;77:325.
- [18] Paglia DE, Valentine WN. Studies on the quantitative and qualitative characterization of erythrocyte glutathione peroxidase. *J Lab Clin Med* 1967;70:158–169.
- [19] Ellman GL. Tissue sulfhydryl groups. *Arch Biochem Biophys* 1959;82:70–77.
- [20] Erel O. A novel automated method to measure total antioxidant response against potent free radical reactions. *Clin Biochem* 2004;37:112–119.
- [21] Chiu C-J, Mc Ardle AH, Brown R, Scott HJ, Gurd FN. Intestinal mucosal lesion in low-flowstates. I. A morphological, hemodynamic, and metabolic reappraisal. *Arch Surg* 1970;101:478–483.
- [22] Acosta S, Ögren M, Sternby N-H, Bergqvist D, Björck M. Incidence of acute thrombo-embolic occlusion of the superior mesenteric artery – a population-based study. *Eur J Vasc Endovasc Surg* 2004;27:145–150.
- [23] Lauterbach M, Horstick G, Plum N, Lotz J, Lauterbach E, Weilemann LS, Kempinski O. C1-esterase inhibitor reverses functional consequences of superior mesenteric artery ischemia/reperfusion by limiting reperfusion injury and restoring microcirculatory perfusion. *Shock* 2007;27:75–83.
- [24] Chatterjee PK. Novel pharmacological approaches to the treatment of renal ischemia–reperfusion injury: a comprehensive review. *Naunyn-Schmiedeberg's Arch Pharmacol* 2007;376:1–43.
- [25] Etensel B, Özkısacık S, Özkara E, Karul A, Öztan O, Gürsoy H. Dexpanthenol attenuates lipid peroxidation and testicular damage at experimental ischemia and reperfusion injury. *Pediatr Surg Int* 2007;23:177–181.
- [26] Parlakpınar H, Olmez E, Acet A, Ozturk F, Tasdemir S, Ates B, et al. Beneficial effects of apricot-feeding on myocardial ischemia–reperfusion injury in rats. *Food Chem Toxicol* 2009;47:802–808.
- [27] El Daly E. Protective effect of cysteine and vitamin E, *Crocus sativus* and *Nigella sativa* extracts on cisplatin-induced toxicity in rats. *J Pharm Belgique* 1997;53:87–93. discussion 93–95.
- [28] Özyurt H, Yıldırım Z, Kotuk M, Yılmaz HR, Yağmurca M, Iraz M, et al. Cisplatin-induced acute renal failure is ameliorated by erdoesteine in a dose-dependent manner. *J Appl Toxicol* 2004;24:269–275.
- [29] Slyshenkov VS, Dymkowska D, Wojtczak L. Pantothenic acid and pantothenol increase biosynthesis of glutathione by boosting cell energetics. *FEBS Lett* 2004;569:169–172.

- [30] Marzocco S, Di Paola R, Autore G, Mazzon E, Pinto A, Caputi AP, et al. Calpain inhibitor I reduces intestinal ischemia–reperfusion injury in the rat. *Shock* 2004;21:38–44.
- [31] Omar HE-DM, Ahmed EA, Abdel-Ghafar S, Mohammed S, Nasser AY. Hepatoprotective effects of vitamin C, DPPD, and L-cysteine against cisplatin-induced oxidative stress in male rats. *J Biol Earth Sci* 2012;2:B28–B36.
- [32] Depeint F, Bruce WR, Shangari N, Mehta R, O'Brien PJ. Mitochondrial function and toxicity: role of the B vitamin family on mitochondrial energy metabolism. *Chem-Biol Interact* 2006;163:94–112.
- [33] Wojtczak L, Slyshenkov VS. Protection by pantothenic acid against apoptosis and cell damage by oxygen free radicals – the role of glutathione. *Biofactors* 2003;17:61–73.
- [34] Koksal M, Oğuz E, Baba F, Eren MA, Ciftci H, Demir M, et al. Effects of melatonin on testis histology, oxidative stress and spermatogenesis after experimental testis ischemia–reperfusion in rats. *Eur Rev Med Pharmacol Sci* 2012;16:582–588.
- [35] Koruk S, Mizrak A, Kaya R, Ugur B, Cebesoy O, Celik A, Oner U. The effects of dexmedetomidine on ischemia reperfusion injury in patients undergoing arthroscopy under spinal anesthesia. *Eurasian J Med* 2010;42:137.
- [36] Yildiz F, Coban S, Terzi A, Savas M, Bitiren M, Celik H, Aksoy N. Protective effects of *Nigella sativa* against ischemia–reperfusion injury of kidneys. *Renal Fail* 2010;32:126–131.
- [37] Meyer T, Klein P, Schweiger H, Lang W. How can the prognosis of acute mesenteric artery ischemia be improved? Results of a retrospective analysis. *Zentralbl Chir* 1997;123:230–234.
- [38] Uncu H, Uncu G, İlçöl Y, Aker Y. Diagnosis of intestinal ischemia by measurement of serum phosphate and enzyme changes and the effectiveness of vitamin E treatment. *Turk J Gastroenterol* 1999;10:272–275.
- [39] Kuenzler KA, Pearson PY, Schwartz MZ. IL-11 pretreatment reduces cell death after intestinal ischemia–reperfusion. *J Surg Res* 2002;108:268–272.
- [40] Jacob T, Ascher E, Hingorani A, Kallakuri S. Glycine prevents the induction of apoptosis attributed to mesenteric ischemia/reperfusion injury in a rat model. *Surgery* 2003;134:457–466.
- [41] Hanck A, Goffin H. Dexpanthenol (Ro 01-4709) in the treatment of constipation. *Acta Vitaminol Enzymol* 1981;4:87–97.
- [42] Polacek M, Close A, Ellison E. Double-blind study of the effect of d-pantothenyl alcohol on experimental postoperative ileus. *Surg Forum* 1959;11:325–327.
- [43] Watne AL, Mendoza C, Rosen R, Nadler S, Case R. The role of dexpanthenol in postoperative ileus. *JAMA* 1962;181:827–830.
- [44] Demirci B, Demir O, Dost T, Birincioglu M. Protective effect of vitamin B5 (dexpanthenol) on cardiovascular damage induced by streptozocin in rats. *Bratisl Med J – Bratisl Lekarske Listy* 2014;115:190–196.