

Choosing the appropriate side for subcutaneous port catheter placement in patients with mastectomy: ipsilateral or contralateral?

Omer Fatih Nas¹ · Kadir Hacikurt² · Ahmet Kaya¹ · Nurullah Dogan³ · Bekir Sanal⁴ · Guven Ozkaya⁵ · Halit Ziya Dundar⁶ · Cuneyt Erdogan¹

Received: 5 August 2016 / Accepted: 31 January 2017 / Published online: 17 February 2017
© Italian Society of Medical Radiology 2017

Abstract

Purpose To evaluate long-term clinical follow-up results of implanting subcutaneous port catheters (SPCs) on ipsilateral or contralateral with mastectomy side in patients with axillary lymph node dissection.

Methods A total of 73 patients composed of ipsilateral (34 catheters) and contralateral (39 catheters) groups, with SPCs were included. All patients had lumpectomy or modified radical mastectomy for breast cancer. Ipsilateral and contralateral groups had similar patient characteristics.

Results Five late complications were seen in the ipsilateral group and 2 late complications in the contralateral group. No statistical significant difference was seen between two groups in regard to late complications. Four complications of the ipsilateral group were classified as major group C and 1 as major group D, while 1 complication of the contralateral group was classified as minor group B and 1 as major group C according to Society of Interventional Radiology (SIR) classification. No statistical significant

difference was seen between complication rates of two groups in regard to SIR classification.

Conclusions SPC related complications do not differ in regard to ipsilateral or contralateral side selection on mastectomized patients with breast cancer and lymph node dissection. SPCs can be implanted on ipsilateral or contralateral sides of the operation in these patients.

Keywords Breast cancer · Contralateral · Ipsilateral · Society of interventional radiology · Subcutaneous port catheter

Introduction

Subcutaneous port catheters (SPCs) have become an increasingly used technique in the treatment of oncology patients. It is used not only for chemotherapy but also for parenteral nutrition, blood transfusion, intravenous (i.v.)

✉ Omer Fatih Nas
omerfatihnas@gmail.com

Kadir Hacikurt
hacikurt@gmail.com

Ahmet Kaya
ahmetkaya.md@gmail.com

Nurullah Dogan
drndogan@gmail.com

Bekir Sanal
bekir.sanal@gmail.com

Guven Ozkaya
ozkaya@uludag.edu.tr

Halit Ziya Dundar
hzdundar@hotmail.com

Cuneyt Erdogan
cerdogan@uludag.edu.tr

¹ Department of Radiology, Uludag University Faculty of Medicine, Bursa, Turkey

² Radiology Clinic, Samandag State Hospital, Hatay, Turkey

³ Radiology Clinic, Doruk Medical Center, Bursa, Turkey

⁴ Department of Radiology, Dumlupınar University Faculty of Medicine, Kutahya, Turkey

⁵ Department of Biostatistics, Uludag University Faculty of Medicine, Bursa, Turkey

⁶ Department of General Surgery, Uludag University Faculty of Medicine, Bursa, Turkey

medication and hemodialysis [1]. Venous access during SPC implantation can be challenging in oncology patients, especially in patients with history of breast cancer surgery and/or radiotherapy (RT) [2].

Lymphedema can develop on ipsilateral upper extremity in patients with the history of modified radical mastectomy (MRM) or lumpectomy and lymph node dissection. Radiation can lead to lymphedema by making obstruction and/or fibrosis in the lymphatic system [2, 3]. Although a scientific proof is not present, general opinion is to avoid all venous interventions (from a simple intravenous cannulation to SPC implantation) in the ipsilateral extremity that lymph node dissection has been done. However, there are studies reporting normal complication rates in cases with chest SPCs implanted ipsilateral to lymph node dissection side [2]. Lymphatic drainage can be made partially through alternative ways like internal mammarian nodes in patients with mastectomy and lymph node dissection [2].

The aim of this study is to evaluate long-term clinical follow-up results and complication rates of implanting SPCs on ipsilateral or contralateral side of the chest with mastectomy side in patients with axillary lymph node dissection.

Materials and methods

Protocol

Inclusion criteria for patients were: female gender, history of breast surgery for breast cancer and eligible for the port implantation procedure (international normalized ratio [INR] below 1.5, platelet count higher than 75,000/mm³ and good performance status). SPCs were implanted to 73 patients with breast cancer in our department between March 2012 and September 2014, of which 34 were on the ipsilateral and 39 were on the contralateral side with the operation. Follow-up period of catheters was March 2012–May 2015. The indication for SPC implantation was chemotherapy (CT). All of the patients were women and have been treated with breast-sparing surgery (lumpectomy) or MRM and lymph node dissection.

Patients were divided into two groups: ipsilateral group (34 patients) and contralateral group (39 patients). Two groups were evaluated in regard to SPC indication: procedure details, lymph node dissection history, the nature of CT (palliative or curative), patient location (inpatient vs. outpatient), malfunction (partial or complete catheter blockage) per 100 catheter days, revision per access site/per 100 catheter days, subtypes of breast cancer, port side (right or left), the period that port was implanted (pre- or post-operative), the kind of operation (lumpectomy or MRM), the reason of port removal (complication or end

of therapy), presence of edema in the extremity with the port, late complications, complications classified according to Society of Interventional Radiology (SIR), infections per 1000 catheter days and total access site service interval. Classification of complications according to SIR criteria was: minor complications, (A) No therapy, no consequence, (B) Required nominal therapy, no consequence; included overnight admission for observation; major complications, (C) Required therapy, minor hospitalization (<48 h), (D) Required major therapy, unplanned increase in level of care, prolonged hospitalization (>48 h), (E) Permanent adverse sequelae, (F) Death. Total access site service interval is the total number of catheter days at a single access site. Infections were defined under the light of SIR criteria (exit site infection, tunnel infection, etc.) [4]. The study was approved by local clinical research ethics committee.

Operative technique

Patients were informed about the procedure and informed consent was obtained. Complete blood count and bleeding tests were done before the procedure. Patients with an INR below 1.5 and platelet count higher than 75,000/mm³ were accepted eligible for the procedure. Six hours fasting was ensured before the procedure. Prophylactic antibiotherapy was not needed. Local anesthesia alone (Prilocaine 20 mg/mL, Citanest, AstraZeneca and lidocaine 20 mg/mL + epinephrine 0.025 mg/mL, Jetokain, Adeka) was adequate for the procedure in most of patients. However, i.v. sedoanalgesia (midazolam 0.03 mg/kg i.v. and/or fentanyl 1 µ/kg i.v.) was needed in patients who were anxious and/or with low pain threshold. SPCs were single lumen catheters and were implanted under the guidance of a monoplane, flat panel angiography unit (Artis Zee, Siemens, Erlangen, Germany) by an experienced interventional radiologist. Types and characteristic of SPCs used are given in Table 1.

Surgical skin cleansing was made by applying the antiseptic solution (povidone iodine 10%, Batticon, Adeka) to the operation side from mandibular level to lower border of the breast and middle axillary line under sterile conditions in the operation room. A single-wall puncture needle (18G) was introduced into the internal jugular vein under ultrasound (US) guidance. Local anesthesia was applied to the area between the vein and subcutaneous tissues, a 1 cm skin incision was made and subcutaneous tissues were dissected. Guidewire was introduced and peel away sheet was placed through this wire under fluoroscopy guidance. Port pocket was constituted by separating subcutaneous tissues thru the fascia with blunt dissection through a 3 cm subcutaneous incision upon the 2nd rib. Local anesthesia was made into the subcutaneous area between the port pocket to the venous entrance site for tunneling. The port catheter

Table 1 Types and characteristics of the implanted ports

Port	Catheter	Number of patients (ipsilateral group)	Number of patients (contralateral group)
Port-A-Cath II Low-profile (SIMS Deltec, St Paul, MN)	7.8 F, polyurethane	1	4
Pro-Fuse [®] CT Power Injectable Low Profile (MedCOMP [®] , Harleysville, PA)	8 F, polyurethane	13	16
INFU-KT [®] Titanium Standard Intravenous Access (FB Medical, France)	7.8 F, silicone	6	11
Polysite Adult Standard (Perouse Medical, France)	7.2 F, polyurethane	7	7
Polysite Adult Standard (Perouse Medical, France)	9.5 F, polyurethane	0	1
Focus Titanium & Polysulfone (Promecon GmbH, Germany)	10.5 F, polyurethane	7	0

was introduced into the tunnel by the help of a trocar and it was attached to the reservoir with locking technique. The length of catheter was modified to fit the distance between superior vena cava and right atrium under fluoroscopy guidance. The catheter was placed into the peel away sheath. Localization of the catheter and reservoir was controlled with fluoroscopy. Functionality of the SPC was controlled by injecting 100 U/mL heparinized saline through the port reservoir.

Patients were followed for 2 h after the procedure in the observation room in regard to hemorrhage and pneumothorax risk. Prophylactic antibiotherapy was not made because of obeying antisepsis and asepsis rules at the procedure. Patients were controlled and sutures were removed three days later. SPC was permitted to be used one week after the procedure.

Statistical analysis

All statistical analyses were performed with SPSS version 22.0. Shapiro–Wilk test was used as normalization test. Descriptive statistics were determined in terms of average \pm standard deviation or median (minimum–maximum). Categorical data was determined as frequency and percentage. Continuous variables were compared using Student *t* test for normal distributed data. Categorical variables were compared using Pearson's Chi-square test, Fisher's exact test and Fisher-Freeman-Halton test. The level of significance was determined to be $\alpha = 0.05$.

Results

Median ages of 34 patients in the ipsilateral group and 39 patients in the contralateral group was 47.3 (28–66 years) and 50 (34–68 years), respectively (Table 2). Mean follow-up period was 420 days (30–742) for the ipsilateral group and 531 days (130–1127) for the contralateral group. There was no statistical difference between two groups in regard to distribution of subtypes of breast cancer (Table 2). Group

characteristics similar in two groups were: evaluation was retrospective, SPC indication was CT, the nature of CT was curative, all patients were outpatient, lymph node dissection history was present in all patients, procedures were technically successful, SPCs were implanted under sterile conditions with full dressing in a single session, the procedure was made under fluoroscopy and US guidance, SPCs were controlled with heparinized saline injection after the procedure, complete wound closure was ensured, control fluoroscopic images were obtained, there was no malfunction per 100 catheter days and no revision per access site/per 100 catheter days. In control fluoroscopic images tips of catheters were seen to be in the superior vena cava-right atrium in all patients. Tumor was on the right breast in 31 patients (31/34; 91.2%), on the left in 3 patients (3/34; 8.8%) in the ipsilateral group. It was on the right breast in 5 (5/39; 12.8%) and on the left in 34 patients (34/39; 87.2%) in the contralateral group. No patient was lost in the follow-up period.

There were no statistical difference between two groups in regard to mean age, subtypes of breast cancer, port side (right or left), the period that port was implanted (pre- or post-operative), the kind of operation (lumpectomy or MRM), the reason of port removal (complication or end of therapy) and presence of edema in the extremity with the port ($p > 0.05$) (Table 2).

Late complications (>30 days) were seen in 5 patients of the ipsilateral group ([5/34; 14.7%]; venous thrombosis in 4 patients [4/34; 11.8%] and venous thrombosis together with infection in 1 patient [1/34; 2.9%]) and in 2 patients of the contralateral group ([2/39; 5.1%]; venous thrombosis in 1 [1/39; 2.6%] and catheter occlusion together with infection in 1 patient [1/39; 2.6%]). In ipsilateral group, thrombus was present in jugular vein of three patients (3/5), in vena cava superior and brachiocephalic vein of one patient (1/5) and in vena cava superior of one patient (1/5). In contralateral group, thrombus was present in jugular and brachiocephalic vein of one patient (1/2). There was no statistical difference between two groups in regard to late complications ($p = 0.240$).

Table 2 Parameters compared in ipsilateral and contralateral groups

	Ipsilateral group (<i>n</i> = 34)	Contralateral group (<i>n</i> = 39)	<i>p</i>
Mean age	47.3 (28–66 years)	50 (34–68 years)	0.226
Subtypes of breast cancer			0.450
Invasive ductal	28; 82.4%	36; 92.3%	
Invasive lobular	2; 5.9%	3; 7.7%	
Ductal carcinoma in situ	1; 2.9%	0	
Metaplastic carcinoma	1; 2.9%	0	
Mucinous carcinoma	1; 2.9%	0	
Invasive micropapillary carcinoma	1; 2.9%	0	
Side of the port catheter	Right: 31; 91.2% Left: 3; 8.8%	Right: 34; 87.2% Left: 5; 12.8%	0.716
The implantation period	Preoperative: 5; 14.7% Postoperative: 29; 85.3%	Preoperative: 10; 25.6% Postoperative: 29; 74.4%	0.249
Type of the operation	Lumpectomy: 28; 82.4% MRM: 6; 17.6%	Lumpectomy: 32; 82.1% MRM: 7; 17.9%	0.973
Reason of port removal	End of treatment: 12; 35.3% Complication: 5; 14.7%	End of treatment: 16; 41% Complication: 2; 5.1%	0.423
Presence of edema in the extremity with the port	1; 2.9%	0	0.466
Late complication	5; 14.7%	2; 5.1%	0.240
Complications according to SIR classification	Class C: 4; 11.8% Class D: 1; 2.9%	Class B: 1; 2.6% Class C: 1; 2.6%	0.140
Infections per 1000 catheter days (95% confidence interval)	0.066 (0.0169–0.37)	0.044 (0.0011–0.17)	0.773
Total access site service interval	30–742 days (441.7 ± 205.8)	130–1127 days (577 ± 229.7)	0.100

MRM modified radical mastectomy, SIR society of interventional radiology

No early complication (<30 days) has happened in both groups. Four of 5 major complications in the ipsilateral group were class C (venous thrombosis in 3 patients [3/34; 8.8%] and venous thrombosis together with infection in 1 patient [1/34; 2.9%]) and 1 was class D (venous thrombosis [1/34; 2.9%]). One of complications seen in the contralateral group was a class B minor complication (venous thrombosis [1/39; 2.6%]) and the other was a class C major complication (catheter occlusion together with infection [1/39; 2.6%]). There was no statistical difference between two groups in regard to complications according to SIR classification ($p = 0.140$) (Table 2). While in the ipsilateral group 3 of 5 complications were seen in ports sized less than 8F and 2 in ports sized 8F or higher, 3 of 5 complications were seen in polyurethane ports and 2 of 5 in silicone ports. These numbers for the contralateral group were: 2 of 2 in ports sized less than 8F and 2 of 2 in silicone ports. There were no statistical correlations between complication rates and dimensions/materials of catheters for the ipsilateral group ($p = 0.627$ and $p = 0.205$, respectively) and the contralateral group ($p = 0.495$ and $p = 0.074$, respectively). Case examples are shown in Figs. 1 and 2.

Catheter infection has happened in 1 patient in each group. Erythema, tenderness and induration on catheter exit site were present in both patients of two groups (exit site infection). Infection per 1000 days was 0.066 (0.0169–0.37) in the ipsilateral group and 0.044 (0.0011–0.17) in the contralateral group (95% confidence interval). There was no statistical difference between two groups in regard to infections per 1000 days ($p = 0.773$) (Table 2). “Total access site service interval” was used instead of “initial (primary) device service interval” because SPCs have not been revised in both groups. This interval was 30–742 days (mean ± SD 441.7 ± 205.8 days) in the ipsilateral group and 130–1127 days (577 ± 229.7 days) in the contralateral group. There was no statistical difference between two groups ($p = 0.100$) (Table 2).

Discussion

The aim of this study was to evaluate long-term effects and complication rates of implanting SPCs on ipsilateral or contralateral according to the operation side in patients with mastectomy and axillary lymph node dissection. SPCs

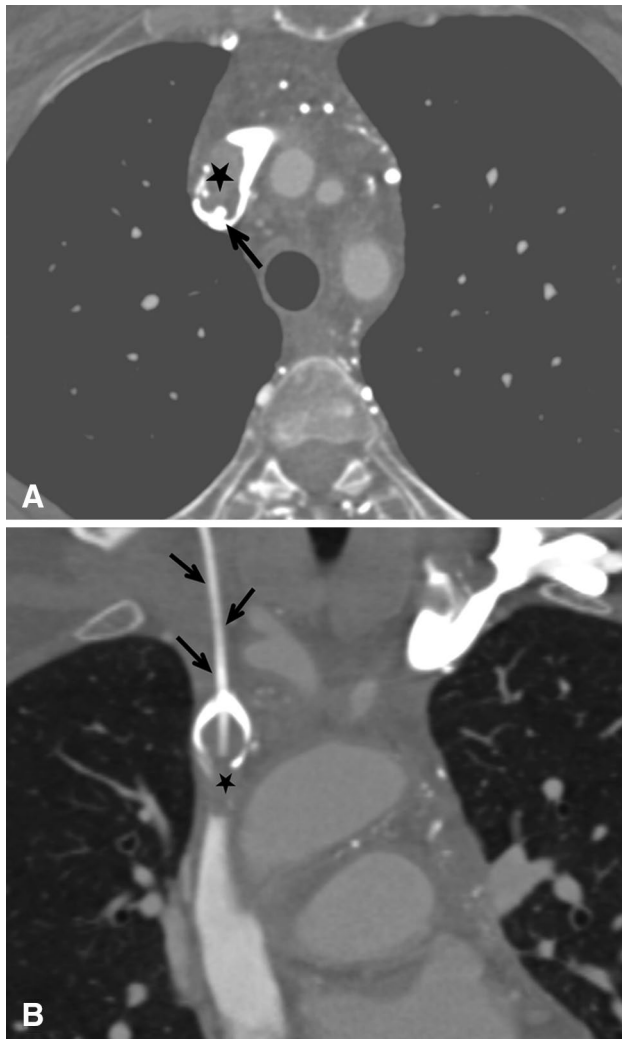


Fig. 1 Axial (a) and coronal (b) computed tomography angiography images: thrombosis in the catheter and superior vena cava leading to occlusion 11 months after implantation a right sided port catheter in a patient with lumpectomy history in her right breast (black arrows port catheter, star thrombus)

can be implanted successfully by US and fluoroscopy guidance and procedure related and infective complication rates are low when imaging guidance is used [5, 6]. The standard access for SPCs is through the subclavian/internal jugular vein or cephalic vein, but a femoral vein access may be preferable in patients with history of breast surgery and/or RT [7]. Furthermore, peripheral arm port implantation can be an alternative way in this kind of patients to reduce complication rates. While increased thrombosis risk is an issue in these types of ports [8], there are some studies reporting lower risk of thrombosis [9]. We preferred the chest approach and SPCs have been implanted with imaging guidance in our interventional radiology unit.

Lymphatic drainage of the upper extremity is to axillary lymph nodes [5, 10] while drainage of the chest wall

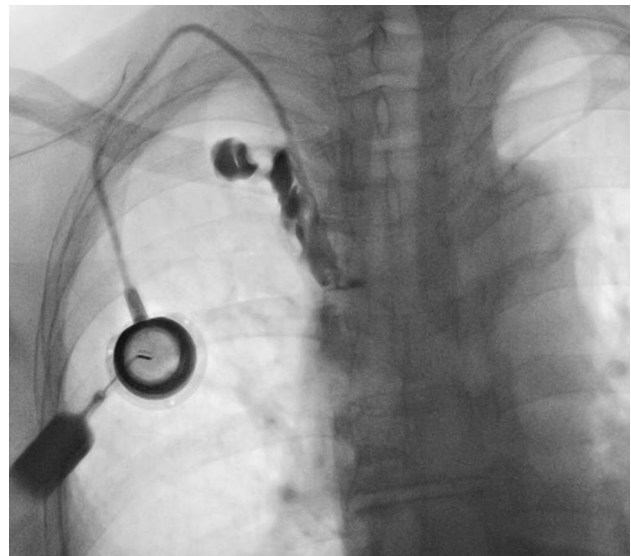


Fig. 2 Findings suggestive of thrombosis on a fluoroscopic image after contrast media injection into the catheter 13 months after implantation of a right sided port catheter in a patient with lumpectomy history in her right breast: contrast media is not passing from superior vena cava into the right atrium and there is pericatheter leakage of the contrast media

is to axillary and internal mammary lymph nodes. [2, 5]. Intravenous injections, blood collection, blood pressure measurement and venous access are traditionally avoided in breast cancer patients with ipsilateral lymph node dissection. Lymphatic drainage of the upper extremity and chest wall can be compromised in mastectomized patients with axillary lymph node dissection history. Tendency to infections can increase for this reason and it is the most frightening complication. Treatment of an infection is challenging in case when regional lymph nodes are absent [2]. Infection rates differ between 2.4 and 6.7% in SPC implanted patients in interventional radiology units [5, 11]. Infection can remain limited to the local port area or spread to the systemic circulation and lead to sepsis [12]. While Peynircioglu et al. [5] reported port related infection only in 1 patient, Gandhi et al. [2] reported no infection in their series with mastectomized patients with axillary lymph node dissection history. Infection was observed in 1 patient in both groups of our study. There was no statistical difference between two groups in regard to infections per 1000 days.

Early (within 30 days of the procedure) and late (after 30 days of the procedure) complications can happen after SPC placement. Most of early complications are probably related to the SPC placement technique and happen within 24 h of the procedure. However, some procedure related complications may not be identified within days or even weeks. Arterial and venous injury, arteriovenous

fistula, pneumothorax, hemothorax and hematoma are early complications seen within 24 h. Catheter fragmentation, occlusion, infection and venous thrombosis can happen within (early) or after (late) 30 days the procedure. Furthermore, cardiac arrhythmia, port erosion, venous perforation and cardiac perforation can be mentioned between other late complications. Complications happening in SPC implanted patients are classified as minor ones requiring no therapy, requiring nominal therapy and major ones requiring hospitalization, resulting in permanent adverse sequelae or death according to SIR classification [4].

Port catheter related venous thrombosis frequency is reported as 1.1–8.8% [13–16]. Thrombus most commonly forms at the entrance site of catheter into the vein or with the contact of catheter and wall of the vein. It is usually asymptomatic and can lead to infection and pulmonary embolism. The effect of type of catheters on thrombus formation is controversial [12]. Silver et al. [17] reported no statistical difference between port catheters and other catheters in regard to thrombosis rates. Furthermore, less thrombosis rates in port catheters have been reported when compared with other catheters. Catheter occlusion is reported to be 1.9–8% and it is mostly caused by thrombosed blood. However, parenteral nutrition, drugs or other intravenous solutions can cause occlusion [12]. Early complication was not observed in both groups of our study. No statistical significant difference was present between two groups in regard to late complications and complication rates defined according to SIR classification. Furthermore, sort of different port types were used in different patients. However, this situation did not affect the randomization of the study, because no statistical correlations were observed between complication rates and dimensions/materials of catheters for both groups.

One limitation of our study is its retrospective nature. Other limitations are the relatively small number of patients, relatively different types of used catheters in two groups and being made in a single center. The lack of significance between two groups in regard to infection rates could be affected by the small number of patients. Nevertheless, we think that including a control group improves the evaluation of data.

In conclusions, SPC usage has an important role in the management of oncologic patients. SPC related complications do not differ in regard to ipsilateral or contralateral side selection on mastectomized patients with breast cancer and lymph node dissection history. For this reason, SPCs can be implanted on ipsilateral or contralateral sides of the operation in these patients.

Compliance with ethical standards

Conflict of interest All authors of this manuscript, Omer Fatih Nas, Kadir Hacikurt, Ahmet Kaya, Nurullah Dogan, Bekir Sanal, Guven Ozkaya, Halit Ziya Dunder and Cuneyt Erdogan declare that they have no conflict of interest.

Ethical standards All procedures performed were in accordance with the ethical standards of the institutional research committee and with the 1964 Helsinki declaration and its later amendments or comparable ethical standards.

Informed consent Informed consent was obtained from all individual participants included in the study.

References

1. Jan HC, Chou SJ, Chen TH et al (2012) Management and prevention of complications of subcutaneous intravenous infusion port. *Surg Oncol* 21:7–13
2. Gandhi RT, Getrajdman GI, Brown KT et al (2003) Placement of subcutaneous chest wall ports ipsilateral to axillary lymph node dissection. *J Vasc Interv Radiol* 14:1063–1065
3. Rockson SG (1998) Precipitating factors in lymphedema: myths and realities. *Cancer* 83:2814–2816
4. Silberzweig JE, Sacks D, Khorsandi AS et al (2003) Reporting standards for central venous access. *J Vasc Interv Radiol* 14:443–452
5. Peynircioglu B, Arslan EB, Cil BE et al (2007) Subcutaneous venous port implantation in patients with bilateral breast surgery. *Cardiovasc Interv Radiol* 30:405–409
6. Vardy J, Engelhardt K, Cox K et al. (2004) Long-term outcome of radiological guided insertion of implanted central venous access port devices (CVAPD) for the delivery of chemotherapy in cancer patients: institutional experience and review of the literature. *Br J Cancer* 91:1045–1049
7. Almasi-Sperling V, Hieber S, Lermann J et al (2016) Femoral placement of totally implantable venous access ports in patients with bilateral breast cancer. *Geburtshilfe Frauenheilkd* 76:53–58
8. Kuriakose P, Colon-Otero G, Paz-Fumagalli R (2002) Risk of deep venous thrombosis associated with chest versus arm central venous subcutaneous port catheters: a 5-year single-institution retrospective study. *J Vasc Interv Radiol* 13:179–184
9. Marcy PY (2008) Central venous access: techniques and indications in oncology. *Eur Radiol* 18:2333–2344
10. Uren RF, Howman-Giles RB, Chung D et al (2005) Role of lymphoscintigraphy for selective sentinel lymphadenectomy. *Cancer Treat Res* 127:15–38
11. Lorch H, Zwaan M, Kagel C et al (2001) Central venous access ports placed by interventional radiologists: experience with 125 consecutive patients. *Cardiovasc Interv Radiol* 24:180–184
12. Kurul S, Saip P, Aydin T (2002) Totally implantable venous-access ports: local problems and extravasation injury. *Lancet Oncol* 3:684–692
13. Pardo I, Rager EL, Bowling MW et al (2011) Central venous port placement: a comparison of axillary versus anterior chest wall placement. *Ann Surg Oncol* 18:468–471

14. Biffi R, Corrado F, de Braud F et al (1997) Long-term, totally implantable central venous access ports connected to a Groshong catheter for chemotherapy of solid tumours: experience from 178 cases using a single type of device. *Eur J Cancer* 33:1190–1194
15. Biffi R, de Braud F, Orsi F et al (1998) Totally implantable central venous access ports for long-term chemotherapy. A prospective study analyzing complications and costs of 333 devices with a minimum follow-up of 180 days. *Ann Oncol* 9:767–773
16. Winters V, Peters B, Coilá S et al (1990) A trial with a new peripheral implanted vascular access device. *Oncol Nurs Forum* 17:891–896
17. Silver DF, Hempling RE, Recio FO et al (1998) Complications related to indwelling caval catheters on a gynecologic oncology service. *Gynecol Oncol* 70:329–333