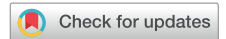

Identification of High-Risk Patent Foramen Ovale Associated With Cryptogenic Stroke: Development of a Scoring System



Rie Nakayama, MD, Yoichi Takaya, MD, Teiji Akagi, MD, Nobuhisa Watanabe, RDCS, Madoka Ikeda, RDCS, Koji Nakagawa, MD, Norihisa Toh, MD, and Hiroshi Ito, MD, *Okayama, Japan*

Background: Transcatheter closure of patent foramen ovale (PFO) has become an effective therapeutic strategy for cryptogenic stroke (CS). The identification of high-risk PFO is essential, but the data are limited. This study aimed to clarify the factors related to CS and to develop a score for high-risk PFO.

Methods: We retrospectively analyzed 57 patients with prior CS and 50 without CS who were scheduled for transcatheter closure. PFO characteristics were evaluated by transesophageal echocardiography. Based on factors related to CS, we estimated the risk score.

Results: Patients with CS had a greater frequency of large-size PFO (≥ 2 mm in height), long-tunnel PFO (≥ 10 mm in length), atrial septal aneurysm, hypermobile interatrial septum, prominent Eustachian valve or Chiari's network, the large right-to-left shunt at rest and during Valsalva maneuver, and low-angle PFO ($\leq 10^\circ$ of PFO angle from inferior vena cava), compared with patients without CS. Multivariate analysis showed that long-tunnel PFO, the presence of hypermobile interatrial septum, the presence of prominent Eustachian valve or Chiari's network, the large right-to-left shunt during Valsalva maneuver, and low-angle PFO were independently related to CS. When the score was estimated based on 1 point for each factor, the proportion of CS was markedly elevated with a score of ≥ 2 points. The probability of CS was markedly different between scores of ≤ 1 or ≥ 2 points.

Conclusions: PFO risk can be assessed with a score based on high-risk features. The presence of two or more high-risk PFO features is associated with CS. (J Am Soc Echocardiogr 2019;32:811-6.)

Keywords: Cryptogenic stroke, Echocardiography, Patent foramen ovale, Transcatheter closure

Patent foramen ovale (PFO) is linked with various diseases, including cryptogenic stroke (CS) and migraine.¹⁻⁶ The relationship between PFO and CS has become of particular interest, based on recent trials demonstrating that transcatheter PFO closure can reduce the recurrence of stroke compared with medical therapy.⁷⁻⁹ The prevalence of PFO is approximately 25% of the general population,¹⁰ but not all PFOs involve CS. As transcatheter closure would be expanded as the therapeutic option, it is important to identify cases of high-risk PFO who are most likely to be associated with CS. However, there are limited data on the comprehensive assessment of PFO morphology associated with the development of

CS.^{11,12} This study aimed to compare the anatomical and functional characteristics of PFO using transesophageal echocardiography (TEE) between patients with CS and those without CS and to clarify the factors related to CS. Furthermore, this study aimed to develop a scoring system for the identification of high-risk PFO.

METHODS

Study Population

We retrospectively enrolled 107 consecutive patients with PFO who were scheduled for transcatheter closure for CS or migraine from May 2008 to December 2017. Patients with CS were proven to have cerebral infarction using magnetic resonance imaging. CS was diagnosed by a neurologist based on the exclusion of all other identifiable causes of stroke such as large artery atherosclerosis, cardioembolism, small vessel disease, or arterial dissection after clinical examinations including brain and carotid imaging, electrocardiography, and echocardiography. Patients with CS who were suspected of PFO were referred to our institution to assess for indication of transcatheter closure. All patients underwent TEE to identify the presence of PFO. When PFO was detected and the other causes of CS were excluded, transcatheter closure was scheduled. Migraine was diagnosed according to the criteria of the International Headache Society.¹³ Patients

From the Department of Cardiovascular Medicine, Okayama University Graduate School of Medicine, Dentistry and Pharmaceutical Science (R.N., Y.T., T.A., K.N., N.T., H.I.); and Division of Medical Support, Okayama University Hospital (N.W., M.I.), Okayama, Japan.

Conflicts of Interest: None.

Reprint requests: Yoichi Takaya, MD, Department of Cardiovascular Medicine, Okayama University Graduate School of Medicine, Dentistry and Pharmaceutical Science, 2-5-1 Shikata-cho, Kita-ku, Okayama 700-8558, Japan (E-mail: takayayoichi@yahoo.co.jp).

0894-7317/\$36.00

Copyright 2019 by the American Society of Echocardiography.

<https://doi.org/10.1016/j.echo.2019.03.021>

Abbreviations

ASA = Atrial septal aneurysm

CS = Cryptogenic stroke

IVC = Inferior vena cava

PFO = Patent foramen ovale

RL = Right-to-left

TEE = Transesophageal
echocardiography

with migraine underwent magnetic resonance imaging and were confirmed to have no cerebral infarct lesion. They were referred to our institution to assess for indication of transcatheter PFO closure. Patients who were detected PFO by TEE were scheduled for transcatheter closure. This study classified patients with migraine as the group

of PFO patients without CS. All patients gave written informed consent for the examinations. The study was approved by the ethics committee of our institution.

Echocardiography

TEE was performed for PFO diagnosis before transcatheter closure using iE33 with an X7-2t probe (Philips Medical Systems, Andover, MA) under local anesthesia. Intravenous sedation was administered if needed, although patients remained able to follow instructions for Valsalva maneuver. The presence of PFO was confirmed when

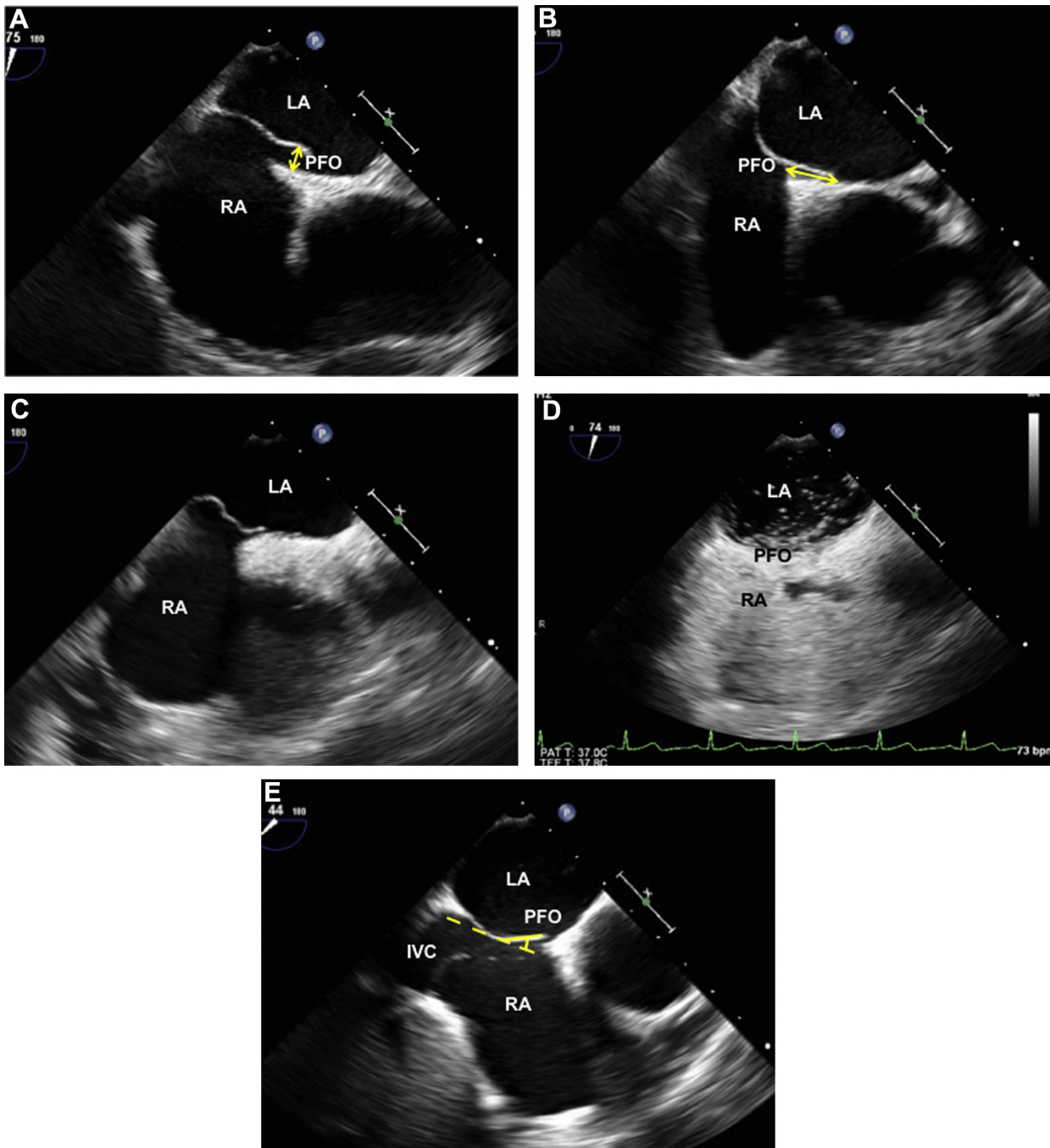


Figure 1 PFO characteristics. **(A)** The height of PFO was measured by the maximum separation (*arrow*). **(B)** The length of PFO tunnel was measured by the maximum overlap (*arrow*). **(C)** The moving and floppy septum was defined as hypermobile interatrial septum. **(D)** The maximum number of microbubbles was counted. **(E)** The angle between IVC and PFO was measured. LA, Left atrium; RA, right atrium.

HIGHLIGHTS

- Transcatheter patent foramen ovale (PFO) closure is effective for cryptogenic stroke.
- Identification of high-risk PFO is important.
- The anatomical and functional characteristics of PFO are evaluated.
- PFO morphologies related to cryptogenic stroke are shown.
- A high PFO score is associated with cryptogenic stroke.

microbubbles crossed from the right to left atrium within three cardiac cycles after opacification of the right atrium, using intravenous injection of agitated saline contrast. The anatomical and functional characteristics of PFO, such as the height of PFO, the length of PFO tunnel, the presence of atrial septal aneurysm (ASA), the presence of hypermobile interatrial septum, the presence of prominent Eustachian valve or Chiari's network, the grade of right-to-left (RL) shunt at rest and during Valsalva maneuver, and the angle between inferior vena cava (IVC) and PFO, were evaluated by independent cardiologists who were unaware of the CS status of the patient. The height of PFO was measured by the maximum separation between the septum primum and septum secundum in the end-systolic frame (Figure 1A), and a height ≥ 2 mm was defined as large-size PFO.¹⁴ The length of PFO tunnel was measured by the maximum overlap between the septum primum and septum secundum (Figure 1B), and a length ≥ 10 mm was defined as long-tunnel PFO.¹¹ ASA was defined as ≥ 10 mm of septal excursion from the midline into the right or left atrium or ≥ 15 mm of total excursion between the right and left atrium.¹ We also defined the moving and floppy septum with ≥ 5 mm of septal excursion in every heartbeat as hypermobile interatrial septum (Figure 1C). The presence of prominent Eustachian valve was defined as ≥ 10 mm protrusion within the right atrium.¹⁵ The grade of RL shunt was assessed at rest and during Valsalva maneuver using agitated saline contrast. The maximum number of microbubbles that appeared in the left atrium was counted in a single frame (Figure 1D), and the large RL shunt was defined as ≥ 20 microbubbles.^{1,8} We measured the angle between IVC and PFO flap on an imaging plane that displayed the IVC and interatrial septum (Figure 1E), and an angle of the PFO from the IVC $\leq 10^\circ$ was defined as low-angle PFO.

Statistical Analysis

Data are presented as mean \pm SD for continuous variables and as number and percentage for categorical variables. Differences between the two groups were analyzed by the *t*-test and Mann-Whitney *U*-test for continuous variables and the χ^2 -test for categorical variables. Univariate and multivariate logistic analysis was performed to identify independent factors related to CS. Variables for analysis included large-size PFO, long-tunnel PFO, the presence of hypermobile interatrial septum, the presence of prominent Eustachian valve or Chiari's network, the large RL shunt during Valsalva maneuver, and low-angle PFO. Odds ratios are shown with 95% CIs. Based on the results of multivariate analysis, the score of high-risk PFO was estimated. Statistical analysis was performed with statistical software (JMP version 11.0; SAS Institute, Cary, NC), and significance was defined as a value of $P < .05$.

Inter- and intraobserver differences were analyzed in 20 randomly selected images. The length of PFO tunnel, the presence of hypermo-

Table 1 Patient characteristics

Variables	Patients with CS (n = 57)	Patients without CS (n = 50)	P value
Age, years	50 \pm 14	42 \pm 18	.016
Male	24 (42)	26 (52)	.668
Hypertension	20 (35)	8 (16)	.025
Dyslipidemia	11 (19)	8 (16)	.656
Diabetes mellitus	3 (5)	3 (6)	.869
Smoking	8 (14)	12 (24)	.202

Data are presented as mean \pm SD or *n* (%) of patients.

Table 2 Echocardiographic PFO characteristics

Variables	Patients with CS (n = 57)	Patients without CS (n = 50)	P value
Height of PFO, mm	2.4 \pm 1.6	1.6 \pm 0.9	.002
Large-size PFO, ≥ 2 mm	11 (19)	3 (6)	.042
Length of PFO, mm	9.1 \pm 4.3	8.3 \pm 4.2	.319
Long-tunnel PFO, ≥ 10 mm	29 (51)	14 (28)	.016
ASA	23 (40)	6 (12)	.001
Hypermobile interatrial septum	40 (70)	8 (16)	<.001
Prominent Eustachian valve or Chiari's network	24 (42)	7 (14)	.001
Large RL shunt at rest	11 (19)	1 (2)	.004
Large RL shunt during Valsalva maneuver	38 (67)	19 (38)	.001
Angle between IVC and PFO, degrees	29 \pm 16	37 \pm 14	.007
Low-angle PFO ($\leq 10^\circ$)	14 (25)	4 (8)	.022

Data are presented as mean \pm SD or *n* (%) of patients.

bile interatrial septum, and the large RL shunt during Valsalva maneuver were evaluated by two blinded observers and by a single observer at two different times. Reliability was calculated by Pearson's correlation coefficient. Variability was calculated as the percentage error of each measurement and derived as the difference between the two measurements divided by the mean value.

RESULTS

Patient Characteristics

The mean age of all patients was 45 \pm 15 years. Comparisons of patient characteristics between 57 patients with CS and 50 without CS are shown in Table 1. Patients with CS were older than those without CS. The prevalence of hypertension was higher in patients with CS than in those without CS.

Echocardiographic Characteristics of PFO

Comparisons of the anatomical and functional characteristics of PFO between the two groups are shown in Table 2. The height of PFO was greater in patients with CS than in those without CS, and large-size

Table 3 Factors related to CS

Variable	Univariate analysis		Multivariate analysis 1		Multivariate analysis 2	
	Odds ratio (95% CI)	P value	Odds ratio (95% CI)	P value	Odds ratio (95% CI)	P value
Large-size PFO, ≥ 2 mm	2.54 (1.16-5.59)	.02	0.83 (0.24-2.62)	.754	1.16 (0.33-3.94)	.815
Long-tunnel PFO, ≥ 10 mm	2.66 (1.19-5.97)	.017	3.27 (1.11-10.6)	.032	3.16 (1.04-10.5)	.042
ASA	4.96 (1.82-13.5)	.002	3.33 (0.94-13.0)	.064	2.51 (0.68-10.3)	.171
Hypermobile interatrial septum	11.4 (4.43-29.1)	<.001	9.09 (2.84-33.5)	<.001	7.26 (2.19-27.5)	.001
Eustachian valve or Chiari's network	4.47 (1.72-11.6)	.002	4.71 (1.45-17.2)	.009	4.58 (1.41-16.9)	.011
Large RL shunt during Valsalva maneuver	5.86 (2.51-13.7)	<.001	3.63 (1.23-11.3)	.020	3.87 (1.27-12.6)	.018
Low-angle PFO, $\leq 10^\circ$	3.74 (1.14-12.3)	.029	5.80 (1.38-29.7)	.016	5.12 (1.10-30.3)	.037
Age	4.34 (1.80-10.5)	.001			2.99 (0.77-12.3)	.112
Hypertension	2.84 (1.12-7.20)	.023			1.64 (0.43-6.77)	.473

Variables for multivariate analysis 1 included large PFO, long-tunnel PFO, the presence of ASA, the presence of hypermobile interatrial septum, the presence of prominent Eustachian valve or Chiari's network, the large RL shunt during Valsalva maneuver, and low-angle PFO. Variables for multivariate analysis 2 added age and the prevalence of hypertension.

PFO (≥ 2 mm) was more frequently observed in patients with CS. While long-tunnel PFO (≥ 10 mm) was more frequently observed in patients with CS than in those without CS, there was no difference in the mean length of PFO tunnel between the two groups. This was because short-tunnel PFO (≤ 2 mm) was also frequent in patients with CS. Patients with CS more frequently had ASA, hypermobile interatrial septum, and prominent Eustachian valve or Chiari's network compared with those without CS. The large RL shunt at rest and during Valsalva maneuver was more frequently observed in patients with CS than in those without CS. The angle between IVC and PFO was lower in patients with CS than in those without CS, and low-angle PFO ($\leq 10^\circ$) was more frequently observed in patients with CS.

Factors Related to CS

Multivariate logistic analysis showed that long-tunnel PFO, the presence of hypermobile interatrial septum, the presence of prominent Eustachian valve or Chiari's network, the large RL shunt during Valsalva maneuver, and low-angle PFO were independently related to CS (Table 3). When age and the prevalence of hypertension were added as variables to multivariate logistic analysis, the same echocardiographic factors were independently related to CS. Age or the prevalence of hypertension was not related (Table 3).

High-Risk PFO Score

By scoring each independent factor related to CS as 1 point (Table 4), we estimated the score of high-risk PFO. The proportion of patients with CS and those without CS according to the score is shown in Figure 2. The proportion of CS was 5% or 17% at a score of 0 or 1 point, respectively. However, the proportion of CS was markedly elevated at a score of ≥ 2 points, with 80%, 87%, or 89% at a score of 2, 3, or 4 points, respectively. The probability of CS was also markedly different between scores of ≤ 1 or ≥ 2 points. A score of 2 points had 91% sensitivity and 80% specificity for the association with CS. The false-positive rate and the false-negative rate were 20% and 9%, respectively. Among patients with CS who had a score of ≥ 2 points, the individual components related to CS are shown in

Table 4 Large-size high-risk PFO score calculator

Variables	Point
Long-tunnel PFO ≥ 10 mm	1
Hypermobile interatrial septum	1
Eustachian valve or Chiari's network	1
Large RL shunt during Valsalva maneuver	1
Low-angle PFO $\leq 10^\circ$	1

Figure 3. The presence of hypermobile interatrial septum and the large RL shunt during Valsalva maneuver were strongly related to CS.

Reproducibility

There was good agreement in the measurements of the length of PFO tunnel between the two blinded observers ($r=0.98$, $P<.001$) and for the intraobserver ($r=0.97$, $P<.001$). The inter- and intraobserver variabilities for the length of PFO tunnel were 4.8% and 5.1%, respectively. There was 100% agreement in the classification of the hypermobile interatrial septum and also the large RL shunt during Valsalva maneuver by both of the blinded observers and a single observer assessing twice.

DISCUSSION

The present study evaluated the anatomical and functional characteristics of PFO in patients with CS and those without CS. The major findings were as follows: (1) long-tunnel PFO, the presence of hypermobile interatrial septum, the presence of prominent Eustachian valve or Chiari's network, the large RL shunt during Valsalva maneuver, and low-angle PFO were independent factors related to CS; and (2) PFO with a score ≥ 2 points was associated with CS when

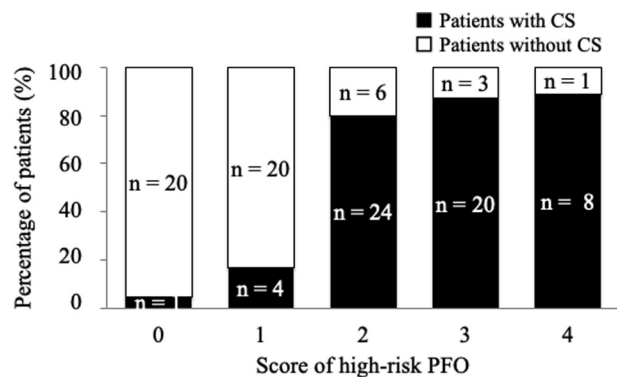


Figure 2 High-risk PFO score. The proportion of patients with CS and those without CS was assessed based on the scoring system. The proportion of CS was low at a score of 0 or 1 point, but it was markedly elevated at a score of ≥ 2 points.

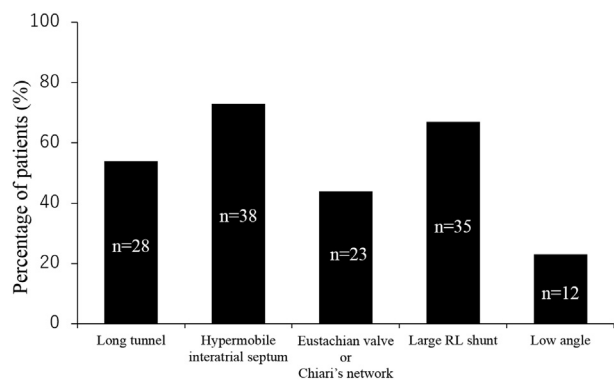


Figure 3 Individual components related to CS. The individual components related to CS in patients with CS who had a score of ≥ 2 points are shown.

the score was estimated based on 1 point for each factor. To the best of our knowledge, this is the first study to develop a score of high-risk PFO associated with CS.

Factors Related to CS

Because transcatheter PFO closure has recently become an effective therapy for stroke, accurate diagnosis of PFO is needed.^{16,17} Furthermore, it is essential to stratify PFO for an increased risk of CS. Previous studies have reported that the large-size PFO, the large RL shunt, and the presence of ASA were risk factors for an increased likelihood that PFO was causally linked to CS.^{11,18-20} The presence of prominent Eustachian valve or Chiari's network was also reported to be more common in patients with CS.^{21,22} Nevertheless, there were conflicting reports showing no relationships,²³ and the characteristics of PFO related to CS remain controversial. In addition, the detailed assessment of PFO morphology using echocardiography has not been fully investigated.

In the present study, the large RL shunt during Valsalva maneuver was related to CS, whereas the large-size PFO was not related. This observation may relate to the fact that PFO size was measured at rest. The opening of PFO can enlarge when the pressure in the right atrium exceeds that in the left atrium due to Valsalva maneuver, thereby increasing the potential for thrombus passage from the venous to arterial circulation. Thus, assessment of the maximum

PFO size induced by Valsalva maneuver may be useful to assess the probability of CS.

This study found that the presence of hypermobile interatrial septum was related to CS. Hypermobile interatrial septum, which is the floppy septum with movement of free edge in every heartbeat, can often cause enlargement of the PFO orifice, leading to an increase in the potential for thrombus passage. Indeed, ASA was observed in 40% of patients with CS, while hypermobile interatrial septum was observed in 70%. Our findings suggest that the presence of hypermobile interatrial septum should be carefully evaluated using TEE.

The presence of prominent Eustachian valve or Chiari's network was also related to CS in this study. The Eustachian valve is an embryological remnant of the valve that prenatally directs blood flow from the IVC to fossa ovalis of the septum. Chiari's network is a mobile structure that extends from the junction of the IVC and right atrium to the septum. Both structures can direct IVC blood flow through PFO and predispose to CS. The mechanism of CS may also relate to the angle between the IVC and PFO. Indeed, we provide new evidence that the low angle between the IVC and PFO is related to CS. The low angle may preferentially direct IVC blood flow toward the interatrial septum and PFO orifice.

Similar to the previous study,¹¹ this study showed that long-tunnel PFO was related to CS. The septal pouch on the left side of interatrial septum was reported to be associated with CS caused by thrombus formation.²⁴ Long-tunnel PFO might also be the site for thrombus formation because of turbulent and stagnant blood flow.¹¹ In contrast, patients with CS have also been reported to have short-tunnel PFO.²⁵ Thus, further studies are required to elucidate the relationship between the length of PFO tunnel and CS and to identify the mechanisms.

Clinical Implications

Recent randomized trials demonstrated the benefits of transcatheter closure for the reduction of stroke compared with medical therapy,⁷⁻⁹ although the earlier trials such as CLOSURE I, PC, and RESPECT failed to show the superiority.²⁶⁻²⁸ These discrepancies between the earlier negative trials and recent positive trials are thought to relate to patient selection for transcatheter PFO closure. Because PFO is a frequent finding,¹⁰ the identification of high-risk PFO is important. There are likely multiple factors involved in the role of PFO in causing CS. Thus, the scoring system using these factors may be useful for clinical stratification of PFO. In the present study, we developed a scoring system for the identification of high-risk PFO associated with CS, with each factor related to CS scored as 1 point. The association with CS was low at a score of 0 or 1 point, but it was markedly elevated at a score of ≥ 2 points. Indeed, at a score of 2 points, the sensitivity and the specificity for the association of PFO with CS were 91% and 80%, respectively. These findings suggest that a score of ≥ 2 points is clinically useful for stratifying PFO for risk of developing of CS and thus for selection of appropriate patients for PFO closure.

Study Limitations

There are several limitations to the present study. First, this was a retrospective cohort study. Thus, the score was not assessed to predict who will develop a CS. Second, there was selection bias because only patients who were scheduled for transcatheter PFO closure were selected. Therefore, our study population had a high proportion of high-risk subjects and was not representative of the general

population with PFO. A larger study including patients who were not considered for transcatheter closure is required to confirm our findings. Third, neurologically asymptomatic subjects who had a PFO on TEE would be the ideal control or comparison group, but for this study we used patients with migraine as the control group. Fourth, the grade of RL shunt might be underestimated because it depends on the degree of Valsalva maneuver. However, the TEE and Valsalva assessment were performed uniformly by the operators at our institution. Lastly, the number of cases may be too small to determine in the multivariate analysis whether certain components in the score should have different weights.

CONCLUSION

Long-tunnel PFO, the presence of hypermobile interatrial septum, the presence of prominent Eustachian valve or Chiari's network, the large RL shunt during Valsalva maneuver, and low-angle PFO were related to CS. When two or more of these features are present on TEE, there is a strong association with CS. Thus, a score that accounts for the presence of these PFO features may be valuable for identifying patients with PFO at high risk of CS.

REFERENCES

1. Kerut EK, Norfleet WT, Plotnick GD, Giles TD. Patent foramen ovale: a review of associated conditions and the impact of physiological size. *J Am Coll Cardiol* 2001;38:613-23.
2. Khessali H, Mojadidi MK, Gevorgyan R, Levinson R, Tobis J. The effect of patent foramen ovale closure on visual aura without headache or typical aura with migraine headache. *JACC Cardiovasc Interv* 2012;5:682-7.
3. Fallier M, Kessler R, Chaouat A, Ehrhart M, Petit H, Weitzenblum E. Platypnea-orthodeoxia syndrome related to an aortic aneurysm combined with an aneurysm of the atrial septum. *Chest* 2000;118:553-7.
4. Torti SR, Billinger M, Schwerzmann M, Vogel R, Zbinden R, Seiler C, et al. Risk of decompression illness among 230 divers in relation to the presence and size of patent foramen ovale. *Eur Heart J* 2004;25:1014-20.
5. Hara H, Virmani R, Ladich E, Mackey-Bhjack S, Titus J, Schwartz RS, et al. Patent foramen ovale: current pathology, pathophysiology, and clinical status. *J Am Coll Cardiol* 2005;46:1768-76.
6. Lechat P, Mas JL, Lascault G, Loron P, Theard M, Grosgeat Y, et al. Prevalence of patent foramen ovale in patients with stroke. *N Engl J Med* 1988;318:1148-52.
7. Saver JL, Carroll JD, Thaler DE, Smalling RW, MacDonald LA, Tirschwell DL, et al. Long-term outcomes of patent foramen ovale closure or medical therapy after stroke. *N Engl J Med* 2017;377:1022-32.
8. Sondergaard L, Kasner SE, Rhodes JF, Andersen G, Iversen HK, Thomassen L, et al. Patent foramen ovale closure or antiplatelet therapy for cryptogenic stroke. *N Engl J Med* 2017;377:1033-42.
9. Mas JL, Derumeaux G, Guillon B, Massardier E, Hosseini H, Chatellier G, et al. Patent foramen ovale closure or anticoagulation vs. antiplatelets after stroke. *N Engl J Med* 2017;377:1011-21.
10. Hagen PT, Scholz DG, Edwards WD. Incidence and size of patent foramen ovale during the first 10 decades of life: an autopsy study of 965 normal hearts. *Mayo Clin Proc* 1984;59:17-20.
11. Goel SS, Tuzcu EM, Shishebor MH, Olivira EI, Borek PP, Kapadia SR, et al. Morphology of the patent foramen ovale in asymptomatic versus symptomatic (stroke or transient ischemic attack) patients. *Am J Cardiol* 2009;103:124-9.
12. De Castro S, Cartoni D, Fiorelli M, Rasura M, Anzini A, Pandian NG, et al. Morphological and functional characteristics of patent foramen ovale and their embolic implications. *Stroke* 2000;31:2407-13.
13. Headache Classification Subcommittee of the International Headache Society. The international classification of headache disorders. 2nd ed. *Cephalalgia* 2004;24:9-160.
14. Lee PH, Song JK, Kim JS, Heo R, Lee S, Kin H, et al. Cryptogenic stroke and high-risk patent foramen ovale: the DEFENSE-PFO Trial. *J Am Coll Cardiol* 2018;71:2335-42.
15. Rigatelli G, Dell'Avvocata F, Cardaioli P, Giordan M, Braggion G, Aggio S, et al. Permanent right-to-left shunt is the key factor in managing patent foramen ovale. *J Am Coll Cardiol* 2011;58:2257-61.
16. Mojadidi MK, Mahmoud AN, Elgendy IY, Agarwal N, Tobis JM. Transesophageal echocardiography for the detection of patent foramen ovale. *J Am Soc Echocardiogr* 2017;30:933-4.
17. Yamashita E, Murata T, Goto E, Fujiwara T, Sasaki T, Minami K, et al. Inferior vena cava compression as a novel maneuver to detect patent foramen ovale: a transesophageal echocardiographic study. *J Am Soc Echocardiogr* 2017;30:292-9.
18. Schuchlenz HW, Weihs W, Horner S, Quehenberger F. The association between the diameter of a patent foramen ovale and the risk of embolic cerebrovascular events. *Am J Med* 2000;109:456-62.
19. Pearson AC, Nagelhout D, Castello R, Gomez CR, Labovitz AJ. Atrial septal aneurysm and stroke: a transesophageal echocardiographic study. *J Am Coll Cardiol* 1991;18:1223-9.
20. Mas JL, Arquizan C, Lamy C, Zuber M, Cabanes LL, Coste J, et al. Recurrent cerebrovascular events associated with patent foramen ovale, atrial septal aneurysm, or both. *N Engl J Med* 2001;345:1740-6.
21. Schneider B, Hofmann T, Justen MH, Meinertz T. Chiari's network: normal anatomic variant or risk factor for arterial embolic events? *J Am Coll Cardiol* 1995;26:203-10.
22. Schuchlenz HW, Saurer G, Weihs W, Rehak P. Persisting Eustachian valve in adults: relation with patent foramen ovale and cerebrovascular events. *J Am Soc Echocardiogr* 2004;17:231-3.
23. Wessle BS, Thaler DE, Ruthazer R, Weimar C, Di Tullio MR, Elkind MS, et al. Transesophageal echocardiography in cryptogenic stroke and patent foramen ovale: analysis of putative high-risk features from the risk of paradoxical embolism database. *Circ Cardiovasc Imaging* 2014;7:125-31.
24. Holda MK, Krawczyk-Ozog A, Koziej M, Sorysz D, Holda J, Dudek D, et al. Left-sided atrial septal pouch is a risk factor for cryptogenic stroke. *J Am Soc Echocardiogr* 2018;31:771-6.
25. Natananz A, Goldman ME. Patent foramen ovale: anatomy versus pathophysiology—which determines stroke risk? *J Am Soc Echocardiogr* 2003;16:71-6.
26. Furlan AJ, Reisman M, Massaro J, Mauri L, Adams H, Wechsler L, et al. Closure or medical therapy for cryptogenic stroke with patent foramen ovale. *N Engl J Med* 2012;366:991-9.
27. Meier B, Kalesan B, Mattle HP, Ahmed A, David HS, Stephan W, et al. Percutaneous closure of patent foramen ovale in cryptogenic embolism. *N Engl J Med* 2013;368:1083-91.
28. Carroll JD, Saver JL, Thaler DE, Smalling RW, Berry S, Tirschwell DL, et al. Closure of patent foramen ovale versus medical therapy after cryptogenic stroke. *N Engl J Med* 2013;368:1092-100.