

The use of autogeneous mandibular bone block grafts for reconstruction of alveolar defects

Access this article online

Website:

www.amsjournal.com

DOI:

10.4103/2231-0746.161070

Quick Response Code:



Doğan Dolanmaz, Alparslan Esen¹, Gülsün Yıldırım, Özgür İnan²

Departments of Oral and Maxillofacial Surgery, Faculty of Dentistry, Selcuk University, ¹Necmettin Erbakan University, ²Department of Prosthodontics, Faculty of Dentistry, Selcuk University, Konya, Turkey

Address for correspondence:

Dr. Alparslan Esen, Faculty of Dentistry, Necmettin Erbakan University, Cerrahi AD. Ankara Cd. No: 74, Konya, Turkey.
E-mail: dtaesen@hotmail.com

ABSTRACT

Objective: Purpose of this retrospective study was to evaluate outcomes autogenous bone block grafts obtained from mandible for different indications. The healing of the donor and recipient sites in the postoperative period, morbidity and the resorption of the graft were investigated. **Patients and Methods:** Twenty-nine patients grafted with mandibular bone block graft were participated in the present study. Grafting was applied in these patients for three indications; reconstruction of alveolar cleft, lateral crest augmentation before dental implantation and sinus floor augmentation. All operations were performed under local anesthesia and in some cases sedation was used as well. **Results:** Minimal exposure of the block graft occurred in three alveolar cleft patients. Secondary epithelization was achieved in all cleft patients with no symptoms of infection. In one patient infection was seen in donor site 1-week after the operation. The region was curetted and antibiotics administrated again. Two patients showed an infection of recipient site, after 4 weeks the grafts were removed. In all the patients, as the screw head became apparent until 1 thread, amount of the resorption were considered <1.5 mm. **Conclusion:** The usage of mandibular block grafts is a simple and effective treatment modality for reconstruction of different types of alveolar defects and it also reduces cost of treatment.

Keywords: Alveolar bone grafting, alveolar cleft grafting, maxillary sinus floor augmentation

INTRODUCTION

The repair of congenital or acquired alveolar defects with bone grafts is one of the most common surgery techniques in oral and maxillofacial surgery. Although autogenous bone grafts need a second surgical intervention, they are accepted as a golden standard because of their high osteogenic potential.^[1] The grafts can be obtained from various extraoral donor sites like iliac crest, calvarium, tibia and rib. The iliac crest is the most common site to harvest large amounts of autogenous bone.^[2,3] Obtaining grafts from these areas usually involves general anesthesia. However, the patients affected by partial edentulism do not easily accept major surgical procedures that may imply hospitalization or general anesthesia. Also, the use of extraoral bone grafting

is a cause of major patient discomfort during the immediate postoperative phase.^[4]

Generally, localized bone defects of oral region require only a confined amount of bone. Donor sites for these grafts can be found within oral cavity. The mandible is one of the most common donor sites in the maxillofacial region. Most of craniofacial bones of the skull and mandible are formed by intra membranous ossification. The membranous bone grafts show less resorption than endochondral bone grafts.^[5-8] Furthermore, membranous cortical grafts revascularization is more rapid than endochondral bone grafts.^[5,9,10] Therefore, embryological origin of donor bone is important factor for a successful recovery period. Another advantage of the intraoral donor site is that harvesting of bone can be performed under local anesthesia. Additionally, bone grafts can

be easily obtained with lower complications from intraoral donor sites.^[11] Common donor sites in the oral region are mandibular symphysis, retromolar area and the maxillary tuberosity.^[11-14]

In this retrospective study, the outcomes of autogenous block bone grafts obtained from mandible are reported for different indications. The healing of the donor and recipient sites in the postoperative period, morbidity and the resorption of the graft are clinically assessed.

PATIENTS AND METHODS

All patients with alveolar defect were treated by mandibular block graft, who had at least 6 weeks of follow-up, complete records and any systemic disease were included in this study. Patient demographic information and other clinical details were stated in Table 1. This retrospective study consisted of 29 patients (14 females and 15 males) and patients' ages ranging from 15 to 63 years (mean age 32.8 years). The bone harvesting procedure was performed for three indications; reconstruction of alveolar cleft, lateral crest augmentation and sinus floor augmentation. All operations were performed under local anesthesia and in some cases sedation was used as well.

Ten alveolar clefts were grafted in seven patients (two female, five male, mean ages 18.1). Out of these seven, four had unilateral alveolar cleft and three bilateral alveolar clefts. Ramus grafts were used for the repair of all clefts. All of these patients had exceeded their secondary graft period and thus their canine tooth had appeared. Maxillary unity and closing of oronasal relation were aimed in these cases. After the nasal mucosal layer had been closed, block graft was harvested from mandibular ramus region. Particle bone was obtained from the same region by using bone scraper and it was placed into the defect. The cortical block was then placed on it as a cover and fixed with screw or plate and screw. Oral layer was primarily sutured with periosteal releasing [Figure 1].

Twenty patients were treated with lateral alveolar augmentation. Seventeen of these patients were partially and three were completely edentulous. The mean age of the patients was 37.7 years. 19 block graft were obtained from ramus and 6 from symphysis [Table 1]. The surgical intervention for alveolar crest augmentation consisted of two phases. In the first phase, one or more bone blocks harvested from mandibular ramus or symphysis were fixed with titanium screws to the recipient site to achieve a horizontal augmentation of the ridge volume. In the second phase, 4–6 months later, fixation screws were removed and the implants were placed simultaneously [Figure 2].

In two patients, mandibular ramus block bone was applied in sinus augmentation procedures. The block graft was used to ensure the primary stability of the implants in patients with subnasal bone height <5 mm. It was fixed by implant on the sinus floor. The remaining space was filled with particles of bovine bone [Figure 3].

Preoperative radiographic evaluations were conducted using plain radiographs and if necessary using dental computerized

tomography (CT). Dental CT was used especially for patients who needed implants. All surgical procedures were performed under local anesthesia after the treatment procedures were explained to the patients. An incision was made from the vestibular sulcus of the first molar tooth to the retromolar pad and to the ascending ramus for the ramus block graft. When the impacted third molar was extracted at the same operation, the incision was performed from the disto-buccal of the second molar and extending posteriorly lateral to the retromolar pad and medial to the external oblique ridge. An additional vertical releasing incision was made. The mucoperiosteal flap was elevated inferiorly and posteriorly to expose the mandibular ramus and external oblique ridge. Osteotomy line was determined with guide holes by using fine round bur. This line was deepened using a fissure bur. After that, cortical layer was taken as a block with osteotomes. The osteotomies were limited to the thickness of the buccal cortex. In the symphysis region, sulcular incision was preferred and the incision extended distal to the canines, and a vertical release incision was made anterior and above the height of mental foramen. A full thickness mucoperiosteal flap was reflected to expose the symphysis region. Superior osteotomy was made 5 mm below the root apices and inferior osteotomy was made at least 5 mm over the inferior border of the mandible. After that, the block graft was harvested carefully without perforating the lingual cortex.

The resorption of bone grafts were evaluated according to the appearance of the screw head used for fixation when the second surgical intervention was performed. The healing of the donor and recipient sites in the postoperative period, morbidity and the resorption of the graft were clinically assessed.

RESULTS

The mean follow-up period of alveolar cleft patients was 16.1 months (range: 6–26 months) and augmentation patients was 17.5 months (range: 6–28 months).

Minimal exposure of the block graft was seen in three alveolar cleft regions. The mean complication rate was 30%. Exposed graft was reduced with a round bur. The region was irrigated with saline solution for 2 weeks and secondary epithelization was seen with no symptoms of infection. Graft exposures in these patients were recorded in the 2nd week after surgery. As the oronasal fistula was closed, the previous complaints of the patients regarding food leakage to the nasal area disappeared.

The overall complication rate was 15% in patients who underwent lateral crest augmentation. Only one patient who had lateral alveolar crest augmentation exhibited a small graft exposure in 2nd week. The soft tissue dehiscence resolved after the reduction of exposed graft. Donor site infection was observed in the same patient. Antibiotic therapy and curettage was performed. Two patients showed an infection of recipient side after 4 weeks. Antibiotic therapy was administered to these patients. Although the symptoms disappeared in 10 days, block graft were not integrated when the same regions were opened after 5 months for implant surgery and these graft were removed.

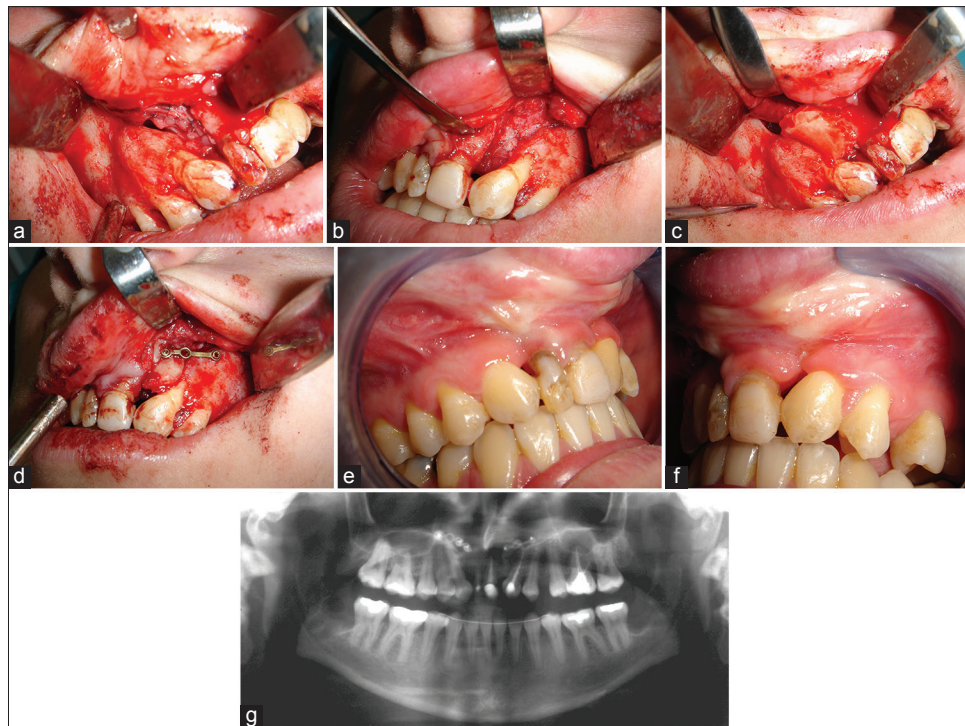


Figure 1: (a and b) Closure of nasal mucosal layer. (c and d) Placement and fixation of cortical block. (e and f) Postoperative images after 12 months. (g) Panoramic radiograph of patient in 12 months

In all the patients, amount of the resorption were considered approximately 1.5 mm according to screw head appearance. Thirty-six endosseous implants were placed to the augmented sides. Primary stability of all implants was satisfactory. Only in one patient, implant insertion caused partial mobilization of the graft at the top of the crest. No additional procedure was performed and any complications were not seen in follow-up. None of the patients had stated any paraesthesia in postoperative period. Extensive bleeding was not seen after the harvesting of the bone graft. No cosmetic problem was seen in any of the patients in whom symphysis or ramus bone graft was harvested.

DISCUSSION

Various techniques available for resolving insufficient alveolar ridge include particulate bone grafting technique, guided bone regeneration (GBR), bone splitting and horizontal alveolar distraction osteogenesis. Autografts, allografts, xenografts or alloplasts can be used for particulate bone augmentation. Reconstruction of alveolar defect with alternative bone filling materials such as freeze-dried bone, demineralized freeze-dried bone or other biomaterials (hydroxyapatite, tri-calcium phosphate) may be considered. The important advantage of these materials is their unlimited availability and lack of donor site morbidity. However, such bone does not have the healing capability and predictability of autogenous bone, and also these materials increase the cost.^[14] GBR has been advocated by some authors for augmentation. However, GBR presents some risks. Early exposure of the membrane is one of the most significant events. Exposure can be caused by the suturing of the mucosa over the membrane, which may compromise the vascular supply of the flaps and prevent them from attaching to the underlying bone

during healing, allowing muscle pull to tear the wound apart. Therefore the membranes and the operated area become infected and bone healing is compromised.^[15]

Ridge splitting is an alternative to the various techniques described for horizontal alveolar augmentation. However, the ridge split technique may cause some disadvantages including unfavorable fractures of the segment in less flexible bone and inadequate segment vascularity during expansion.^[16] Currently, the alveolar distraction osteogenesis is frequently used for augmentation of alveolar ridges. Distraction of the alveolar bone can be achieved in a vertical or a horizontal direction. Vertical alveolar distraction has advanced very rapidly, allowing the placement of longer implants. However, horizontal alveolar distraction (allowing implants with greater diameter) has received less attention because of postoperative complications, difficulty of technique and discomfort of patients in postoperative period.^[17]

Milinkovic and Cordaro reported mean bone gains and complication rates in a systematic review related with aforementioned methods performed to provide horizontal crest augmentation.^[18] According to authors, when the residual crest is 2.9 mm or wider, staged GBR can be applied and a mean bone gain of 3, 31 mm can be expected with 11, 9% complications related to membrane exposure. When the residual crest is < 4 mm, bone block grafts can be used in the augmentation of horizontal defects within a two staged approach. A mean bone gain of 4.3 mm at the time of implant placement can be seen with a mean complication rate of 6.3% related to graft exposure in this procedure. And finally, a linear bone gain of 2, 95 mm can be observed with a complication rate of 0.9–26% resulting from fracture of the buccal bone with ridge expansion/splitting

Table 1: Patients, procedures and complications

Age	Sex	Indication	Donor site	Recipient site	Complications	Follow-up (month)
15	Male	UAC	Ramus	Alveolar cleft	-	6
22	Female	BAC	Ramus (bilateral)	Alveolar cleft	Graft exposed (right side)	18
20	Male	BAC	Ramus (bilateral)	Alveolar cleft	Graft exposed (left side)	26
18	Male	BAC	Ramus (bilateral)	Alveolar cleft	-	14
16	Male	UAC	Ramus	Alveolar cleft	Graft exposed	16
17	Male	UAC	Ramus	Alveolar cleft	-	9
15	Male	LCA	Ramus	Anterior maxilla	-	8
20	Male	LCA	Ramus	Anterior maxilla	-	14
41	Female	LCA	Ramus	Posterior mandible	-	18
32	Female	LCA	Ramus	Posterior mandible	-	6
62	Female	LCA	Ramus	Posterior mandible	-	25
26	Female	LCA	Ramus	Anterior maxilla	-	22
49	Male	LCA	Ramus (bilateral)	Anterior maxilla	-	19
44	Female	LCA	Ramus	Posterior mandible	-	15
48	Female	LCA	Symphysis	Posterior maxilla	-	12
19	Male	LCA	Symphysis	Anterior mandible	-	23
39	Female	LCA	Ramus	Posterior maxilla	-	21
28	Female	LCA	Ramus	Posterior mandible	Donor site infection, graft exposed	24
34	Male	LCA	Ramus	Anterior maxilla	-	11
50	Male	LCA	Symphysis	Anterior maxilla	-	18
25	Male	LCA	Ramus	Anterior maxilla	-	28
38	Female	SFA	Ramus	Maxillary sinus floor	-	20
19	Female	UAC	Ramus	Alveolar cleft	-	24
56	Female	LCA	Ramus (bilateral)	Anterior maxilla	-	13
28	Female	LCA	Ramus	Posterior mandible	-	25
63	Female	LCA	Ramus	Posterior mandible	Recipient site infection, graft was lost	12
23	Male	LCA	Symphysis (bilateral)	Anterior maxilla	-	14
52	Male	LCA	Symphysis	Anterior mandible	Recipient site infection, graft was lost	23
38	Female	SFA	Ramus	Maxillary sinus floor	-	16

UAC: Unilateral alveolar cleft, BAC: Bilateral alveolar cleft, LCA: Lateral crest augmentation, VCA: Vertical crest augmentation SFA: Sinus floor augmentation

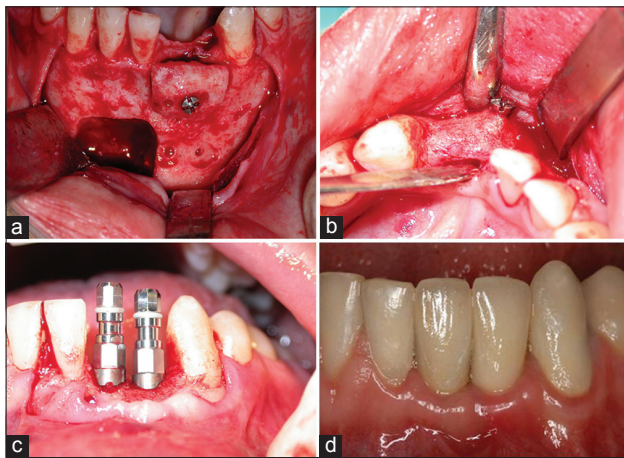


Figure 2: (a) Defect of donor site and placement of symphysis block graft with a screw to the recipient site. (b) Well incorporation of bone graft and minimal resorption of around the screw is seen after 5 months. (c) Placement of two implants. (d) Prosthetic image

technique. It is clear from this systematic review that autogenous block bone grafts can be applied safely with a low complication rate and satisfactory bone gain in patients when residual crest thickness is < 4 mm.

Currently, the usage of mandibular bone grafts has gained popularity.^[11,19-23] The mandible develops embryologically as intramembranous bone. Some studies have shown that the membranous bone grafts show less resorption and revascularize more rapidly than endochondral bone grafts.^[5,6,8,24] This rapid revascularization of membranous bone graft explains the maintenance of mandibular graft volume. However, other researchers^[9,25-27] suggested that the volume maintenance of onlay bone grafts depended on whether they are cortical or cancellous irrespective of their embryologic origin. So, the graft microarchitecture more correctly reflects bone graft behavior and serves as a better factor of bone graft survival. Same studies reported that the cortical bone grafts were less resorbed than cancellous grafts for onlay bone grafts.^[9,26,27] In addition to this, cortical/trabecular bone also contains mature bone cells, growth factors and more bone morphogenetic protein. Through these growth factors such as transforming growth factor or vascular endothelial growth factor, it stimulates the blood vessel growth from the host bone. Hence, mandibular donor grafts, which are primarily cortical bone, represent little volume loss and show good integration at short healing times.^[9,10]

We didn't use collagen membrane or xenograft in any cases which underwent lateral crest augmentation. In some clinical studies, xenograft and collagen barrier membranes in

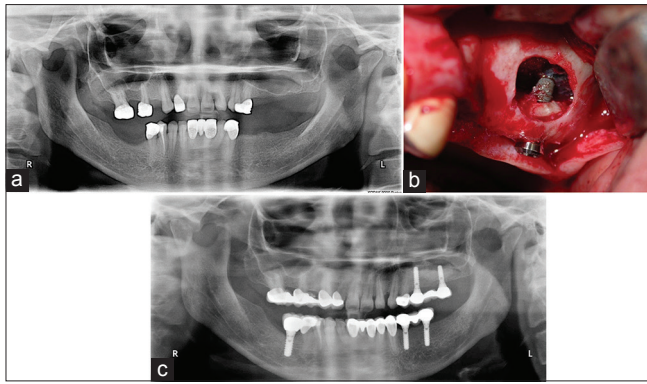


Figure 3: (a) The view of the left maxillary sinus before the surgery on panoramic radiograph. (b) The block graft was fixed by implant. (c) Panoramic radiograph after 15 months

combination with mandibular bone block graft were performed by different authors.^[20,28,29] The authors deduced that adding graft material and a collagen membrane around and over a mandibular bone block graft could reduce graft resorption during healing. But, the use of xenogenic materials and collagen membranes increased the frequency of complications related to soft tissue dehiscence.

Different methods were used for evaluation of the rate of resorption like head of screw, periodontal probe, caliper, clinical palpation or conventional radiographs in these studies. We based the head of fixation screw as reference to evaluate the level of resorption in our cases. We found that the rate of resorption is approximately 1.5 mm 4–6 months postoperatively. Two patients showed an infection of recipient side after 4 weeks and these grafts were removed. We believe that loosening of fixation screws is the cause of infection. Therefore the block graft must be kept fixed in the recipient side. If necessary, two screws can be used to provide the rigid fixation. In addition, for the graft fixation, the surface of the block graft should be in full contact with the underlying cortex of the host bone. Therefore, the correction of sharp edges of block graft may be required to better adapt to the recipient site.

Bone grafting is also important for alveolar clefts to close oronasal fistulae, to support the teeth around the cleft, to erupt the impacted canine tooth or neighboring teeth, to satisfy orthodontic movement, to boost premaxillary segment in bilateral clefts, to establish continuity of the contour of the alveolar crest, to build up nasolabial contour and alar base.^[2,3,30] Cortical bone grafts have some advantages physically in treatment of residual alveolar clefts such as supporting of alar base and providing immobilization of the maxilla.^[31] All of the alveolar cleft patients were in permanent dentition period and tertiary alveolar bone grafting was performed. Ramus block graft was fixed by screws or plate and screws for bilateral clefts so that immobilization of premaxilla was provided in early postoperative period. At the same time, particulate bone grafts were collected by scraper and bedded under the cortical cover to ensure better healing. The bone bridge was observed on radiographic images in all patients.

Grafting of the alveolar clefts with autogenous cancellous bone is a traditional method for erupting of impacted tooth to cleft region

or implant insertion.^[30,32] There are few reports in the literature regarding the treatment of alveolar clefts with mandibular bone block graft. Sawaki et al.^[33] reported the treatment of a bilateral cleft lip and palate patient using dental implant. The author used the particle cancellous bone marrow taken from the ilium to close the alveolar cleft. 14 years later, they applied mandibular ramus bone onlay grafting to raise the bilateral alveolar bone bridge because of the patient asked dental implant treatment. Takahashi et al.^[34] performed symphysis bone onlay graft combined with simultaneous implant insertion in patients with insufficient alveolar bone height. As we have seen mandibular bone grafts are applied to increase the alveolar bone bridges in these studies. In our patients, cancellous particulate bone was not preferred since there was not impacted tooth in clefts region and we didn't plan dental implant treatment. We aimed to just stabilize the maxillary segments and to support the alar base. We believe that well stabilization of the maxillary segments also provides a strong structure for the prosthetic rehabilitation.

The reasons for the common use of mandibular bone grafts are the use of local anesthesia instead of general anesthesia, the relatively short operation time, no need for postoperative hospitalization, less morbidity in the donor site and lower cost.^[11,13] Better postoperative patient comfort and low wound dehiscence rate are the reasons for selecting the ramus as a donor site.^[11] In this study, generally ramus region was preferred as a donor site. However, we chose symphysis region in 4 cases for the following reasons. These are planning of additional surgeries (removal of miniplate and implant placement) in anterior mandible and the need of large amount of bone graft volume.

Impacted third molars can be removed for the prophylactic or orthodontic indications. Ramus region is suitable as a donor site in the patients who have impacted third molars. With a modified technique, the bone covered the third molar can be harvested to use as a graft and after that impacted tooth can be removed easily at the same operation.^[35] In this study, ten third molar teeth were extracted during the donor site surgeries. Osteotomy line was made with a thin bur on the bone around the third molar tooth then the bone was taken as a block. After that teeth extracted easily and this procedure did not affect healing.

One of the disadvantages of ramus or retromolar region grafts was the risk of the damage to the inferior alveolar nerve or extensive bleeding.^[36] Misch was reported that 4 mm thickness of graft can be obtained from the region. When the anatomy of the region is well known and the osteotomy in the buccal cortex is given an inclination to the outside and conducted carefully, the exposure of the nerve or intensive bleeding are possibilities met rarely.^[35] We think that cone beam CT can be used as highly effective for this purpose prior to the procedure.

Mandibular bone block grafts give satisfactory results in cases with the lack of teeth up to 4, and they show resistant to resorption, as well as have lower complication rates and shorter healing period. The results of this research show that the technique of mandibular bone block grafting is a simple and effective treatment modality for reconstruction of insufficient alveolar bone and also reduced

the cost. Additionally it can be used in tertiary grafting of alveolar cleft to provide maxillary continuity.

REFERENCES

- Albrektsson T. Repair of bone grafts. A vital microscopic and histological investigation in the rabbit. *Scand J Plast Reconstr Surg* 1980;14:1-12.
- Boyne PJ, Sands NR. Secondary bone grafting of residual alveolar and palatal clefts. *J Oral Surg* 1972;30:87-92.
- Johanson B, Ohlsson A, Friede H, Ahlgren J. A follow-up study of cleft lip and palate patients treated with orthodontics, secondary bone grafting, and prosthetic rehabilitation. *Scand J Plast Reconstr Surg* 1974;8:121-35.
- Isaksson S, Alberius P. Maxillary alveolar ridge augmentation with onlay bone-grafts and immediate endosseous implants. *J Craniomaxillofac Surg* 1992;20:2-7.
- Kusiak JF, Zins JE, Whitaker LA. The early revascularization of membranous bone. *Plast Reconstr Surg* 1985;76:510-6.
- Zins JE, Whitaker LA. Membranous versus endochondral bone: Implications for craniofacial reconstruction. *Plast Reconstr Surg* 1983;72:778-85.
- Avery JK. *Oral Development and Histology*. New York: Thieme; 2011.
- Smith JD, Abramson M. Membranous vs endochondral bone autografts. *Arch Otolaryngol* 1974;99:203-5.
- Ozaki W, Buchman SR. Volume maintenance of onlay bone grafts in the craniofacial skeleton: Micro-architecture versus embryologic origin. *Plast Reconstr Surg* 1998;102:291-9.
- Misch CE. *Contemporary Implant Dentistry*. St. Louis: Mosby, Elsevier; 2008.
- Misch CM. Comparison of intraoral donor sites for onlay grafting prior to implant placement. *Int J Oral Maxillofac Implants* 1997;12:767-76.
- Sindet-Pedersen S, Enemark H. Mandibular bone grafts for reconstruction of alveolar clefts. *J Oral Maxillofac Surg* 1988;46:533-7.
- Misch CM, Misch CE, Resnik RR, Ismail YH. Reconstruction of maxillary alveolar defects with mandibular symphysis grafts for dental implants: A preliminary procedural report. *Int J Oral Maxillofac Implants* 1992;7:360-6.
- Raghoobar GM, Batenburg RH, Vissink A, Reintsema H. Augmentation of localized defects of the anterior maxillary ridge with autogenous bone before insertion of implants. *J Oral Maxillofac Surg* 1996;54:1180-5.
- Buser D, Dula K, Belser UC, Hirt HP, Berthold H. Localized ridge augmentation using guided bone regeneration. II. Surgical procedure in the mandible. *Int J Periodontics Restorative Dent* 1995;15:10-29.
- Duncan JM, Westwood RM. Ridge widening for the thin maxilla: A clinical report. *Int J Oral Maxillofac Implants* 1997;12:224-7.
- Garcia-Garcia A, Somoza-Martin M, Gandara-Vila P, Saulacic N, Gandara-Rey JM. Horizontal alveolar distraction: A surgical technique with the transport segment pedicled to the mucoperiosteum. *J Oral Maxillofac Surg* 2004;62:1408-12.
- Milinkovic I, Cordaro L. Are there specific indications for the different alveolar bone augmentation procedures for implant placement? A systematic review. *Int J Oral Maxillofac Surg* 2014;43:606-25.
- Misch CM. Use of the mandibular ramus as a donor site for onlay bone grafting. *J Oral Implantol* 2000;26:42-9.
- Cordaro L, Torsello F, Morcavallo S, di Torresanto VM. Effect of bovine bone and collagen membranes on healing of mandibular bone blocks: A prospective randomized controlled study. *Clin Oral Implants Res* 2011;22:1145-50.
- Cordaro L, Torsello F, Accorsi Ribeiro C, Liberatore M, Mirisola di Torresanto V. Inlay-onlay grafting for three-dimensional reconstruction of the posterior atrophic maxilla with mandibular bone. *Int J Oral Maxillofac Surg* 2010;39:350-7.
- Cordaro L, Amadé DS, Cordaro M. Clinical results of alveolar ridge augmentation with mandibular block bone grafts in partially edentulous patients prior to implant placement. *Clin Oral Implants Res* 2002;13:103-11.
- Buser D, Dula K, Hirt HP, Schenk RK. Lateral ridge augmentation using autografts and barrier membranes: A clinical study with 40 partially edentulous patients. *J Oral Maxillofac Surg* 1996;54:420-32.
- Peer LA. Fate of autogenous human bone grafts. *Br J Plast Surg* 1951;3:233-43.
- Hardesty RA, Marsh JL. Craniofacial onlay bone grafting: A prospective evaluation of graft morphology, orientation, and embryonic origin. *Plast Reconstr Surg* 1990;85:5-14.
- Chen NT, Glowacki J, Bucky LP, Hong HZ, Kim WK, Yaremchuk MJ. The roles of revascularization and resorption on endurance of craniofacial onlay bone grafts in the rabbit. *Plast Reconstr Surg* 1994;93:714-22.
- Sugg KB, Rosenthal AH, Ozaki W, Buchman SR. Quantitative comparison of volume maintenance between inlay and onlay bone grafts in the craniofacial skeleton. *Plast Reconstr Surg* 2013;131:1014-21.
- Maiorana C, Beretta M, Salina S, Santoro F. Reduction of autogenous bone graft resorption by means of bio-oss coverage: A prospective study. *Int J Periodontics Restorative Dent* 2005;25:19-25.
- Von Arx T, Buser D. Horizontal ridge augmentation using autogenous block grafts and the guided bone regeneration technique with collagen membranes: A clinical study with 42 patients. *Clin Oral Implants Res* 2006;17:359-66.
- Boyne PJ, Sands NR. Combined orthodontic-surgical management of residual palato-alveolar cleft defects. *Am J Orthod* 1976;70:20-37.
- Burchardt H. The biology of bone graft repair. *Clin Orthop Relat Res* 1983;174:28-42.
- Sindet-Pedersen S, Enemark H. Reconstruction of alveolar clefts with mandibular or iliac crest bone grafts: A comparative study. *J Oral Maxillofac Surg* 1990;48:554-8.
- Sawaki M, Ueno T, Kagawa T, Kanou M, Honda K, Shirasu N, *et al.* Dental implant treatment for a patient with bilateral cleft lip and palate. *Acta Med Okayama* 2008;62:59-62.
- Takahashi T, Fukuda M, Yamaguchi T, Kochi S. Use of endosseous implants for dental reconstruction of patients with grafted alveolar clefts. *J Oral Maxillofac Surg* 1997;55:576-83.
- Misch CM. The harvest of ramus bone in conjunction with third molar removal for onlay grafting before placement of dental implants. *J Oral Maxillofac Surg* 1999;57:1376-9.
- Von Arx T, Kurt B. Endoral donor bone removal for autografts. A comparative clinical study of donor sites in the chin area and the retromolar region. *Schweiz Monatsschr Zahnmed* 1998;108:446-59.

Cite this article as: Dolanmaz D, Esen A, Yıldırım G, İnan Ö. The use of autogeneous mandibular bone block grafts for reconstruction of alveolar defects. *Ann Maxillofac Surg* 2015;5:71-6.

Source of Support: Nil, **Conflict of Interest:** None declared.