

Esthetic Outcomes after Immediate and Late Implant Loading for a Single Missing Tooth in the Anterior Maxilla

P Yildiz, M Zortuk¹, E Kiliç², M Dincel³, H Albayrak⁴

Nimet Bayraktar Oral and Dental Health Center, ⁴Department of Prosthodontics, Faculty of Dentistry, Erciyes University, Kayseri, ¹Department of Prosthodontics, Faculty of Dentistry, Mustafa Kemal University, Hatay, ²Department of Oral and Maxillofacial Surgery, Faculty of Dentistry, Bezmialem University, Istanbul, ³Department of Prosthodontics, Yozgat Oral and Dental Health Center, Yozgat, Turkey

Date of Acceptance:
04-Apr-2018

INTRODUCTION

Considering only the survival rate is not sufficient to assess the success of the anterior implants. Osseointegration of an implant does not always result in aesthetic success.^[1] For esthetic success, the peri-implant soft tissue should be compatible with the adjacent soft tissue and implant-supported crowns must be in equilibrium with the opposite dentition. In the anterior maxilla, unsuccessful treatment outcomes can lead to disastrous clinical situations that can only be corrected by removal of the implant and a subsequent tissue augmentation procedure.^[2,3]

Smith and Zarb studied optimal esthetic outcomes for successful implant treatment in the anterior maxilla.^[2] In 2005, the “pink esthetic score” (PES) was proposed by Fürhauser *et al.* focusing on the soft-tissue aspects of anterior implants.^[3] Successful implant dentistry should include an assessment of the long-term outcome of the entire implant-prosthetic and soft tissue complex.^[4,5] Fürhauser *et al.* recommended PES as a suitable technique

ABSTRACT

Objective: This study compared the esthetic outcomes of 1-year follow-up of immediate and late implant loading after implant restoration of a single tooth in the anterior maxilla. **Materials and Methods:** A total of 33 patients with missing teeth in the anterior maxilla (Central = 8/lateral = 22/canine = 3) were enrolled in this study (18 immediate loading and 15 late loading). At after cementation, 1, 3, 6, and 12 months photographs were taken of anterior maxilla. The photographs were assessed using pink esthetic score (PES) which consists of seven variables. All PES data were analyzed with independent sample *t*-tests and repeated measures ANOVAs. **Results:** PES values increased significantly in both groups at the 1-year follow-up ($P > 0.05$). There was no statistically significant difference between the immediate and late loading groups at any time point ($P > 0.05$). **Conclusions:** Within the limitation of this study, immediate loading did not have a negative effect on esthetics.

KEYWORDS: *Esthetic success, loading protocols, pink esthetic score*

for evaluating soft tissue around single-tooth implant crowns that might change over time and as a useful tool for monitoring long-term soft tissue alterations.^[3]

Regarding the anterior maxilla, patients expect to be rehabilitated as soon as possible, especially patients undergoing esthetic restorations. After implant insertion, fabrication of the temporary restoration and loading of the implant within 48 h is referred to as “immediate loading.” This approach shortens the total treatment time, requires fewer surgical interventions and temporary prostheses, reduces peri-implant crestal bone loss, leads to better soft tissue healing, and can improve the esthetics. Moreover, the stability of peri-implant soft tissue is also of paramount importance within the anterior maxilla.^[6,7]

In this study, we compared PES outcomes at the 1-year follow-up of immediate and late implant loading after


Address for correspondence: Dr. H Albayrak, Department of Prosthodontics, Faculty of Dentistry, Erciyes University, 38039, Melikgazi, Kayseri, Turkey. E-mail: dthaydaralbayrak@hotmail.com

This is an open access journal, and articles are distributed under the terms of the Creative Commons Attribution-NonCommercial-ShareAlike 4.0 License, which allows others to remix, tweak, and build upon the work non-commercially, as long as appropriate credit is given and the new creations are licensed under the identical terms.

For reprints contact: reprints@medknow.com

How to cite this article: Yildiz P, Zortuk M, Kiliç E, Dincel M, Albayrak H. Esthetic outcomes after immediate and late implant loading for a single missing tooth in the anterior maxilla. *Niger J Clin Pract* 2018;21:1164-70.

Access this article online

Quick Response Code: 	Website: www.njcponline.com
	DOI: 10.4103/njcp.njcp_17_18

implant restoration of a single tooth in the anterior maxilla. The null hypothesis was that there would be no difference in PES outcomes after immediate and late implant loading for a single missing tooth in the anterior maxilla.

MATERIALS AND METHODS

This study involved patients who were referred to the Erciyes University Faculty of Dentistry. Treatment for single missing tooth was planned in the Department of Prosthodontics. Implant surgeries were performed in the Department of Oral and Maxillofacial Surgery.

Ethics approval was obtained on October 06, 2010 from the Erciyes University Ethics Council (2010/23). Informed consent was obtained from all patients who participated in this study.

In total, 33 patients with a mean age of 24.8 years were enrolled (23 women and 10 men). A summary of patient information is summarized in Table 1.

Treatment protocol

The same surgeon performed all surgeries. A mucoperiosteal flap was lifted, and an osteotomy was performed for the placement of all implants (bone level SLA implant and Straumann Dental Implant System; Institut Straumann AG, Basel, Switzerland) using 0.9% sodium chloride (NaCl) irrigation according to the manufacturer's recommendations.

The implants were 3.3 mm in diameter and 8, 12, or 14 mm in length, depending on the amount of bone present. During implant placement, the implant stability quotient (ISQ) was recorded immediately after insertion of the implant using an Osstell Mentor (Integration Diagnostics AB, Sævedalen, Sweden); there were no complications such as dehiscence or bone defects.

When ISQ values of 54 and above were observed, primary stability was considered sufficient, and an immediate loading protocol was performed with patient consent. An appropriate healing screw was selected based on gingival height, and the flap was sutured with Vicryl 3/0 (Ethicon Inc., Johnson and Johnson, Somerville, NJ, USA) in its original position [Figure 1].

Immediate implant loading protocol

In total, 18 patients (8 males and 10 females) were included in the immediate loading group. The same dentist prepared all restorations. Two patients lost their implants shortly after immediate loading. At 1 day after surgery, impressions were taken using a closed-tray technique with polyether impression materials (Impregum Penta; 3M-ESPE, Seefeld, Germany). With the help of temporary abutments, provisional crowns were fabricated and delivered on the same day. To add gingiva to the

provisional crown, acrylic resin (Dentalon Plus; Kulzer Co., Werheim, Germany) was added during fabrication. Occlusion of the provisional crown was designed with normal contacts in a centric relation and with lateral excursion. Patients were advised to avoid biting and using the tooth if possible. Patients were recalled 1 week later, and in that session, sutures were removed, and the effects of the provisional crowns were evaluated. If necessary, acrylic resin was added on the provisional crown or trimmed extraorally, and the formation of the gingiva was followed.

Late implant loading protocol

In the immediate loading group, at 3 months after surgery, the provisional crowns were removed. The primary stability of the implants was evaluated with the Osstell Mentor device.

In the late loading group, a second surgery was performed, healing caps were mounted on the implant, and gingiva was sutured. After a 1 week healing period, fabrication of the permanent prosthesis was started.

In the immediate loading group, to imitate the formatted gingiva, pink wax (Modeling Wax; Dentsply Detrey, UK) was added on the impression posts and mounted on the implants. In the late loading group, impressions were taken with standard procedures and standard impression posts. In both groups, impressions were taken with polyether (Impregum Penta, 3M-ESPE Dental AG, Seefeld, Germany) impression materials using a closed tray technique. Permanent restorations were fabricated according to patient choice (zirconium, $n = 11$, metal ceramic, $n = 20$); occlusions were adjusted, glazed, and cemented, and intraoral and extraoral photographs were taken. After 1, 3, 6, and 12 months, patients were recalled and photographs were taken again.

Photographic protocol

Initial photographs were taken after cementation of the prosthesis. At 1, 3, 6, and 12 months, patients were recalled and control photographs were taken again. A Nikon D100 digital SLR camera equipped with a Nikkor Medical Objective circular flash (Nikon Corporation, Tokyo, Japan) was used in aperture-priority mode to capture the images. Patients were positioned semi-reclined with the occlusal plane parallel to the floor. A lip retractor was positioned. The photographs were evaluated by two observers using PES.

Pink esthetic score

All photographs were assessed according to the PES,^[3] which consists of seven variables [Figure 2]:

1. Mesial papilla
2. Distal papilla
3. Soft-tissue level

4. Soft-tissue contour
5. Alveolar process deficiency
6. Soft tissue color and
7. Soft-tissue color texture.

Each variable was assessed on a scale from 0 to 2, with 2 indicating the best and 0 the poorest outcome. The mesial and distal papillae were evaluated for completeness, incompleteness or absence. All other variables were assessed by comparison with a reference tooth (i.e., the symmetric or neighboring tooth; [Table 2]).^[3] The highest possible score, reflecting a perfect match of the peri-implant soft tissue with that of the reference tooth, was 14.

Data analysis

Statistical analyses were performed using SPSS for Windows software (ver. 16.0; SPSS Inc., Chicago, IL, USA). To test the normality of the distribution of the PES data, the Shapiro-Wilk test was used. To evaluate the homogeneity of variance, Levene’s test was used. Independent-sample *t*tests and repeated-measures ANOVA were used for intra- and inter-group comparisons. The Bonferroni correction was used for multiple comparisons. *P* values <0.05 were considered to indicate statistical significance.

RESULTS

This study included 33 patients (23 females and 10 males). In total, 18 implants were evaluated in the immediate loading group and 15 in the late loading group. All implants in the immediate loading group had ISQ values of 54 or higher. In the immediate loading group, two implants (3.3 mm in diameter and 12 mm in length) failed within 2 weeks after surgery and were excluded from the study. Two patients in the late loading group were also excluded because they failed to attend their control appointments. The late loading group showed 100.0% success whereas the immediate loading group showed 88.8% success.

Intraexaminer reliability was high. When evaluating intraexaminer PES scores in the photographic assessment, the lowest kappa values were obtained for soft-tissue color (0.440, *P* = 0.005), and the highest values pertained to the evaluation of Zenith points (0.917, *P* < 0.001).

The intergroup evaluation of summed PES values is shown in Table 3. In the initial month in the immediate loading group, the mean summed PES value was 9.81 whereas after 12 months, the mean total PES value was 11.56. In the initial month in the late loading group, the mean summed PES value was 9.83 whereas after 12 months, it was 12. According to the *t*test results, there was no statistically significant difference between the immediate and late loading groups at any time point (*P* > 0.05).

The highest mean mesial papilla score in the immediate loading group was reported in the 12th month. The highest mean distal papilla scores were reported at baseline and at the 6th and 12th months. At baseline, in 43.8% of patients, the mesial papilla was not complete (score of 0 or 1), while in 87.5% of patients, the distal papilla was not complete. At 1-year follow-up, the mesial papilla was

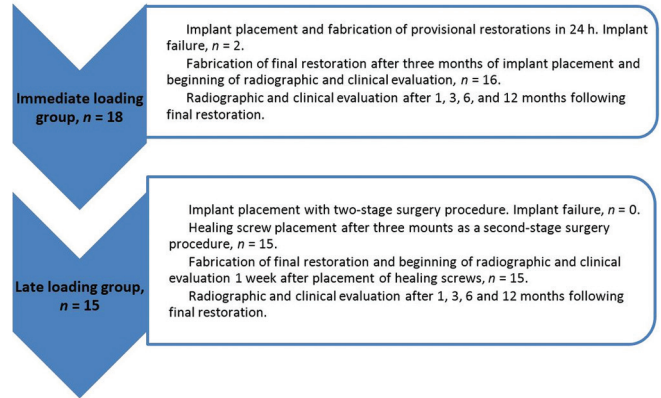


Figure 1: Overview of treatment protocols for immediate and late implant loading

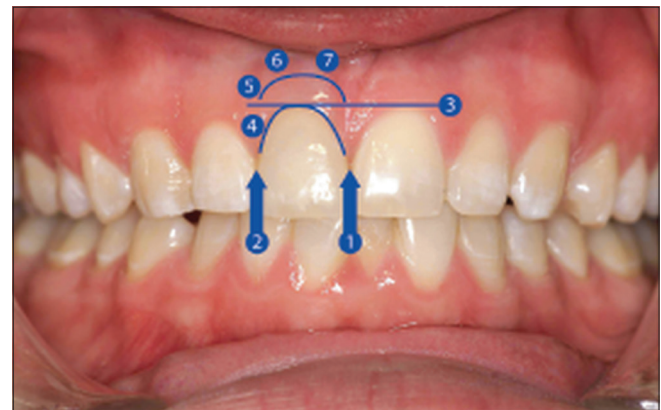


Figure 2: Pictorial view of pink esthetic score variables

Parametera	Immediate loading ^b	Late loading ^b
Mean age (years)	26, 68	22, 38
Male/female ratio	8/10	2/13
Place of the implant, C/L/Cn	5/11/2	3/11/1
Reason for missing tooth		
Trauma	4	2
Agenesis	7	9
Endodontic complication	7	4
Implant length (mm)		
8	1	
10	3	1
12	13	12
14	1	2

^aC, central; L, lateral; Cn, canine. ^bFor mean age, the first value is for male patients and the second is for females

Downloaded from http://journals.lww.com/njcp by BhdMf5eP-HKav1zEoum1t0iN4a+kLlHEZ9bstH04XMi0hCjwCXC1AW nYQp/IIQH3D3i3D00O0RyVT7vSF14C13VC1y0ab9gQZXdG6j2MwIZLeI= on 05/02/2025

Table 2: Variables of the pink esthetic score

Variables	Referances	0	1	2
Mesial papilla	Shape vs. reference tooth	Absent	Incomplete	Complete
Distal papilla	Shape vs. reference tooth	Absent	Incomplete	Complete
Level of soft tissue margin	Level vs. reference tooth	Major discrepancy, >2 mm	Minor discrepancy, 1-2 mm	No discrepancy, <1 mm
Soft tissue contour	Natural, matching reference tooth	Unnatural	Fairly natural	Natural
Alveolar process	Alveolar process deficiency	Obvious	Slight	None
Soft tissue color	Color vs. reference tooth	Obvious difference	Moderate difference	No difference
Soft tissue texture	Texture vs. reference tooth	Obvious difference	Moderate difference	No difference

Table 3: Inter- and intra-group evaluations of total PES values

Time	Groups		P ⁺
	Immediate loading group (n=16)	Late loading group (n=13)	
0	9.81±2.37 ^{a,c}	9.83±1.75 ^a	0.980
1	10.13±2.31 ^a	11.17±1.40 ^b	0.179
3	10.56±1.90 ^{a,c}	11.75±1.06 ^b	0.062
6	11.31±1.92 ^{bc}	11.92±1.08 ^b	0.302
12	11.56±1.97 ^b	12.00±1.04 ^b	0.491
Δ0-1	2.56±15.38	12.00±10.70	0.081
Δ0-3	7.33±16.66	16.63±10.34	0.101
Δ0-6	13.27±18.22	17.69±10.60	0.460
Δ0-12	15.30±16.50	18.33±10.28	0.581
P [†]	<0.001	<0.001	-

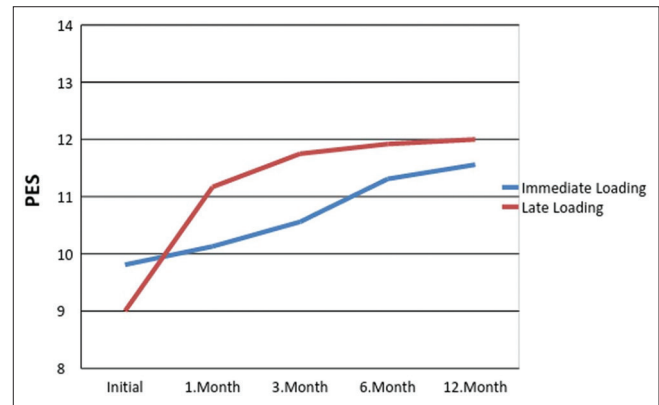
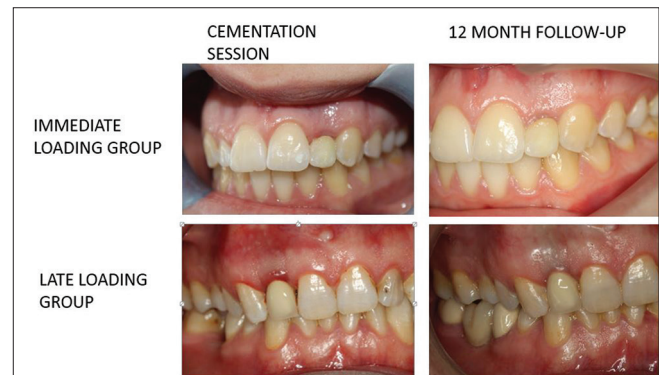
Data are expressed as means and standard deviation. Different letters indicate a statistical difference in the same column. P⁺: Significant inter-group difference. P[†] significant intra group difference. Δ0-1: ((total 1 - total 0)/total 1) × 100. P<0.05 were considered to indicate statistical significance

complete (score of 2) in 56.2% of the patients, with the distal papilla being complete in 12.5% of the patients.

The highest mean mesial papilla scores in the late loading group were seen in the 6th and 12th months. The highest mean distal papilla score was observed in the 12th month. At baseline, in 18.2% of patients, the mesial papilla was complete (score of 2), whereas the distal papilla was complete in 7.7% of patients. At 1-year follow-up, the mesial papilla was complete in 61.5% of patients, with the distal papilla being complete in 53.8% of patients.

The soft-tissue margin showed more than a 1-mm discrepancy in relation to the reference tooth in 75% of patients in the immediate loading group, compared to 76.9% of patients in the late loading group, at baseline. At 1-year follow-up, the soft-tissue margin showed a more than 1 mm discrepancy in relation to the reference tooth in 75% of patients in the immediate loading group and 61.5% of the patients in the late loading group.

The soft-tissue contour was found to be natural (score of 2) in 56.2% of patients in the immediate loading group, compared to 46.2% of patients in the

**Figure 3: Time-dependent changes in total pink esthetic score values****Figure 4: Case pictures of both the immediate and the late loading cases**

late loading group, at baseline. At 1-year follow-up, the values had increased to 75% and 84.6% of the patients in the immediate and late loading groups, respectively.

An alveolar process deficiency (score of 0 or 1) was seen in 19% of the patients in the immediate loading group, and 7.7% of patients in the late loading group, at baseline. At 1 year follow-up, the value had decreased to 12.5% in the immediate loading group, whereas no deficiency was observed in any patient in the late loading group.

The soft-tissue color showed no difference from that of the reference tooth in 37.5% of patients in the immediate loading group and in 46.2% of the patients in the late loading group, at baseline. At 1-year follow-up, the soft-tissue color was compatible with the reference tooth

Table 4: Patient distribution according to time and PES

PES	Score	Immediate Loading					Late Loading				
		0	1	3	6	12	0	1	3	6	12
Mesial papilla	0	3 (18.8%)	2 (12.5%)	1 (6.2%)	1 (6.2%)	0 (0%)	4 (30.8%)	0 (0%)	0 (0%)	0 (0%)	0 (0%)
	1	4 (25%)	7 (43.8%)	9 (56.2%)	6 (37.5%)	7 (43.8%)	7 (53.8%)	7 (53.8%)	7 (53.8%)	5 (38.5%)	5 (38.5%)
	2	9 (56.2%)	7 (43.8%)	6 (37.5%)	9 (56.2%)	9 (56.2%)	2 (18.2%)	6 (46.2%)	6 (46.2%)	8 (61.5%)	8 (61.5%)
Distal papilla	0	1 (6.2%)	1 (6.2%)	1 (6.2%)	0 (0%)	1 (6.2%)	4 (30.8%)	3 (23.1%)	0 (0%)	0 (0%)	0 (0%)
	1	13 (81.2%)	12 (75%)	10 (62.5%)	8 (50%)	6 (37.5%)	8 (61.5%)	8 (61.5%)	9 (69.2%)	7 (53.8%)	6 (46.2%)
	2	2 (12.5%)	3 (18.8%)	5 (31.2%)	8 (50%)	9 (56.2%)	1 (7.7%)	2 (15.4%)	4 (30.8%)	6 (42.9%)	7 (53.8%)
Soft tissue margin	0	1 (6.2%)	1 (6.2%)	1 (6.2%)	1 (6.2%)	1 (6.2%)	2 (15.4%)	2 (15.4%)	1 (7.7%)	1 (7.7%)	2 (15.4%)
	1	3 (18.8%)	3 (18.8%)	2 (12.5%)	2 (12.5%)	3 (18.8%)	1 (7.7%)	2 (15.4%)	4 (30.8%)	4 (30.8%)	3 (23.1%)
	2	12 (75%)	12 (75%)	13 (81.2%)	13 (81.2%)	12 (75%)	10 (76.9%)	9 (69.2%)	8 (61.5%)	8 (61.5%)	8 (61.5%)
Soft tissue contour	0	5 (31.2%)	2 (12.5%)	2 (12.5%)	2 (12.5%)	1 (6.2%)	1 (7.7%)	1 (7.7%)	0 (0%)	0 (0%)	0 (0%)
	1	2 (12.5%)	6 (37.5%)	5 (31.2%)	3 (18.8%)	3 (18.8%)	6 (46.2%)	5 (38.5%)	3 (23.1%)	2 (15.4%)	2 (15.4%)
	2	9 (56.2%)	8 (50%)	9 (56.2%)	11 (68.8%)	12 (75%)	6 (46.2%)	7 (53.8%)	10 (76.9%)	11 (84.6%)	11 (84.6%)
Alveolar process	0	1 (6.2%)	0 (0%)	0 (0%)	0 (50%)	0 (0%)	0 (0%)	0 (0%)	0 (0%)	0 (0%)	0 (0%)
	1	2 (12.5%)	3 (18.8%)	3 (18.8%)	2 (12.5%)	2 (12.5%)	1 (7.7%)	0 (0%)	1 (7.7%)	0 (0%)	0 (0%)
	2	13 (81.2%)	13 (81.2%)	13 (81.2%)	14 (87.5%)	14 (87.5%)	12 (92.3%)	13 (100%)	12 (92.3%)	13 (100%)	13 (100%)
Soft tissue color	0	1 (6.2%)	1 (6.2%)	0 (0%)	1 (6.2%)	1 (6.2%)	1 (7.7%)	0 (0%)	1 (7.7%)	2 (15.4%)	2 (15.4%)
	1	9 (56.2%)	9 (56.2%)	10 (62.5%)	8 (50%)	9 (56.2%)	6 (46.2%)	5 (38.5%)	4 (30.8%)	6 (46.2%)	6 (46.2%)
	2	6 (37.5%)	6 (37.5%)	6 (37.5%)	7 (43.8%)	6 (37.5%)	6 (46.2%)	8 (61.5%)	8 (61.5%)	5 (38.5%)	5 (38.5%)
Soft tissue texture	0	2 (12.5%)	0 (0%)	0 (0%)	0 (0%)	0 (0%)	0 (0%)	0 (0%)	0 (0%)	0 (0%)	0 (0%)
	1	6 (37.5%)	8 (50%)	6 (37.5%)	4 (25%)	1 (6.2%)	4 (30.8%)	1 (7.7%)	3 (23.1%)	1 (7.7%)	0 (0%)
	2	8 (50%)	8 (50%)*	10 (62.5%)	12 (75%)	15 (93.8%)	9 (69.2%)	12 (92.3%)*	10 (76.9%)	12 (92.3%)	13 (100%)

in 37% and 38.5% of the patients in the immediate and late loading groups, respectively.

The soft-tissue texture showed no difference from that of the reference tooth in 50% of the patients in the immediate loading group, and 69.2% of the patients in the late loading group at baseline. At 1-year follow-up, the soft-tissue texture was compatible with the reference tooth in 93.8% of patients in the immediate loading group and in all of the patients in the late loading group.

The time-dependent change in the total PES value was statistically significant in both groups [Figure 4]. According to the Bonferroni test results, in the immediate loading group, the baseline value was statistically significantly different versus the 12th month value ($P < 0.05$). The baseline value was statistically significantly different compared to the 6- and 12-month values ($P < 0.05$). The value at the 3rd month was also statistically significantly different to the 12-month value ($P < 0.05$). The 12-month value was statistically significantly different to the baseline, 1- and 3-month values ($P < 0.05$). Moreover, in the late loading group, the baseline value was statistically significantly different compared to the 1-3-, 6-, and 12-month values ($P < 0.05$; [Table 3]).

DISCUSSION

The esthetics of immediate- and late-loaded implants were evaluated by PES [Figure 3]. There was no

difference between the immediate- and late-loaded groups regarding PES values; thus, the null hypothesis of the study was accepted. Initially, in the immediate loading group, the total PES value was 9.812, while in late loading group, it was 9.615. At the 1-year follow-up, these scores had increased to 11.562 and 11.692, respectively. Chen and Buser defined PES values between 10 and 12 as indicative of “good” esthetics, with values of 13–14 indicating optimum implant esthetics.^[8] Thus, the patients in our study showed good esthetic outcomes, and there was no significant difference between the groups [Table 4.]

PES values increased significantly in both groups at the 1 year follow-up ($P > 0.05$). PES values in the immediate loading group increased, from 9.8–11.5, at 1 year. Similar to the results of this study, Lai *et al.*^[9] evaluated PES values for 29 implant-supported crowns in the anterior maxilla and reported that soft-tissue esthetics around single implants improved significantly after 6 months. In addition, Boardman *et al.* reported a total PES score of 10.9 and concluded that satisfactory esthetic outcomes could be achieved by replacing missing single teeth in the anterior maxilla with dental implants.^[10]

The mesial papilla “score 2” percentage did not change at the end of the 12th month whereas the distal papilla, “score 2” percentage increased to the same value as that for the mesial papilla (56.2%) in the immediate loading group. Fürhauser *et al.* reported a distal papilla score of 2

in ~ 50% of 1200 assessments.^[3] They explained that the difference between mesial and distal papilla scores was due to the type of photograph presented, where the distal papilla was harder to observe and to evaluate. Moreover, the distal papilla score was consistently low, with a median value of 1 (mean value = 1.2 0.6), in a study by Boardman *et al.*^[10] This is consistent with previous studies, in which the distal papilla was shown to be more troublesome than the mesial papilla.^[10-14] In addition, there were significant improvements in both the mesial and distal papillae in the late loading group.

The PES values for the soft-tissue margin did not change at 1 year follow-up in the immediate loading group compared with adjacent or symmetrical teeth. In 75% of the patients in this group, the soft-tissue level difference was <1 mm. However, in the late loading group, patients who had a soft-tissue level difference of <1 mm decreased from 76.9% to 61.5%. The soft-tissue recession in this region, in the late loading group, may have been due to bone loss. Similarly, Scheller *et al.* reported stable soft tissue in 75% of the implant-supported single-tooth replacements that they evaluated, with recession occurring in 10% of cases.^[3,15]

Alveolar process deficiency PES values were high, whereas soft-tissue contour PES values were average, at baseline in both groups. In our study, soft-tissue contour values approached alveolar process deficiency values after 12 months. According to these findings, alveolar process deficiency may affect the degree of soft-tissue contour.

At baseline, the color of the soft tissue in 37.5% of the patients in the immediate loading group was not different from that of the reference tooth; the value was 46.2% for the patients in late loading group. At 1-year follow-up, the value for immediate loading patients had not changed, whereas for the late loading group, it had decreased to 38.5%. Our late loading results were similar to those of Fürhauser *et al.*^[3] They reported that the color of the peri-implant soft tissue was consistent with that of the reference tooth in less than one-third of the cases and showed major differences in 20% of cases. They emphasized that ceramic abutments would play an important role in addressing this.

The PES value for soft-tissue texture showed a moderate difference between baseline and 1-year follow-up in both groups, but with no significant difference in either group. The reason for this success in soft-tissue texture outcome may be attributable to the high PES values of the alveolar process.

In a prospective study by Hall *et al.*, implants were placed in the anterior maxilla in two groups.^[16] Provisional crowns were then prepared just after surgery,

with permanent crowns prepared in the first group after 8 weeks ($n = 13$). In the second group ($n = 14$), the authors allowed 6 months for implant healing; then, they used provisional crowns for 8 weeks and prepared permanent crowns. At 1 year follow-up, they found that the type of loading did not affect the formation of soft tissue. Moreover, they concluded that there was no difference in prosthodontic maintenance or the implant crown mucosal response, including with respect to the interdental papillae, between the immediate and “conventional” restorations. Our results are consistent with Hall *et al.* The use of temporary crowns did not affect the esthetics of the soft tissue significantly in either group. There was also no statistically significant difference between the immediate and late loading groups ($P > 0.05$) regarding the mesial and distal papillae at 1-year follow-up.

In this study, the PES index was used to evaluate the esthetics of the soft-tissue around the implant. Fürhauser *et al.* suggested that PES was a suitable instrument for reproducibly evaluating soft tissue around single-tooth implant crowns that might change over time and could be useful for monitoring long-term soft-tissue alterations.^[3] In the literature, PES or the papilla filling index (PFI) have been used in similar studies.^[3,9,10,17-19] The primary difference between PES and PFI is that multiple parameters are evaluated.

It is obvious that immediate nonocclusal loading of a single implant in the maxillary esthetic zone leads to a short-term treatment outcome that is not less favorable than conventional loading. As immediate loading reduces the treatment time and could offer more comfort for the patient. However, the concept of immediate nonocclusal loading should be performed according to a specified protocol with attention to adequate primary implant stability and careful patient instruction. Our study had some limitations. A 1-year follow-up period is insufficient for a completely adequate evaluation of esthetic results. In addition, the number of patients and implants should be increased in future studies. Moreover, most of the patients were young, and the healing speed of tissues may have affected the esthetic outcomes. Finally, all of the selected teeth were in the anterior maxilla, and the outcome may be different in posterior parts of the mouth.

CONCLUSIONS

The lack of a statistically significant difference in PES values between the immediate and late loading groups indicated that immediate loading did not have a negative effect on esthetics. With appropriate patient selection, immediate implant loading may be used as a

safe alternative to late loading, to provide good esthetics shortly after surgery.

Financial support and sponsorship

Nil.

Conflicts of interest

There are no conflicts of interest.

REFERENCES

- Nisapakultorn K, Makrudthong J, Sa-Ard-Iam N, Rerkyen P, Mahanonda R, Takikawa O, *et al.* Indoleamine 2,3-dioxygenase expression and regulation in chronic periodontitis. *J Periodontol* 2009;80:114-21.
- Smith DE, Zarb GA. Criteria for success of osseointegrated endosseous implants. *J Prosthet Dent* 1989;62:567-72.
- Fürhauser R, Florescu D, Benesch T, Haas R, Mailath G, Watzek G, *et al.* Evaluation of soft tissue around single-tooth implant crowns: The pink esthetic score. *Clin Oral Implants Res* 2005;16:639-44.
- Patil R, Gresnigt MM, Mahesh K, Dilbaghi A, Cune MS. Esthetic evaluation of anterior single-tooth implants with different abutment designs-patients' satisfaction compared to dentists' observations. *J Prosthodont* 2017;26:395-8. [Doi: 10.1111/jopr.12423].
- Cho HL, Lee JK, Um HS, Chang BS. Esthetic evaluation of maxillary single-tooth implants in the esthetic zone. *J Periodontal Implant Sci* 2010;40:188-93.
- Belser U, Buser D, Higginbottom F. Consensus statements and recommended clinical procedures regarding esthetics in implant dentistry. *Int J Oral Maxillofac Implants* 2004;19 Suppl 1:73-4
- Belser UC, Schmid B, Higginbottom F, Buser D. Outcome analysis of implant restorations located in the anterior maxilla: A review of the recent literature. *Int J Oral Maxillofac Implants* 2004;19 Suppl 1:30-42.
- Chen ST, Buser D. Clinical and esthetic outcomes of implants placed in postextraction sites. *Int J Oral Maxillofac Implants* 2009;24 Suppl 1:186-217.
- Lai HC, Zhang ZY, Wang F, Zhuang LF, Liu X, Pu YP, *et al.* Evaluation of soft-tissue alteration around implant-supported single-tooth restoration in the anterior maxilla: The pink esthetic score. *Clin Oral Implants Res* 2008;19:560-4.
- Boardman N, Darby I, Chen S. A retrospective evaluation of aesthetic outcomes for single-tooth implants in the anterior maxilla. *Clin Oral Implants Res* 2016;27:443-51.
- De Rouck T, Collys K, Cosyn J. Immediate single-tooth implants in the anterior maxilla: A 1-year case cohort study on hard and soft tissue response. *J Clin Periodontol* 2008;35:649-57.
- Canullo L, Goglia G, Iurlaro G, Iannello G. Short-term bone level observations associated with platform switching in immediately placed and restored single maxillary implants: A preliminary report. *Int J Prosthodont* 2009;22:277-82.
- Gallucci GO, Grütter L, Chuang SK, Belser UC. Dimensional changes of peri-implant soft tissue over 2 years with single-implant crowns in the anterior maxilla. *J Clin Periodontol* 2011;38:293-9.
- Cosyn J, De Bruyn H, Cleymaet R. Soft tissue preservation and pink aesthetics around single immediate implant restorations: A 1-year prospective study. *Clin Implant Dent Relat Res* 2013;15:847-57.
- Scheller H, Urgell JP, Kultje C, Klineberg I, Goldberg PV, Stevenson-Moore P, *et al.* A 5-year multicenter study on implant-supported single crown restorations. *Int J Oral Maxillofac Implants* 1998;13:212-8.
- Hall JA, Payne AG, Purton DG, Torr B, Duncan WJ, De Silva RK, *et al.* Immediately restored, single-tapered implants in the anterior maxilla: Prosthodontic and aesthetic outcomes after 1 year. *Clin Implant Dent Relat Res* 2007;9:34-45.
- Schropp L, Isidor F, Kostopoulos L, Wenzel A. Patient experience of, and satisfaction with, delayed-immediate vs. delayed single-tooth implant placement. *Clin Oral Implants Res* 2004;15:498-503.
- Jemt T, Lekholm U. Single implants and buccal bone grafts in the anterior maxilla: Measurements of buccal crestal contours in a 6-year prospective clinical study. *Clin Implant Dent Relat Res* 2005;7:127-35.
- Priest G. Predictability of soft tissue form around single-tooth implant restorations. *Int J Periodontics Restorative Dent* 2003;23:19-27.