

# The role of EUS and EUS-guided FNA in the management of subepithelial lesions of the esophagus: A large, single-center experience

Birol Baysal, Omar A. Masri, Mohamad A. Eloubeidi<sup>1</sup>, Hakan Senturk

Department of Internal Medicine, Division of Gastroenterology, Bezmialem Vakif University Hospital, Istanbul, Turkey,

<sup>1</sup>Department of Gastroenterology, Advanced Endoscopy Unit, Regional Medical Center, Alabama, USA

## ABSTRACT

**Background:** Referral for endosonographic evaluation of subepithelial lesions seen in the gastrointestinal (GI) tract is fairly common. Although rarely studied separately in details, esophageal lesions have some unique differences from other GI sites and might deserve some special considerations regarding follow-up and management. **Materials and Methods:** All cases referred for endoscopic ultrasound (EUS) evaluation of subepithelial esophageal lesions at Bezmialem University Hospital, a tertiary center in Istanbul, Turkey were retrospectively reviewed. Data were collected for patient and lesion characteristics as well as for pathology results and follow-up if available. Lesions were subcategorized according to their size, location, and final diagnosis. **Results:** A total of 164 EUS examinations were identified. In 22.5% of cases, the lesion could not be identified by EUS. Of the remaining cases, 57.6% had a lesion larger than 1 cm in size. Extramural compression was the diagnosis in 12% and leiomyoma in around 60%. Thirteen patients had follow-up examinations with only two showing an increase in size after 12 months. Sixty-five EUS-guided fine needle aspirations (EUS-guided FNAs) were performed, with around 50% having nondiagnostic samples and 94% of the remaining samples confirming the presumptive diagnosis. **Conclusions:** The majority of subepithelial lesions in the esophagus are benign with extremely low malignancy potential. EUS examinations performed for lesions smaller than 2 cm as well as FNAs taken from lesions smaller than 3 cm might have minimal impact on their ultimate management and outcome. More than one FNA pass should be attempted in order to improve the yield.

**Key words:** Endosonography, esophagus, EUS-guided FNA, fine needle, leiomyoma, subepithelial, submucosal

## INTRODUCTION


The term “submucosal lesion” is often used to describe lesions along the gastrointestinal (GI) tract that are usually seen incidentally during endoscopic examination done for various indications, and in most cases they do not explain the indication or the symptoms for which the procedure was initially performed. However,

these lesions may arise from any layer along the wall, from deep mucosa to the serosa, making the term “subepithelial lesion” a more accurate one. They typically appear as a bulge from the wall into the lumen with a normal overlying mucosa. Moreover, extramural

This is an open access article distributed under the terms of the Creative Commons Attribution-NonCommercial-ShareAlike 3.0 License, which allows others to remix, tweak, and build upon the work non-commercially, as long as the author is credited and the new creations are licensed under the identical terms.

**For reprints contact:** [reprints@medknow.com](mailto:reprints@medknow.com)

**How to cite this article:** Baysal B, Masri OA, Eloubeidi MA, Senturk H. The role of EUS and EUS-guided FNA in the management of subepithelial lesions of the esophagus: A large, single-center experience. *Endosc Ultrasound* 2017;6:308-16.

Access this article online	
Quick Response Code:	Website: <a href="http://www.eusjournal.com">www.eusjournal.com</a>
	DOI: 10.4103/2303-9027.155772

## Address for correspondence

Dr. Hakan Senturk, E-mail: [drhakansenturk@yahoo.com](mailto:drhakansenturk@yahoo.com)

**Received:** 2015-03-02; **Accepted:** 2015-03-04

lesions or structures compressing the lumen might have a very similar appearance and in most of the occasions cannot be differentiated from esophageal intramural lesions by regular endoscopy alone.

Although the majority of subepithelial lesions discovered during upper endoscopy are located in the stomach, they are frequently seen in the esophagus accounting for up to 30% of upper GI tract lesions.<sup>[1,2]</sup> Thus, referral for endosonographic evaluation of such lesions when seen on regular endoscopy is an increasingly faced entity. However, it is important to note that there are some major clinical, prognostic, and pathological differences between lesions arising from the esophagus and those seen in the stomach or duodenum [Table 1]. These differences usually affect the decision for follow-up and the ultimate approach regarding surveillance recommendations, the need for endoscopic ultrasound-guided fine needle aspiration (EUS-guided FNA), the need and the feasibility of endoscopic mucosal resection, or the necessity of surgical excision.

Leiomyomas are by far the most common subepithelial lesions found in the esophagus accounting for around 70% of cases. Esophageal leiomyomas account for about 12% of all GI leiomyomas.<sup>[3]</sup> Cysts are the second most common found in up to 20% of esophageal subepithelial lesions. These include inclusion cysts, duplication cysts, and bronchogenic cysts. Granular cell tumors can also be seen in the esophagus

although the majority (95%) is located outside the GI tract; mostly in the tongue, skin, and breast.

With the emergence of endoscopic ultrasonography, patients with such lesions are increasingly being referred for EUS evaluation. Potential information delivered by such a modality includes the location and the layer of origin of the lesion, the accurate size, features of malignancy, the ability to obtain pathology samples, potential resectability, and other treatment plans. However, data regarding the utility of this modality and its role in the management of subepithelial lesions arising specifically in the esophagus are scarce.

In 2006, the American Gastroenterological Association (AGA) published guidelines specific for the management of gastric subepithelial masses.<sup>[4]</sup> However, the role of EUS in esophageal subepithelial lesions has not been addressed. To date, no clear data are available to guide endoscopists in selecting the patients with esophageal subepithelial lesions who actually need referral for EUS examination. In some cases, EUS would significantly add to the cost and risks without providing major added benefit over regular endoscopic follow-up.

The aims of this retrospective study are to document the EUS findings of these cases, and to clarify the diagnostic and prognostic role of EUS and/or EUS-guided FNA in altering their management. Our ultimate goal is to set a guide for appropriate referral of these patients for EUS evaluation.

**Table 1: Characteristics and management of the common causes for esophageal subepithelial lesions**

Type of lesion	Layer of origin	Grossly	Common location	Malignant potential	EUS characteristics	Follow up
Leiomyoma (70%)	MP (4th layer) (MM is more common in esophagus)	Variable	Mid-distal	Rare if any	Hypoechoic, homogeneous, well demarcated	EUS every 12 months
Duplication cyst	Variable, mostly SM (3rd layer)	Round, compressible	Any	Very low	Anechoic, well demarcated, +/- septae & debris	EUS ?
Bronchogenic cyst	MP (or SM)	Large (2-6 cm), round, compressible	Distal	Absent	Anechoic or hypoechoic. Enhanced walls	None
Granular cell tumor	SM or deep mucosa (Rarely MM or MP)	Small (<1 cm), yellow firm nodules, single or multiple	Mid-distal	Low	Small, oval, hypoechoic, mildly heterogeneous, smooth borders	EUS every 1-2 years or resection
GIST	MP	Nonspecific	Unusual	High	Hypoechoic, more or less homogeneous, well demarcated	Excision
Lipoma	SM (3rd layer)	Yellow hue, soft/ pillow sign	Any	Absent	Hyperechoic, homogeneous, well demarcated	None
Fibrovascular polyp	Deep mucosa or SM	Elongated polypoid	Proximal	Absent	Superficial	None
Varices	SM	Tortuous, blue	Mid-distal	Absent	Anechoic, flow on doppler	None
Hemangioma	SM or MM	Bluish, nodular, blanch when pressed	Distal	Absent	Hypoechoic, sharp margins	None

MM: Muscularis mucosa, MP: Muscularis propria, SM: Submucosa, GIST: Gastrointestinal stromal tumor

## MATERIALS AND METHODS

The medical records of all endoscopies performed at Bezmialem University Hospital, a tertiary center in Istanbul, Turkey, were reviewed retrospectively. Records of all patients who were referred for EUS evaluation of esophageal lesions in the period extending from May 2011 to August 2014 were identified. Only those with a suspicion for “submucosal”, “subepithelial”, or “extrinsic compression” were systematically reviewed in details. Patients with a diagnosis of esophageal cancer were excluded from the study. Data collection included the age and sex of the patient, the location and size of the lesion by endoscopy, the layer of origin, echogenicity and size by EUS, and the pathology result if FNA was performed. Follow-up endoscopies and any further management like endoscopic or surgical excision were also recorded.

The lesions were subcategorized according to their location in the esophagus: Proximal (<20 cm from incisors), mid (20-30 cm), or distal (>30 cm); or according to their size: Small (<1 cm), medium (1-2 cm), and large (>2 cm); or according to the final diagnosis: Normal if no lesion or findings were seen, extrinsic compression, or intramural subepithelial lesion.

All EUS examinations were performed using linear or radial echoendoscopes (PentaxEurope GmbH, Hamburg, Germany). Deep sedation protocol using propofol and ketamine under the supervision of an anesthesiologist was adopted for all patients unless there was a contraindication and the alternative mode of sedation were used according to the recommendation and guidance of the anesthesiologist. All FNAs were performed using a 22 Gauge needle (Echotip Ultrasound Needle, Wilson-Cook, Cook Ireland Ltd, Limerick, Ireland). The trend was to perform only one needle pass in most of the cases, with further attempts considered in case the retrieved sample was grossly inadequate or bloody.

## RESULTS

A total of 151 patients underwent 164 EUS examinations for the evaluation of a suspected esophageal subepithelial lesion [Table 2]. Out of the 164 EUS examinations, EUS-guided FNA was performed in 65 cases. Thirteen patients had two EUS examinations performed either for surveillance or for obtaining better tissue samples. Linear EUS was used

in 122 cases (74.4%) as compared to 42 cases (25.6%) where radial EUS was used. Miniprobe ultrasound was not used in any patient due to its unavailability. In 34 cases (22.5%), no lesion could be identified by EUS. In nine of these 34 patients, lesions were not even visualized grossly by endoscopy; whereas in the remaining 25 patients, they were identified endoscopically but could not be detailed by EUS, mainly due to their small size (mostly less than 5 mm) or due to technical difficulty. Interestingly, seven of the eight proximal lesions could not be seen by EUS.

On the other hand, out of the 117 cases with an identified lesion [Table 3], only 14 (12.0%) were caused by an extraluminal compression as compared to 103 cases (88.0%) having an intramural pathology. Extraluminal lesions were identified as being enlarged lymph nodes (LNs) in four cases; aorta or aortic aneurysm in four cases; dilated left atrium in two cases; and one case of compression by a dilated right atrium (myxoma), an enlarged thyroid gland, and a mediastinal mass or a mediastinal cyst.

Table 2 summarizes the basic characteristics of the patients. Around 55% of the patients were males. The age ranged from 19 to 78 with a mean of 51.8 years. Three patients had multiple lesions. There was no statistically significant difference in sex or age distribution with regard to location or cause of compression.

**Table 2: General characteristics of patients and lesions referred for endoscopic ultrasound evaluation**

Characteristic	N = 151 (%)
Sex	
Male	84 (55.6)
Female	67 (44.4)
Age, years	
≤40	30 (19.9)
41-60	85 (56.3)
>60	36 (23.8)
Size	
<1 cm	38 (25.2)
1-2 cm	52 (34.4)
>2 cm	35 (23.2)
Mean (± SD, min-max) mm	20.3 (±15.1, 5-90)
Not known/Not seen	26 (17.2)
Site	
Proximal (<20 cm)	8 (5.3)
Mid (20-30 cm)	50 (33.1)
Distal (>30 cm)	93 (61.6)

Sixty-five cases were sampled by means of FNA, which constitutes more than half (50.4%) of the patients who had a detectable lesion seen on EUS. Five patients were sampled twice due to an insufficient first sample. To note that all lesions larger than 2 cm were sampled by FNA ( $N = 35$ ). Moreover, all the lesions that were

sampled were 1 cm or larger except for two lesions that measured 5 and 7 mm. Six of these patients had compression by an extrinsic lesion.

Out of these 65 cases, 31 samples (47.7%) were considered insufficient or nondiagnostic [Table 4]. Of the remaining 34 samples, presumed diagnosis was positively confirmed in 32 cases (94.1%) [Table 5]. One of the remaining two cases with a discordant diagnosis was initially reported by the examiner to be a distal 50 mm leiomyoma originating from the muscularis mucosa in a 55-year-old lady. However, the endoscopic biopsies as well as the EUS-guided FNA pathology results were reported as having atypical/malignant cells. Upon reviewing the endoscopic and EUS pictures and videos of this particular case, the lesion appeared in fact to be an infiltrating polypoid mass that was falsely labeled as a subepithelial tumor. The second case was presumably a gastrointestinal stromal tumors (GIST) and the pathological diagnosis was for a neuroendocrine tumor (NET).

Surgical and pathology reports of three other lesions that were surgically removed at our institution were also retrieved. The diagnosis of leiomyoma in two of

**Table 3: Characteristics of the lesions that were detected with endoscopic ultrasound**

Characteristic	N = 117 (%)
Site	
Proximal	1 (0.9)
Mid	42 (39.5)
Distal	74 (63.2)
Size	
<1 cm	21 (17.9)
1-2 cm	51 (43.6)
>2 cm	35 (29.9)
Not measurable*	10 (8.5)
Layer of origin	
Extramural	14 (12.0)
Deep mucosa/Muscularis mucosa	22 (18.8)
Submucosa	33 (28.2)
Muscularis propria	48 (41.0)
Echogenicity	
Hypoechoic	88 (75.2)
Anechoic	25 (21.4)
Hyperechoic	4 (3.4)
US homogeneity	
Homogenous	97 (82.9)
Heterogenous**	20 (17.1)
Presumptive Diagnosis	
Extrinsic compression	14 (12.0)
Leiomyoma	70 (59.8)
Gastrointestinal stromal tumor	7 (6.0)
Lipoma	4 (3.4)
Granular cell tumor	2 (1.7)
Cyst	12 (10.3)
Vascular ectasia	5 (4.3)
Neuroendocrine tumor	3 (2.6)

\*Not measurable: Compression by an extrinsic vessel or organ; \*\*Heterogenous: Areas with different echogenicity including anechoic, hyperechoic or calcified foci

**Table 4: Final results for the 65 cases that had endoscopic ultrasound-guided fine needle aspiration**

FNA final result	% (Number of cases)
Nondiagnostic/ Insufficient sample	47.7 (31)
Leiomyoma	30.7 (20)
Gastrointestinal stromal tumor	6.2 (4)
Cyst*	4.6 (3)
Mediastinal enlarged lymph nodes**	7.7 (5)
Neuroendocrine tumor	1.5 (1)
Atypical cells***	1.5 (1)

\*Two were labelled as duplication cysts and one as a simple cyst; \*\*Four cases were labelled as granulomatous inflammation and one as a metastatic squamous cell carcinoma; \*\*\*This case was an invasive mass falsely labelled as a subepithelial lesion

**Table 5: Final diagnosis based on fine needle aspiration results in correlation with the presumptive diagnosis of sampled patients**

Presumptive Diagnosis (Number of patients sampled among the group)	Final Diagnosis (N, %)					
	Nondiagnostic	Leiomyoma	GIST	Cyst	NET	Malignancy
Leiomyoma (45 out of 80)	25 (55.5)	19 (44.5)	—	—	—	1 (2.2)**
Cyst (3 out of 13)	—	—	—	3 (100)	—	—
GIST (10 out of 10)	5 (50)	—	4 (40)	—	1 (10)	—
NET (1 out of 3)	1 (100)	—	—	—	—	—
Extrinsic lesion (6 out of 14)*	0 (0)	—	—	—	—	—
Lipoma (0 out of 4)	—	—	—	—	—	—
Vascular ectasia (0 out of 5)	—	—	—	—	—	—

\*Four were granulomatous inflammatory lymph nodes, one malignant lymph node and one cyst; \*\*This was an invasive mass falsely labelled as a subepithelial lesion; GIST: Gastrointestinal stromal tumor; NET: Neuroendocrine tumor



these cases (45 and 46 mm in size) was confirmed after surgery. The third lesion that measured 90 mm and was presumably a distal esophageal GIST turned out to be a GIST originating from the gastric cardia.

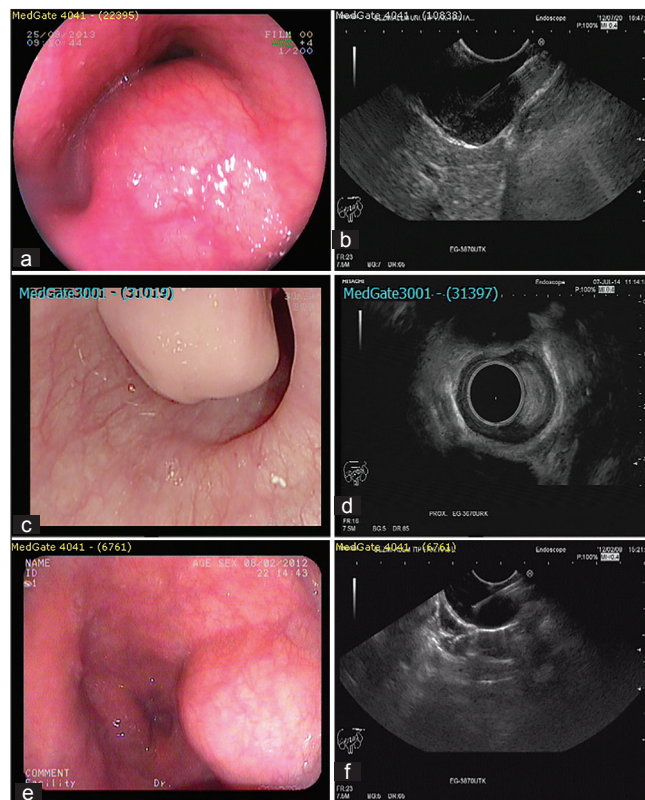
Thirteen patients had EUS examination performed twice. One of these patients had a second look EUS for a small lesion that was not seen in the first examination. Three other examinations were performed within 1-4 months for reobtaining an FNA sample due to a nondiagnostic initial pathology result. Surveillance was the indication for repeating EUS in the remaining nine patients with a time interval of 4-20 months (mean 11.8 months). The lesion was considered to be a leiomyoma in nine cases. The initial sizes of the lesions ranged between 4 and 30 mm. Upon surveillance endosonography, two leiomyomas showed an increase in their sizes by 50%, from 10 to 15 mm after 12 months. The sizes of all the other lesions remained stable or were reported to be even smaller.

None of the patients developed any complications in association with the EUS procedures.

## DISCUSSION

EUS is a helpful and sensitive method in providing information aiding in the diagnosis and prognostication of subepithelial lesions in general. It might be the best modality that can accurately differentiate between a true intramural mass and an extrinsic lesion compressing the wall, which is difficult to determine by regular endoscopy alone. Moreover, it accurately defines the size, margins, vascularity, layer of origin, and the specific echogenicity of the lesion which will help in identifying malignant or high risk lesions, and will also guide to the specific diagnosis in most of the cases.

Combining the data regarding the echogenicity and the layer of origin of the lesion offers the best guide to the diagnosis. An educated guess is sufficient to diagnose some of the lesions without the need for tissue diagnosis as in the case of a hyperechoic lesion arising from the submucosa which is characteristic of a lipoma [Figure 1]. Another example would be an anechoic well-demarcated superficial lesion that is highly suggestive of a benign cyst. Cystic lesions can be differentiated from an isolated varicosity or a vessel by using the Doppler feature during echoendoscopy. A hypoechoic lesion arising in the esophagus from the muscularis mucosa (MM) or muscularis propria (MP)



**Figure 1.** Image a and b; 40 mm hypoechoic lesion arising from the muscularis propria suggestive of leiomyoma. Image c and d; 12 × 18 mm hyperechoic lesion suggestive of lipoma. Image e and f; 14 × 36 mm anechoic lesion suggestive of a cyst

is mostly a leiomyoma (or occasionally the “potentially malignant” GIST which is rarely seen in the esophagus). The differentiation between a leiomyoma and a GIST by EUS alone is very difficult.<sup>[5]</sup> The tumor size and the presence of ulcerations are similar in both cases. The echogenicity leiomyomas was found to be nearly similar to that of the surrounding normal proper muscle layer, whereas more than half of GISTs show higher echogenicity as compared to that of the surrounding normal muscle layer. Moreover, inhomogeneity of the tumor, the presence of hyperechogenic spots, and having a marginal halo were observed more frequently in the GISTs than in the leiomyomas.<sup>[6]</sup>

Imaging using regular echoendoscopy can be optimized by means of water instillation and using minimally inflated water-filled balloons. Moreover, small lesions might be better seen with a fairly technical ease using through-the-scope miniprobe that offer higher frequencies of up to 20-30 MHz. Despite these enhancements, the ability of EUS alone in accurately identifying the layer of origin and its diagnostic accuracy in small upper GI subepithelial lesions was found to

range between 45 and 78% as compared to pathologic diagnosis (FNA or excision).<sup>[7]</sup> In one prospective study including 100 patients with submucosal lesions, the presumptive EUS diagnosis was correct in only 43% of cases.<sup>[8]</sup> Most misdiagnoses occurred in hypoechoic lesions in the third and fourth layers, which include carcinoids, GISTs, aberrant pancreas, and granular cell tumors.

Thus, EUS-guided FNA is sometimes required in certain hypoechoic lesions to provide pathologic confirmation of the diagnosis and to rule out malignancy, which cannot be obtained by the regular biopsy forceps because of the subepithelial nature of the lesion.

However, the diagnostic accuracy of EUS-guided FNA for intramural GI lesions was initially found to range between 60 and 80%,<sup>[9-11]</sup> which is lower than the yield with pancreatic masses or mediastinal LNs. Williams *et al.*, showed that although EUS-guided FNA had an overall accuracy of 89% and 85% for the diagnosis of malignancy in LNs and pancreatic masses, respectively; its accuracy in intramural masses was only 38%. Wiersema *et al.*,<sup>[12]</sup> had slightly better outcomes, with an accuracy of 92 and 90% for the diagnosis of malignancy in LNs and pancreatic masses, respectively, as compared to 67% with intramural lesions, with nearly similar figures for sensitivity and specificity.

More recent studies showed even better results. When compared to the final diagnosis obtained by surgical or endoscopic excision of subepithelial lesions in 67 patients, Çağlar *et al.*,<sup>[13]</sup> found that EUS-guided FNA had a sensitivity of 96%, a specificity of 100%, and a diagnostic yield of 85% if the obtained material was sufficient for evaluation. However, nine patients in this study had samples considered insufficient for definitive diagnosis.

Other than the experience of the endosonographer and the quality of machines and accessories used, few important factors may play a role in enhancing the diagnostic yield of EUS-guided FNA. Immunohistochemical staining is very important to differentiate GISTs from other benign lesions or lymphomas.<sup>[14]</sup> Diagnostic yield was reported to be improved when three or more needle passes were performed (90 vs 78%).<sup>[15]</sup> The yield was found to be comparable when using 22 or 25 Gauge needles,<sup>[15,16]</sup> with some data showing some preference to the 25 Gauge in terms of adequacy.<sup>[17]</sup> The use of Tru-Cut biopsy as an alternative or the presence of an onsite

cytopathologist are also other important factors to improve the diagnostic yield in these cases.<sup>[18,19]</sup>

One of the few studies focusing specifically on esophageal subepithelial lesions is a prospective study from China<sup>[20]</sup> that included 229 patients with suspected esophageal leiomyoma based on EUS findings using miniature ultrasonic probes (frequency of 12 MHz). One hundred and eighteen patients with lesions arising from the muscularis mucosa had endoscopic resection and seven had surgical resection performed. None of these lesions was malignant. The diagnostic accuracy of EUS for the diagnosis of leiomyoma was calculated to be 88.6%. However, with a mean follow-up of 35 months, those who did not receive any therapy did not have any significant progression of their lesions and those patients who had resection did not show any recurrence. Moreover, the results of this study were contradictory to general literature as it showed that more than 78% of esophageal leiomyomas in this population originated from the MM and that one-fourth of them were found in the proximal esophagus.

A retrospective study from Turkey by Oztas *et al.*,<sup>[21]</sup> evaluated 211 patients who were referred for evaluation of submucosal lesions of the upper GI tract. Of these, 41 patients had a suspected esophageal lesion. These lesions were predominantly found in the mid esophagus (61%). External compression of the esophagus by an adjacent vascular structure or an organ was the diagnosis in 23 cases, 17 of which were due to vascular compression (mainly by the aorta). Moreover, EUS failed to detect any lesion and the examination was reported as normal in three out of the 41 patients. Failure rate was even higher for gastric lesions, reaching 26.5% and actual intramural subepithelial pathology was found only in eight out of 166 patients (4.8%). This study, however, did not report any data regarding pathologic diagnosis by FNA or about follow-up.

Rosch *et al.*,<sup>[22]</sup> performed a prospective study that included 150 patients who had EUS for evaluation of a suspected subepithelial lesion discovered by upper endoscopy. EUS was normal in 35 patients (23.3%), showed extraluminal compression in 12 (8%), and intraluminal lesion in 102 patients (68%). The sensitivity and specificity of EUS to differentiate between intraluminal and extraluminal lesions were found to be 92 and 100%, respectively. FNA was performed in 34 patients only.

According to the European Society of Gastrointestinal Endoscopy (ESGE) clinical guidelines,<sup>[23]</sup> EUS-guided FNA is indicated when there is a presumptive diagnosis of unresectable GIST for which treatment with tyrosine kinase inhibitors is contemplated, in patients with previous history of malignancy to rule out metastasis, and when lymphoma is diagnosed, NET or extrinsic tumor is suspected (based on EUS, biological, or clinical criteria). On the other hand, the authors recommended against FNA if surgical excision is considered, or in case of the presence of the typical echo features of a lipoma, and in small (<2 cm) submucosal tumors (SMTs) of the esophagus and the stomach. Moreover, the clinical benefit from sampling of larger lesions in affecting the ultimate management was questioned.

Major clinicopathological differences exist regarding the lesions that arise in the esophagus as compared to the rest of the upper GI tract [Table 6]. For instance, wall compression by an extrinsic lesion or structure is more commonly encountered in the esophagus due to its relatively narrow tubular anatomy. This anatomy also may cause the esophageal lesions to be symptomatic earlier and more often as compared to gastric lesions, thus presenting with dysphagia or globus. On the other hand, 65% of GISTs are found in the stomach;<sup>[24]</sup> whereas, it is exceptionally seen in the esophagus (<1%). In contrast, another mesenchymal tumor, leiomyoma, is by far the most common subepithelial lesion in the esophagus, accounting for approximately 70% of cases, and is only rarely seen in the stomach or the intestines.<sup>[25]</sup> Moreover, leiomyomas in the esophagus were reported in many studies to commonly originate from the MM; whereas it mostly originates from the muscularis propria (MP) when found in the stomach.<sup>[20,26]</sup> Another

characteristic pathologic entity commonly seen only in the esophagus is the granular cell tumor which is extremely rare in the stomach or duodenum. Fortunately both of these common esophageal lesions have no malignant potential.

The relative frequency of having a malignant subepithelial lesion (including high risk GISTs) in the esophagus is very low (<1%) as compared to the duodenum (5%) and the stomach (16%).<sup>[27]</sup>

In one prospective study, complete endoscopic excision of subepithelial esophageal lesions was successful in 61 out of 62 patients, of which 25 were more than 2 cm in size. All the excised tumors turned out to be benign. Fifty-six were leiomyomas, four were granular cell tumor (GCTs), one was a NET, and one was a cyst. With a mean follow-up of 38.4 months, no recurrence was observed.<sup>[28]</sup>

In our study, 27 out of 164 lesions (16.4%) that were referred for EUS evaluation of esophageal subepithelial lesions could not be identified by EUS, which is comparable to other similar studies. This was mostly due to a very small size (<5 mm) of the suspected lesion to start with. Other factors that might prevent the accurate detection of these lesions might be the technical difficulty encountered specifically in the esophagus, especially with proximal lesions. In fact, we failed to detect seven out of the eight referred lesions at this location. Using a miniprobe is of great benefit in certain lesions, especially in the stomach; however in the esophagus, its use might be limited due to the difficulty in achieving water immersion and the increased risk of aspiration.

The majority of our population (76.2%) were younger than 60 years of age. This suggests that esophageal subepithelial lesions are not by necessity age related. In fact, there was no statistically significant difference in sex or age distribution with regard to location or cause of compression.

The mean size of the detected lesions was 20.3 mm. Nearly half of the lesions were larger than 1 cm and a quarter was larger than 2 cm.

The rate of performing FNA was considerable in our study. Sixty-five lesions were sampled. The selection of cases depended mainly on the size (all lesions >2 cm were biopsied) and on the discretion and

**Table 6: Comparison between the frequency of various subepithelial lesions in the esophagus and the stomach/duodenum**

Lesion	Esophagus	Stomach/duodenum
Leiomyoma	Most common (70%)	Rare
Gastrointestinal stromal tumor	Rare (1-2%)	Most Common (50%)
Granular cell tumor	Common (13-20%)	Rare (1%)
Cysts	Common (10%)	Common (10%)
Lipoma	Occasional (1%)	Occasional (5%)
Haemangioma	Occasional (1%)	Occasional (1%)
Pancreatic rest	Absent	Common (16%)
Carcinoid	Absent	Occasional (3-10%)
Extrinsic compression	Common	Less common



evaluation of the endoscopist for smaller lesions. Unfortunately, the sample was considered nondiagnostic or insufficient in around 50% of cases. This might be due to performing only one pass per examination in most of these patients, the use of only one modality for sampling (FNA), the lack of onsite pathologist, as well as the known low yield in this type of lesions due to the difficulty in retrieving a cell block. Of these factors, increasing the number of passes to at least three passes would be the best and the most feasible approach to improve the yield. However, in the pathology samples that yielded a positive result, the final diagnosis was confirmative to the initial presumptive diagnosis in 94.1%.

When performing surveillance EUS with or without FNA, no increase in the size or change in the diagnosis was noted in 11 out of 13 cases with a mean follow-up period of approximately 12 months. Two cases showed an increase in the size from 10 to 15 mm over 1 year.

In all of the detected lesions, EUS examination offered a fairly accurate and detailed recognition of the type of the lesion. It was very sensitive in differentiating between intraluminal and extraluminal lesions. However, when critically analyzing all the patients who had lesions less than 2 cm in size, EUS with or without FNA offered no clinically significant benefit over endoscopic evaluation or follow-up. None of these patients had any change in the ultimate management plan except for labeling the type of the lesion. Neither surveillance nor resection was recommended for any of these cases. Moreover, all the four cases with FNA results suggesting the diagnosis of GIST were at least 30 mm in size. On the other hand, the only case where malignant cells were retrieved turned out to be an infiltrating mass rather than a subepithelial lesion and it was readily diagnosed with regular endoscopic biopsies.

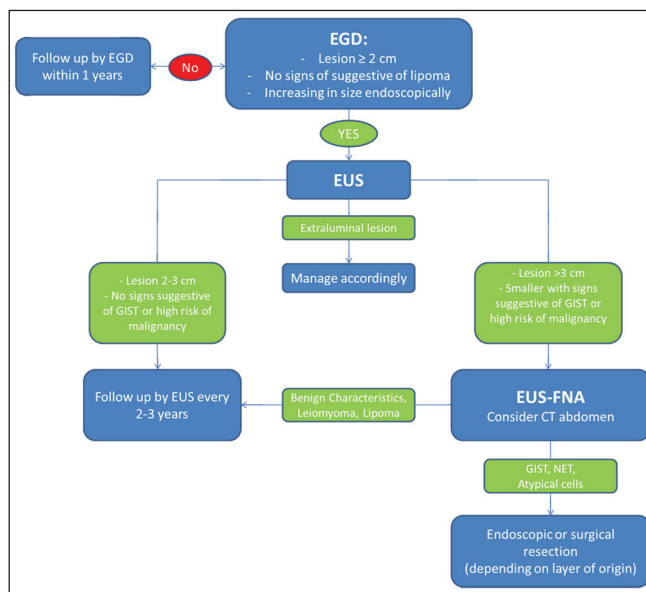
A major limitation of our study is that it is retrospective. However, the number of patients and number of FNA examinations was considerable and allowed for the above mentioned analysis. Moreover, information on the indication for the initial upper GI endoscopic evaluation was not readily accessible for all patients. Although the low yield of FNA decreased the number of patients with a confirmed diagnosis, the data shown confirms the belief that multiple needle passes should be attempted for subepithelial lesions in order to improve the sample quality and size.

## CONCLUSION

In general, EUS examination for subepithelial lesions offers a great deal of information regarding their location (intramural or extraluminal), echogenic characteristics, and their malignant potential.

Given the generally highly favorable prognosis of esophageal subepithelial lesions as compared to gastric lesions, and the lack of clinically significant impact of using EUS or EUS-guided FNA in the ultimate management of small lesions, we recommend against routine referral of patients with lesions less than 2 cm for EUS evaluation as this might significantly increase the cost with no major impact on the decisions. For lesions 3 cm or larger, a pathologic evaluation, probably by means of multiple passes FNA or by endoscopic or surgical resection is suggested to rule out the presence of GIST or less likely atypical cells. For extraluminal lesions, decision should be made depending on the individual case.

The algorithm shown below suggests a management approach to patients found to have esophageal subepithelial lesions on endoscopy [Figure 2]. This algorithm reflects our own experience and practice in our institution. It is based solely on expert opinion and on the current presented data. We believe that the suggested time frames for follow-up and the cutoffs for the sizes are reasonable although they are not



**Figure 2.** Management algorithm of esophageal subepithelial lesions. EGD: Esophagogastroduodenoscopy, EUS: Endoscopic ultrasound, EUS-FNA: Ultrasound-guided fine needle aspiration, GIST: Gastrointestinal stromal tumor, NET: Neuroendocrine tumor



based on solid prospective data or randomized studies. Further studies are needed to improve the management strategies and plans for these frequently encountered lesions.

### Financial support and sponsorship

Nil.

### Conflicts of interest

There are no conflicts of interest.

## REFERENCES

- Hoda KM, Rodriguez SA, Faigel DO. EUS-guided sampling of suspected GI stromal tumors. *Gastrointest Endosc* 2009;69:1218-23.
- Xu GQ, Li YW, Han YM, *et al.* Miniature ultrasonic probes for diagnosis and treatment of digestive tract diseases. *World J Gastroenterol* 2004;10:1948-53.
- Choong CK, Meyers BF. Benign esophageal tumors: Introduction, incidence, classification, and clinical features. *Semin Thorac Cardiovasc Surg* 2003;15:3-8.
- Hwang JH, Rulyak SD, Kimmey MB. American Gastroenterological Association Institute. American Gastroenterological Association Institute technical review on the management of gastric subepithelial masses. *Gastroenterology* 2006;130:2217-28.
- Miettinen M, Lasota J. Gastrointestinal stromal tumors — definition, clinical, histological, immunohistochemical and molecular features and differential diagnosis. *Virchows Arch* 2001;438:1-12.
- Kim GH, Park do Y, Kim S, *et al.* Is it possible to differentiate gastric GISTs from gastric leiomyomas by EUS? *World J Gastroenterol* 2009;15:3376-81.
- Karaca C, Turner BG, Cizginer S, *et al.* Accuracy of EUS in the evaluation of small gastric subepithelial lesions. *Gastrointest Endosc* 2010;71:722-7.
- Hwang J, Saunders M, Rulyak SJ, *et al.* A prospective study comparing endoscopy and EUS in the evaluation of GI subepithelial masses. *Gastrointest Endosc* 2005;62:202-8.
- Moon JS. Endoscopic ultrasound-guided fine needle aspiration in submucosal lesion. *Clin Endosc* 2012;45:117-23.
- Vander Noot MR 3rd, Eloubeidi MA, Chen VK, *et al.* Diagnosis of gastrointestinal tract lesions by endoscopic ultrasound-guided fine needle aspiration biopsy. *Cancer* 2004;102:157-63.
- Williams DB, Sahai AV, Aabakken L, *et al.* Endoscopic ultrasound guided fine needle aspiration biopsy: A large single centre experience. *Gut* 1999;44:720-6.
- Wiersema MJ, Vilman P, Giovannini M, *et al.* Endosonography guided fine-needle aspiration biopsy: Diagnostic accuracy and complication assessment. *Gastroenterology* 1997;112:1087-95.
- Cağlar E, Hatemi I, Atasoy D, *et al.* Concordance of endoscopic ultrasonography-guided fine needle aspiration diagnosis with the final diagnosis in subepithelial lesions. *Clin Endosc* 2013;46:379-83.
- Fu K, Eloubeidi MA, Jhala NC, *et al.* Diagnosis of gastrointestinal stromal tumor by endoscopic ultrasound-guided fine needle aspiration biopsy — A potential pitfall. *Ann Diagn Pathol* 2002;6:294-301.
- Rong L, Kida M, Yamauchi H, *et al.* Factors affecting the diagnostic accuracy of endoscopic ultrasonography-guided fine needle aspiration (EUS-FNA) for upper gastrointestinal submucosal or extraluminal solid mass lesions. *Dig Endosc* 2012;24:358-63.
- Vilman P, Săftoiu A, Hollerbach S, *et al.* Multicenter randomized controlled trial comparing the performance of 22 gauge versus 25 gauge EUS-FNA needles in solid masses. *Scand J Gastroenterol* 2013;48:877-83.
- Affolter KE, Schmidt RL, Matynia AP, *et al.* Needle size has only a limited effect on outcomes in EUS-guided fine needle aspiration: A systematic review and meta-analysis. *Dig Dis Sci* 2013;58:1026-34.
- Keswani RN, Krishnan K, Wani S, *et al.* Addition of endoscopic ultrasound (EUS)-guided fine needle aspiration and on-site cytology to EUS-Guided fine needle biopsy increases procedure time but not diagnostic accuracy. *Clin Endosc* 2014;47:242-7.
- Turhan N, Aydog G, Ozin Y, *et al.* Endoscopic ultrasonography guided fine-needle aspiration for diagnosing upper gastrointestinal submucosal lesions: A prospective study of 50 cases. *Diagn Cytopathol* 2011;39:808-17.
- Xu GQ, Qian JJ, Chen MH, *et al.* Endoscopic ultrasonography for the diagnosis and selecting treatment of esophageal leiomyoma. *J Gastroenterol Hepatol* 2012;27:521-5.
- Oztas E, Oguz D, Kurt M, *et al.* Endosonographic evaluation of patients with suspected extraluminal compression or subepithelial lesions during upper gastrointestinal endoscopy. *Eur J Gastroenterol Hepatol* 2011;23:586-92.
- Rosch T, Kapfer B, Will U, *et al.* German EUS Club. Endoscopic ultrasonography. Accuracy of endoscopic ultrasonography in upper gastrointestinal submucosal lesions: A prospective multicenter study. *Scand J Gastroenterol* 2002;37:856-62.
- Dumonceau JM, Polkowski M, Larghi A, *et al.* European Society of Gastrointestinal Endoscopy. Indications, results, and clinical impact of endoscopic ultrasound (EUS)-guided sampling in gastroenterology: European Society of Gastrointestinal Endoscopy (ESGE) clinical guideline. *Endoscopy* 2011;43:897-912.
- Chak A. EUS in submucosal tumors. *Gastrointest Endosc* 2002;56:S43-8.
- Polkowski M, Butruk E. Submucosal lesions. *Gastrointest Endosc Clin N Am* 2005;15:33-54, viii.
- Xu GQ, Zhang BL, Li YM, *et al.* Diagnostic value of endoscopic ultrasonography for gastrointestinal leiomyoma. *World J Gastroenterol* 2003;9:2088-91.
- Polkowski M. Endoscopic ultrasound and endoscopic ultrasound guided fine needle aspiration for the diagnosis of malignant submucosal tumors. *Endoscopy* 2005;37:635-45.
- Hyun JH, Jeon YT, Chun HJ, *et al.* Endoscopic resection of submucosal tumor of the esophagus: Results in 62 patients. *Endoscopy* 1997;29:165-70.