



The Brazilian Journal of INFECTIOUS DISEASES

www.elsevier.com/locate/bjid



Clinical image

Pott abscess mimicking aortic aneurysm in chest X-ray

Yasemin Akkoyunlu^a, Turan Aslan^a, Muhammed Emin Akkoyunlu^{b,*}

^a Bezmialem Vakif University, School of Medicine, Department of Infectious Diseases and Clinical Microbiology, Istanbul, Turkey

^b Bezmialem Vakif University, School of Medicine, Department of Pulmonary Medicine, Istanbul, Turkey

ARTICLE INFO

Article history:

Received 20 June 2012

Accepted 24 June 2012

Available online 16 January 2013

Drug resistance in tuberculosis is an exponential problem all around the world. Spondylodiscitis and osteomyelitis are other challenges for specialists to overcome. When the problem occurs due to multidrug-resistant tuberculosis (MDR), it appreciable grows.

A 21-year-old man presented with sloping cervical mass. He was diagnosed with lymphadenitis caused by tuberculosis and taking antituberculosis drugs for 5 months. He received isoniazid, rifampin, ethambutol, and morfosinamide for 2 months and then continue with isoniazid and rifampin. At the end of second month the leakage stopped, but one month later, leakage from the lymphadenitis reoccurred. He had night sweats, and weight loss that never decreased with antibiotherapy. He presented with serious back pain since last year. He had no history of lung tuberculosis, but his family members presented with tuberculosis. His father had lung tuberculosis whereas his mother and sister had tuberculosis lymphadenitis. All of them received standard antituberculosis therapy and their therapy was successfully completed. In our patient computerized tomography (CT) scanning of thorax demonstrated a Pott abscess formation, nearly 15 cm length between thoracic vertebrae 5 and 11, which may be easily misdiagnosed as an aortic aneurysm with the imagination on chest X-ray (Figs. 1 and 2). Microbiological sample was

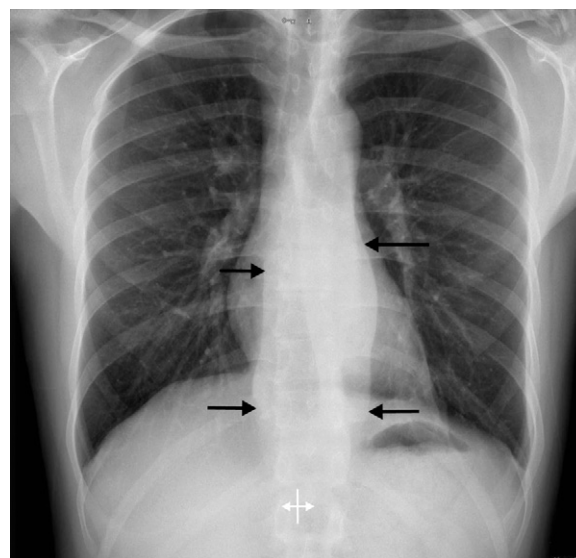


Fig. 1 – Chest X-ray imagination showing the borders of abscess which mimicks aortic aneurysm.

* Corresponding author at: Bezmialem Vakif University, School of Medicine, Department of Pulmonary Medicine, Vatan Cad. Fatih 34093, Istanbul, Turkey. Tel.: +90 2124531700.

E-mail address: eminakkoyunlu@gmail.com (M.E. Akkoyunlu).

1413-8670 © 2013 Elsevier Editora Ltda. Este é um artigo Open Access sob a licença de [CC BY-NC-ND](https://creativecommons.org/licenses/by-nc-nd/4.0/)

<http://dx.doi.org/10.1016/j.bjid.2012.06.028>

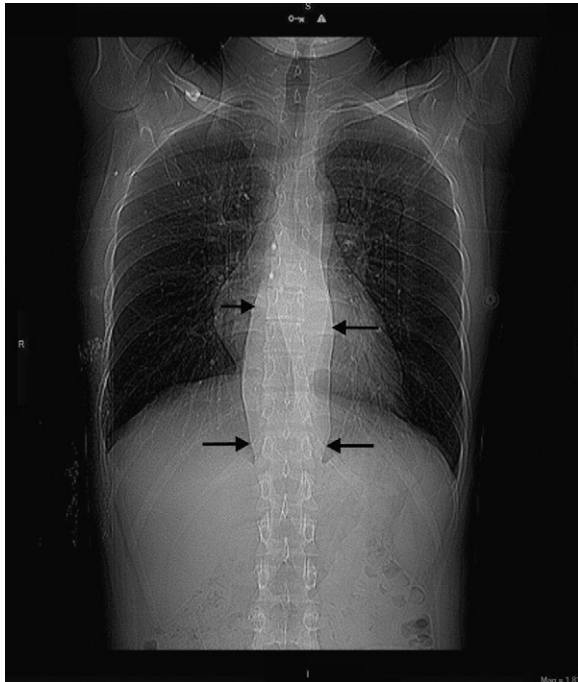


Fig. 2 – Computerized tomography (CT) imagination of Pott's abscess.

taken with CT-guided biopsy. Only one acid fast bacilli (AFB) was seen with AFB stain. *Mycobacterium tuberculosis* yielded at Lowenstein-Jensen culture medium. This bacilli was found resistant to all primary antituberculosis therapeutic agents that he was taking. His therapy was stopped and amikacin 1 g/day + ethionamide 1000 mg/day + cycloserine 1000 mg/day + ofloxacin 400 mg/day + prazinaimide 2500 mg/day was given.

Drug resistance must be thought in patients who do not improve with standard antituberculosis therapy. According to our knowledge this was the first case of vertebral osteomyelitis caused by MDR tuberculosis in Turkey.

Conflict of interest

The authors have no conflict of interest to declare.