

Multidirectional instability of the shoulder: surgical techniques and clinical outcome

Koray Şahin¹, Alper Şükrü Kendirci², Muhammed Oğuzhan Albayrak³, Gökhan Sayer⁴ and Ali Erşen³

¹Bezmalem Vakif University, Department of Orthopedics and Traumatology, Istanbul, Turkey

²Erciş Şehit Rıdvan Çevik State Hospital, Department of Orthopedics and Traumatology, Van, Turkey

³Istanbul University Istanbul Faculty of Medicine, Department of Orthopedics and Traumatology, Istanbul, Turkey

⁴Muş State Hospital, Department of Orthopedics and Traumatology, Muş, Turkey

Correspondence should be addressed to Koray Şahin

Email
drkoraysahin@gmail.com

- Multidirectional instability of the shoulder has a complex pathoanatomy. It is characterized by a redundant glenohumeral capsule and increased joint volume.
- Subtle clinical presentation, unclear trauma history and multifactorial etiology poses a great challenge for orthopedic surgeons in terms of diagnosis.
- Generally accepted therapeutic approach is conservative and the majority of patients achieve good results with rehabilitation.
- In patients who are symptomatic despite appropriate rehabilitation, surgical intervention may be considered.
- Good results have been obtained with open inferior capsular surgery, which has historically been performed in these patients.
- In recent years, advanced arthroscopic techniques have taken place in this field, and similar results compared to open surgery have been obtained with the less-invasive arthroscopic capsular plication procedure.

Keywords

- ▶ multidirectional shoulder instability
- ▶ open inferior capsular shift
- ▶ arthroscopic capsular plication

EFORT Open Reviews
(2022) 7, 772–781

Introduction

Multidirectional instability (MDI) of the shoulder was first described by Neer and Foster as instability of the shoulder to more than one direction, without the history of trauma or following minimal trauma (1). Although different definitions were tried to be made for MDI in the following years, there is still no consensus for this pathology in the literature, so the definition made by Neer and Foster is still mostly accepted as the most valid definition. Since the first definition of MDI, glenohumeral joint stability has been better understood thanks to advances in basic science, shoulder biomechanics and clinical concepts. However, MDI still poses a great challenge for orthopedic surgeons in terms of diagnosis and treatment. The main culprit for this difficulty is the unique complexity of glenohumeral joint stability.

Three different instability forms were reported according to the direction of the dislocation: anteroinferior dislocation accompanying posterior subluxation and posteroinferior dislocation accompanying anterior subluxation and global dislocation (1, 2). In addition to these, instabilities with two or three directions have also been described in

previous studies (3, 4). Matsen *et al.* labeled shoulder instability into two groups with the abbreviations TUBS (traumatic, unilateral, Bankart lesion and surgery) and AMBRI (atraumatic, multidirectional, bilateral, rehabilitation, inferior capsular shift) (5). However, since distinctions between instability-laxity and microtrauma-macrotrauma are not made in this classification, it is insufficient in the evaluation of MDI. Distinction between the terms 'laxity and instability' must be clearly made in order to diagnose and treat MDI. The concept of laxity can be defined as an increase in physiological range of motion and increase in joint elasticity; however, it is an asymptomatic condition, considered physiological and may be one of the predisposing factors causing instability (6, 7). On the contrary, instability is a symptomatic and pathological condition and may develop after repetitive microtrauma or a single macrotrauma. Gerber and Nyffeler established a more comprehensive classification under the term 'dynamic instabilities' that allows understanding of the pathogenesis, identifying different MDI populations and guiding treatment (8) (Table 1). However, since it is a multifactorial pathology, it is very difficult to make a complete classification of shoulder instability.

Table 1 Dynamic shoulder instability classification of Gerber and Nyfeller (8).

Classification	Description
B1: Chronic locked dislocation	Locked instability caused by major trauma
B2: Unidirectional instability without hyperlaxity	Symptoms appear in a single direction Frequent traumatic capsulolabral lesions
B3: Unidirectional instability with hyperlaxity	Symptoms appear in a single direction Frequent patulous capsular tissue Capsulolabral lesions are uncommon
B4: Multidirectional instability without hyperlaxity	Symptoms appear in two or more directions Frequent anterior and posterior capsulolabral lesions
B5: Multidirectional instability with hyperlaxity	Symptoms appear in two or more directions Frequent patulous capsular tissue Signs of generalized hyperlaxity usually present Frequent recurrent subluxations
B6: Instability with voluntary reduction	Dislocation is not noticed at first and voluntary reduction is symptomatic. Over time, patients learn to voluntarily dislocate and reduce their shoulders.

Biomechanics and pathoanatomy

Treatment of MDI should be planned individually for each patient after detailed anamnesis and physical examination. Knowledge about the biomechanics of glenohumeral joint and understanding the pathogenesis of existing instability and anatomical lesions are of great importance in making the surgical decision and choosing the correct procedure to be performed. Glenohumeral joint stability is mainly provided by the mutual effect of two components: static and dynamic stabilizers. Static stabilizers consist of the glenoid version and concavity, labral structures and glenohumeral ligaments, while dynamic stabilizers are scapulothoracic muscles, rotator cuff, joint proprioception and neuromuscular control around the joint (Table 2). In cases where some of these stabilizers are defective, stability can usually be maintained by the compensation of other components. According to this concept which is called ‘functional stability’, the preservation of stabilization in a normal shoulder depends on the coordination of these different mechanisms which are responsible for stabilization during shoulder movement. This coordination is ensured by protection of the concavity-compression mechanism provided by the rotator cuff during motion, correct positioning and version of scapula and therefore glenoid with the effect of scapulothoracic muscles and neuromuscular proprioception control (9, 10, 11). In patients with MDI, simultaneous deteriorations in static and dynamic mechanisms are usually present. Although there are rare cases with impairments in only dynamic stabilizer mechanisms, no isolated static stabilizer mechanism defect was found (12).

A patulous capsular tissue with loose and redundant inferior capsule and increase in glenohumeral joint

volume are characteristic findings of MDI and present in all shoulders with MDI. Evaluations performed using magnetic resonance arthrography showed that posteroinferior and inferior capsule dimensions were increased in all symptomatic MDI patients (13). However, this finding alone is not sufficient for the development of a symptomatic MDI because same condition has been shown to be present in some asymptomatic individuals and in 23% of fetal shoulders. These findings indicate that the etiology of this redundancy of the capsule may not be only traumatic but also developmental (14).

Surgical treatment

First line of treatment is rehabilitation in MDI for all patients (3, 5, 15). The goal of rehabilitation is to do proprioception training by strengthening the periscapular muscles and rotator cuff muscles, thus enabling the patient to regain active control over the shoulder by improving the impaired dynamic stabilization mechanisms (16, 17). Instability is due to a combination of defects in the static and dynamic shoulder stabilizers. Rehabilitation will act upon the dynamic stabilizers and also attempt to compensate for static stabilizer deficiencies. Traditionally recommended rehabilitation programs mainly focused on the rotator cuff. With recent changes in the understanding of shoulder biomechanics, emphasis has been put on exercises for deltoid and scapular stabilizers in combination with proprioceptive and plyometric training (18).

The vast majority of patients respond well to rehabilitation and good results are obtained with current rehabilitation programs. Previous studies reported that rehabilitation is associated with good functional outcomes and low recurrence rates in MDI patients, especially in atraumatic cases. Poorer results were obtained in cases with trauma history or in young athletes who needed surgical intervention due to persisting instability in one-third of patients. Moreover, patients in these studies who did not respond well to physiotherapy within 3 months did not seem to improve in the following months despite

Table 2 Components providing the stability of glenohumeral joint.

Static stabilizers	Dynamic stabilizers
Glenoid version and concavity	Scapulothoracic muscles
Labrum	Rotator cuff
Glenohumeral ligaments	Proprioceptive and neuromuscular control

persistent therapy (15, 19). In a biomechanical study conducted by Nyiri *et al.*, it was shown that rehabilitation alone is not sufficient to regain impaired shoulder kinematics in patients with MDI (20). In addition, it has been reported that surgery may be necessary to restore normal muscle activity when rehabilitation fails (21, 22). Currently accepted management is that surgical intervention should be considered only for a limited group of patients whose symptoms persist despite the appropriate rehabilitation program. Surgical treatment should be avoided especially in patients with voluntary dislocation, in the presence of psychiatric pathology and in young patients who are thought to be unable to accord with surgery (23). In a recent study, it was reported that there was a strong association between post-operative shoulder disability and pre-operative biopsychological factors such as depression and that psychological comorbidities had significant negative impact on functional outcomes following surgery for atraumatic shoulder instability (24). Therefore, surgical treatment should be individualized according to symptoms, psychosocial status of the patient and anatomical lesions causing instability. Consequently, the main indication for surgery in MDI is confined to a small patient population who were compliant with rehabilitation program but who continue to experience debilitating symptoms with a concrete anatomical lesion causing instability. Surgery is contraindicated in atraumatic cases with possible psychological comorbidities and worker's compensation claims. Many surgical techniques have been described in the surgical treatment of MDI. Reconstructive techniques include glenoid osteotomy, labral augmentation and capsuloligamentous reconstruction procedures. Currently, the most commonly used techniques are open inferior capsular shift and arthroscopic plication techniques, which are capsuloligamentous reconstruction techniques (11).

Open inferior capsular shift

Open inferior capsular shift procedure was described by Neer (1) and has been widely used as the gold standard method in the surgical treatment of MDI until the late 1990s (25). Although arthroscopic techniques are more frequently used in current practice, open inferior capsular shift procedure has been still preferred by some surgeons and has been reported to have good outcomes in long-term follow-up (25, 26, 27). However, it is still not clear whether open or arthroscopic techniques are the best option in the surgical management of MDI.

The aim of this procedure is to achieve a reduction in anterior, inferior and posterior capsular volume by performing a plication of the inferior capsule. Following a detailed examination under general anesthesia and determination of the dominant direction of instability,

the patient is prepared in beach-chair position. A deltopectoral approach is used with a 7–8 cm incision extending from coracoid process to axilla. Deltoid, pectoralis major muscles and cephalic vein are exposed and dissection is deepened between these two muscles. Then conjoint tendon is exposed and retracted medially. As described in the original technique, the subscapularis muscle can be elevated by a complete vertical tenotomy or by performing an inverted 'L'-shaped tenotomy to preserve anterior circumflex vascular structures and lower muscular attachment in order to reduce the possibility of axillary nerve injury (28). In order to reduce the possibility of post-operative subscapularis deficiency or external rotation limitation that may develop due to the healing of the subscapularis tenotomy by scarring, a less-invasive muscle-sparing approach parallel to the muscle fibers of subscapularis can be used (29). This procedure should be performed between the upper 2/3 and lower 1/3 fibers of the subscapularis muscle, from musculotendinous junction to the medial border of long head of the biceps tendon. The capsule is then exposed by blunt dissection. Capsular incision is then performed in a 'T' shape, with the top of the 'T' either laterally (humeral) as described by Neer and Foster (1) or medially (glenoid) (2). The lateral approach is more advantageous because it exposes larger capsular tissue, allows for more plication and axillary nerve injury possibility is less likely (30). After capsulotomy, the capsular flaps are carefully lifted from humeral neck and shifted to opposite side in order to eliminate the redundancy of the inferior capsular pouch. The amount of capsular shifting is of great importance in order to provide stability, prevent recurrences and minimize post-operative range of motion limitation. Therefore, this procedure is performed at 45° of abduction and in neutral rotation (31). First, the inferior flap is shifted superiorly deep into the superior limb and then fixed with #2 non-absorbable sutures. The superior flap is mobilized laterally and inferiorly and then sutured over the shifted inferior flap in a similar manner to the arm in adduction and neutral rotation (Fig. 1). If a tenotomy was performed, subscapularis tendon is re-inserted to its anatomical location.

The success of instability surgery is assessed by persistent apprehension test positivity, recurrent subluxation, functional scoring scales and patient's ability to return to pre-operative sportive activity level (11). Previous studies conducted according to these criteria reported that the effectiveness of inferior capsular shift combined with Bankart repair was approximately 95%. However, the level of return to sports was found to be lower than expected (2, 4). Another previous study reported high patient satisfaction and low instability recurrence rates following open inferior capsular shift surgery (30). In a systematic review by Longo *et al.*,

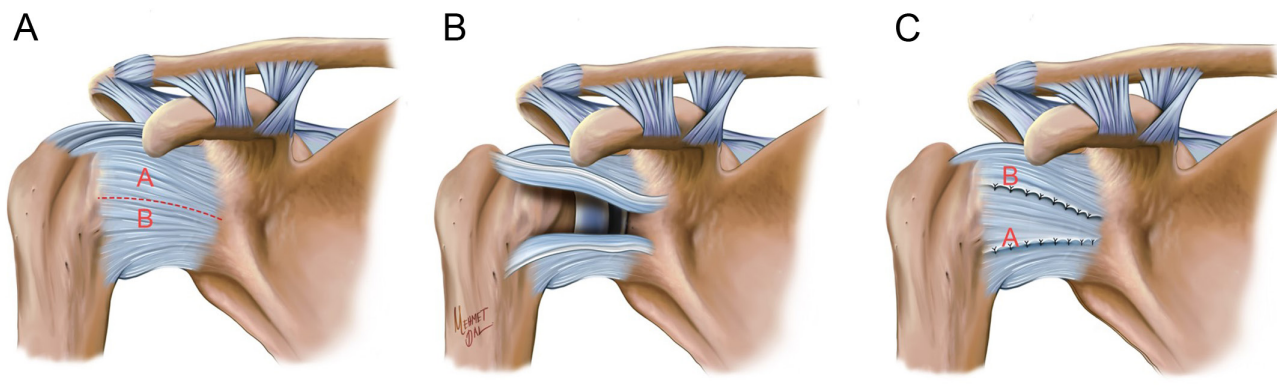


Figure 1

Illustration of open inferior capsular shift procedure. (A). Capsular incision is performed creating superior (A) and inferior (B) capsular flaps. (B). The capsular flaps are elevated and advanced in the opposite direction. The inferior flap is shifted first superiorly. (C) The flaps are then sutured.

redislocation rate after 4 years of follow-up was reported to be only 7.5% in 226 patients (26).

As mentioned before, the purpose of this procedure is to decrease joint volume by performing capsular plication. The reduction of joint volume is proportional to the amount of capsular shift performed. In their study, Miller *et al.* compared different capsular shift techniques in terms of obtained amount of reduction in joint volume (32). They showed that lateral (humeral)-sided capsulotomy provides significantly higher decrease in joint volume compared to medial (glenoid) sided capsulotomy. It has been reported that up to 50% decrease in joint volume can be achieved with open inferior capsular shift technique; however, its clinical reflection is still unknown (32, 33).

Arthroscopic capsular plication

Arthroscopic techniques are less invasive compared to open techniques, provide opportunity to preserve dynamic stabilizers (such as subscapularis muscle) and provide better visualization and opportunity to approach accompanying intra-articular lesions and capsulolabral changes which are specific to MDI such as redundant inferior capsule. Therefore, It has become the preferred method in current practice (34). Another advantage of arthroscopic techniques is that anteroinferior and posteroinferior patulous capsule can be approached in a single intervention and also they provide the opportunity to approach each region selectively (11). Deficient posterior labrum may contribute to instability by causing relative glenoid retroversion in some MDI patients (35). Compared to open techniques, this condition is easier to visualize arthroscopically and if necessary, to augment the labral structures (35).

Arthroscopic capsular plication can be performed either in beach-chair or lateral decubitus position. Before starting the procedure, the patient should be examined under

general anesthesia in order to re-assess the dominant direction of the instability and the amount of translation. Posterior portal should be established more laterally than usual so that posteroinferior capsule and posterior glenoid can be evaluated. During diagnostic arthroscopy, all intra-articular structures, possible labral lesions and redundancy of inferior capsule should be systematically evaluated. The ‘drive-through’ sign observed during arthroscopy is a typical finding of patulous capsule (34) and indicates the need for capsular plication (31) (Fig. 2 and 3).

It is important to evaluate the capsule not only on the glenoid side but also on the humeral attachment side in order to avoid neglecting a possible humeral avulsion of the glenohumeral ligaments (HAGL) lesion. In

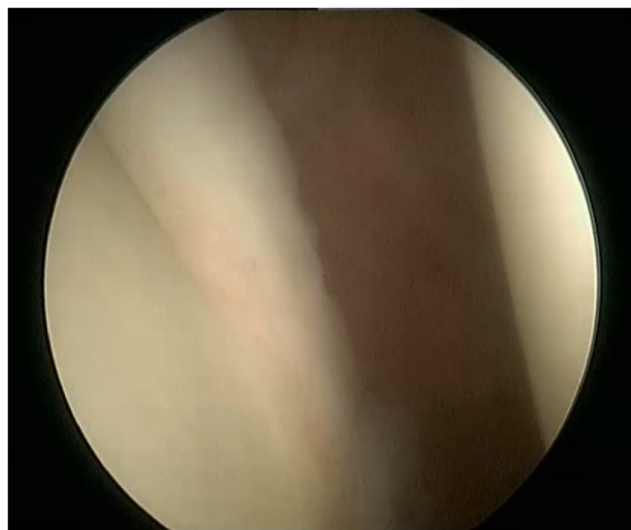


Figure 2

The arthroscope is easily advanced inferiorly between glenoid and humerus indicating laxity of the shoulder (drive-through sign).

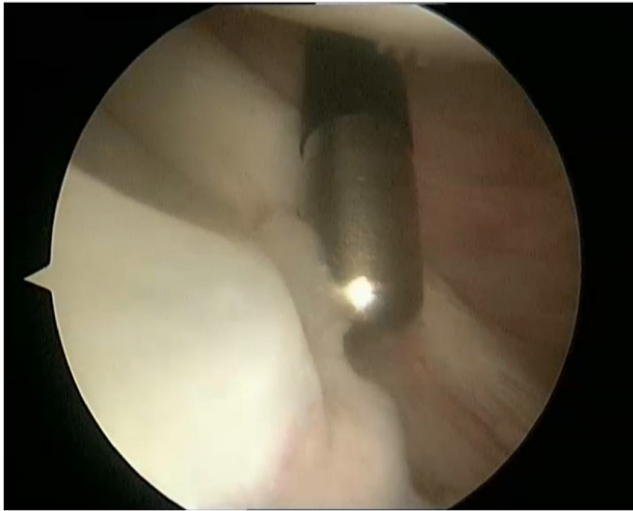

Figure 3
 Deficiency of labrum and loose inferior glenohumeral ligament (IGHL) at inferior glenoid in the 5 o'clock position.

addition, the humeral head should be evaluated for the presence of a Hill-Sachs lesion and these lesions should be approached if necessary regarding the location and size of the existing lesion.

Following diagnostic arthroscopy, anterosuperior and anteroinferior portals are established. Anterior portals are used for instrumentation, while posterior portal is used for visualization. The plication is performed following abrasion of the capsule with a rasp (Fig. 4). The sequence of capsular reconstruction should begin in direction of the primary instability in order to enhance healing (11). However, since inferior capsular plication would be

required in most cases (13) and each plication narrows the joint space and working area, repair should be performed from inferior to superior. Thus, visualization is facilitated during procedure and inferior capsule is shifted superiorly. When necessary, anterior view can be obtained by switching the portals.

In case of an intact labrum, capsular tissue can be fixed directly to the labrum with sutures passed through the capsule (34), because it has been reported that healthy labrum tissue has biomechanically similar load-to-failure compared to suture-anchor (36). However, due to concern about the labral integrity and need for augmentation of labral height in most patients, fixation using suture anchors can be preferred (Fig. 5). The reduction in capsular volume is proportional to the amount and size of the plication. Studies have shown that the arthroscopic capsular plication technique reduces capsular volume as effectively as the open capsular shift technique (37, 38). In their cadaveric study, Flanigan *et al.* reported that 5 mm capsular plication provided 16.2% decrease in joint volume and 10 mm plication provided 33.7% decrease in joint volume (39). In another cadaveric study, it has been reported that multiple anterior, posterior and inferior arthroscopic plications resulted in significantly greater volume reduction compared to open inferior capsular shift procedure (40). In their study, Lubiatuski *et al.* reported that arthroscopic techniques lead to a significant joint volume reduction; most powerful volume reduction achieved in arthroscopic capsular shift procedure (41).

Reduction in capsular volume is clinically beneficial only if it provides an increase in glenohumeral stability. Previous reports have shown that capsulolabral augmentation and plication increase stability by reducing

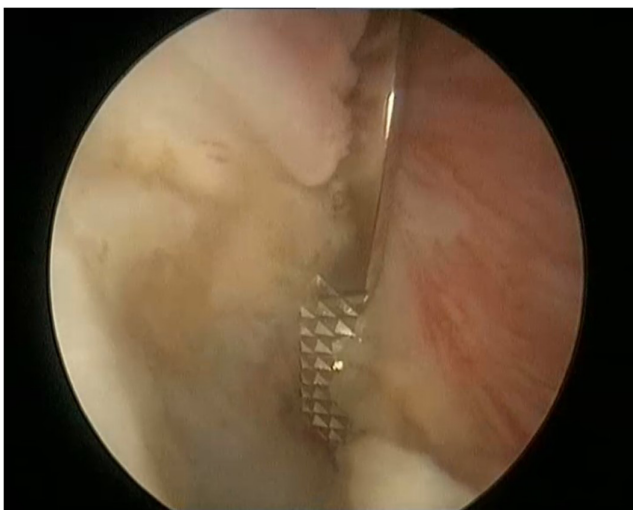


Figure 4
 Abrasion of capsule and inferior glenohumeral ligament (IGHL) with a rasp.

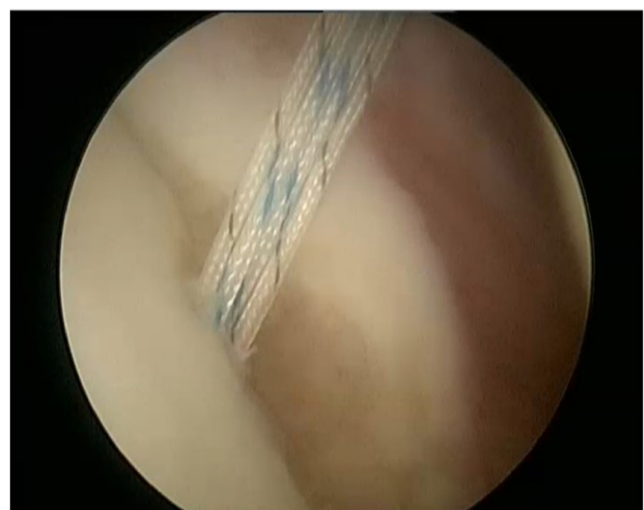

Figure 5
 Insertion of a double-loaded suture-anchor in order to perform capsular plication.

capsular laxity and increasing glenoid concavity (42, 43) (Fig. 6 and 7). In their study conducted with 47 MDI patients treated arthroscopically, Gartsman *et al.* reported good or excellent clinical outcomes in 94% of patients and significant improvement in functional outcomes. Importantly, the authors also reported a return to sportive activity at a desired level in 85% of patients (44). In another study, Baker *et al.* reported similar clinical outcomes and rate of return to sports (45). Recent findings in the literature suggest that the arthroscopic technique may be superior to the open technique in terms of return to sports in appropriately selected patients (44, 45, 46). However, there is still no consensus on the advantages and disadvantages of these techniques over each other (Table 3). In a systematic review by Longo *et al.*, the two techniques have been shown to have similar redislocation rates, post-operative loss of external rotation, return to sports and complication rates (26). In another study comparing open and arthroscopic techniques; Chen *et al.* reported that the two techniques had similar results in terms of recurrent instability and re-operation rates. However, they reported that external rotation limitation was higher in open technique (27).

Excessive plication in arthroscopic capsular plication procedure may lead to limitation of motion, especially loss of external rotation (47, 48). Therefore, appropriate determination of the amount of plication is important for clinical success. Determination of the amount of plication is subjective, depends on the experience of the surgeon and should be determined individually for each patient according to the severity of the instability. During the procedure, excessive plication should be avoided by comparing the shoulder movement with the opposite side (11).

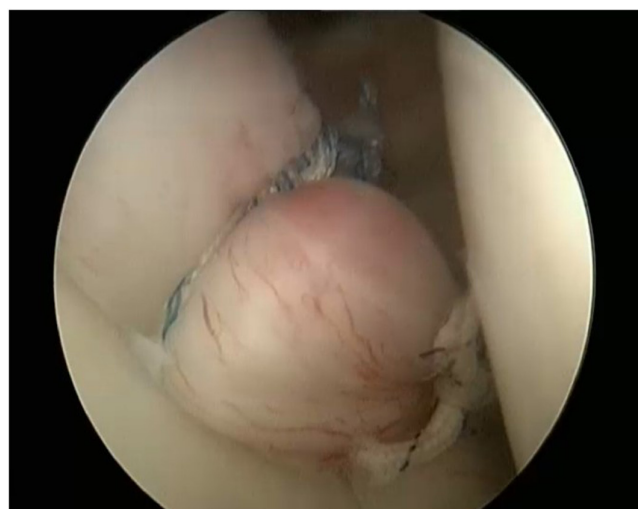

Figure 6
Arthroscopic view of capsule following plication. Positive drive-through sign is now negative after plication.

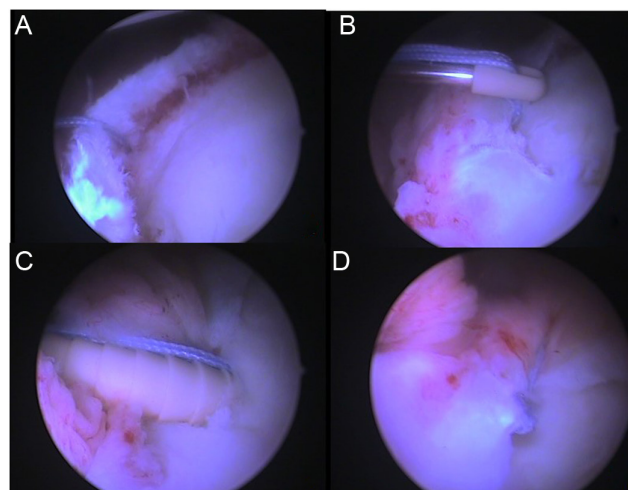


Figure 7
(A) A free suture limb is passed through deficient and loose posterior capsulolabral tissue. (B,C) Loading the suture to knotless anchor and insertion of the anchor to posterior glenoid. (D) Arthroscopic view of posterior joint after capsular plication.

The course of axillary nerve is in close proximity to inferior glenohumeral pouch and injury to this nerve has been reported both in arthroscopic and open procedures (11). Open approach allows direct visualization and protection of axillary nerve. However, the nerve is typically not visualized in arthroscopic procedures. Therefore, thorough knowledge of zones at risk is necessary to avoid axillary nerve injury. The branch to the teres minor is the closest part of the axillary nerve to inferior glenoid and the nerve is typically injured in this portion (49). This branch is a mean 12.4 mm from inferior glenoid in the 6 o'clock position and before emerging from quadrangular space, it passes a mean of 2.5 mm from inferior capsule. However, proximity of this branch varies from patient and position (49). In a cadaveric study, it was reported that external rotation, abduction and slight traction provided largest margin between capsule and axillary nerve (50). In conclusion, appropriate positioning and a good understanding of the anatomical relationship are important in prevention of axillary nerve injury.

Rotator interval closure

In the original technique described by Neer and Foster (1), the closure of subscapularis recess was defined as a routine part of inferior capsular shift procedure. Rotator interval closure continued to be applied by many surgeons; however, there are still conflicting findings in the literature about the biomechanical and clinical results of this procedure and the debate continues (13, 51, 52). The study conducted by Harryman *et al.* (53) is at the forefront of this debate. In this study, the authors reported that open medial-lateral coracohumeral ligament imbrication

Table 3 Comparison of open inferior capsular shift and arthroscopic capsular plication techniques in the treatment of multidirectional instability of shoulder.

Open inferior capsular shift	Arthroscopic capsular plication
Traditionally regarded as ‘gold standard’ procedure May be advantageous in patients with bone loss or in revision surgery	Allows direct visualization and evaluation of intra-articular structures Allows possibility to intervene co-existing intra-articular lesions in the same procedure.
No difference in terms of complication rates compared to arthroscopic techniques Allows visualization and protection of axillary nerve	Subscapularis split or tenotomy is not necessary Fewer post-operative loss of motion compared to open procedures

resulted in a significant decrease in posterior and inferior translation of the humeral head. However, traditional superior-inferior arthroscopic rotator interval closure techniques have failed to replicate these results (47, 54). In another study comparing medial-lateral and superior-inferior interval closure techniques, it has been reported that medial-lateral interval closure is superior in restoring shoulder range of motion and providing stability (48). Current findings suggest that benefits of rotator interval closure arise from superior glenohumeral ligament (SGHL). Therefore, closure of the interval should be performed in a manner to repair SGHL to its native insertion site (34).

Good clinical reports have been reported following MDI surgery, with or without rotator interval closure (44, 55). Therefore, it is difficult to recommend routine application of this procedure with the available data. It may be preferred in cases where the desired decrease in laxity cannot be achieved despite appropriate capsular plication. However, rotator interval closure can lead to limitation in external rotation and the decision should be made individually for each patient. Closing the rotator interval with the shoulder in 30° of external rotation can minimize post-operative external rotation limitation (56).

Thermal capsulorrhaphy

The advances in arthroscopy at the end of late 1980s led to the development of different arthroscopic techniques in the treatment of MDI. ‘Thermal capsulorrhaphy’ was introduced as an alternative to open inferior capsular shift in the following years, allowing the ‘shrinkage’ of the patulous capsule with the aid of an arthroscopic heat-generating probe. Thermal capsulorrhaphy was an intriguing alternative due to its immediate visualization of capsular shrinkage, quick and easy application (11, 57). However, this technique is not recommended in current practice due to risk of chondrolysis, thermal nerve injury and high failure rates (58, 59). Previous studies have reported high failure rates of up to 60% with this technique (59).

Postoperative rehabilitation

The post-operative rehabilitation approach applied after MDI surgery is similar between open and closed

techniques. The main factor that determines the approach to be applied is the severity and direction of the primary instability and the robustness of the repair. Therefore, the rehabilitation program should be planned individually for each patient.

Patients are usually immobilized in sling for 4–6 weeks with abduction pillow. Immobilization is performed at approximately 30° of abduction and neutral rotation. However, it has been reported that immobilization applied in external rotation up to 10–20° may be superior in terms of shoulder range of motion and functional outcomes (60). If there is concern about stiffness, immobilization can be terminated earlier, while prolonged immobilization can be performed if laxity is prominent (11). In the early post-operative period; elbow, wrist and hand motions should be initiated immediately in order to prevent the development of stiffness in these joints.

Following the immobilization period, gentle passive and active joint range of motion exercises and isometric strengthening exercises should be initiated in order to restore joint range of motion and to avoid the atrophy of the muscle structures around the shoulder. Starting from the 6th week, active mobilization is gradually increased and full range of motion should be achieved until 10–12th weeks. Following this period, glenohumeral joint stability should be supported with rotator cuff and periscapular muscle strengthening exercises and proprioceptive exercises aiming dynamic shoulder stabilizers. Stretching exercises should be avoided during rehabilitation as they may cause instability (61). If full muscle strength and range of motion are achieved, return to full activity and sports can be allowed in the post-operative sixth month.

Management of failed MDI surgery

Main indicator of failure in surgical treatment of MDI is persistence of glenohumeral instability. However, patients may also present with pain and stiffness following earlier surgeries such as capsular shift, arthroscopic plication and/or rotator interval closure and thermal capsulorrhaphy. Reasons behind these failures are mostly related to insufficient pre-operative clinical evaluation and misdiagnosis. When a patient presents after a failed surgery for MDI, history and examination should be closely scrutinized. Imagings of the affected shoulder may show possible intra-articular

pathologies which may have caused post-operative pain such as painful hardware, chondral lesions, osteoarthritis, chondrolysis, concomitant rotator cuff and/or biceps tendon pathology. Post-operative stiffness might be related to prolonged immobilization, excessive post-operative bleeding in open procedures or aggressive capsular volume reduction due to imperfect surgical technique (62). Inadequate post-operative rehabilitation and post-operative scapular dyskinesia can also be other reasons for poor outcomes following MDI surgery. A detailed physical examination is essential for the detection of persistent scapular dyskinesia which can be treated with extensive rehabilitation before considering revision surgery.

Once recognized, a variety of surgical treatment options are available for the treatment of failed MDI surgery depending on the reason behind the failure. However, careful patient selection, adherence to techniques and detailed patient counseling are strongly advised in these cases since most of these patients have already been misdiagnosed in previous interventions and results of revision surgeries for failed MDI are unpredictable. A previous report by Zabinski *et al.* showed that good results could be achieved in only 39% of the patients following a revision surgery (63).

Conclusion

MDI is a condition that can be challenging for physicians, especially at the diagnosis stage. After proper evaluation and diagnosis, it is possible to achieve satisfactory results with rehabilitation in most of the patients. Surgical treatment is indicated for patients whose symptoms persist despite appropriate rehabilitation. The success of surgical treatment depends on a thorough understanding of the biomechanics of shoulder joint and the pathoanatomy of glenohumeral joint instability. The surgical decision and the choice of the technique to be performed should be made individually for each patient. With current techniques such as open inferior capsular shift or arthroscopic capsular plication, good outcomes can be achieved with correct patient selection and appropriate technique.

ICMJE Conflict of Interest Statement

The authors declare no conflicts of interest

Funding

There are no funders to report for this submission.

References

1. Neer2nd CS & Foster CR. Inferior capsular shift for involuntary inferior and multidirectional instability of the shoulder. A preliminary report. *Journal of Bone and Joint Surgery* 1980 **62** 897–908. (<https://doi.org/10.2106/00004623-198062060-00004>)
2. Altchek DW, Warren RF, Skyhar MJ & Ortiz G. T-plasty modification of the Bankart procedure for multidirectional instability of the anterior and inferior types. *Journal of Bone and Joint Surgery. American Volume* 1991 **73** 105–112. (<https://doi.org/10.2106/00004623-199173010-00013>)
3. Neer 2nd CS. Involuntary inferior and multidirectional instability of the shoulder: etiology, recognition, and treatment. *Instructional Course Lectures* 1985 **34** 232–238.
4. Pollock RG, Owens JM, Flatow EL & Bigliani LU. Operative results of the inferior capsular shift procedure for multidirectional instability of the shoulder. *Bone and Joint Surgery* 2000 **82-A** 919–928. (<https://doi.org/10.2106/00004623-200007000-00003>)
5. Matsen FI, Thomas S, Rockwood Jr CA & Wirth M. Glenohumeral instability. In *The Shoulder* **1**, pp. 611–754. CA Rockwood Jr & FI Matsen, Eds.: Philadelphia 2005.
6. Saccomanno MF, Fodale M, Capasso L, Cazzato G & Milano G. Generalized joint laxity and multidirectional instability of the shoulder. *Joints* 2013 **1** 171–179. (<https://doi.org/10.11138/jts/2013.1.4.171>)
7. Navlet MG & Asenjo-Gismero CV. Multidirectional instability: natural history and evaluation. *Open Orthopaedics Journal* 2017 **11** 861–874. (<https://doi.org/10.2174/1874325001711010861>)
8. Gerber C & Nyffeler RW. Classification of glenohumeral joint instability. *Clinical Orthopaedics and Related Research* 2002 **400** 65–76. (<https://doi.org/10.1097/00003086-200207000-00009>)
9. Lippitt S & Matsen F. Mechanisms of glenohumeral joint stability. *Clinical Orthopaedics and Related Research* 1993 **291** 20–28. (<https://doi.org/10.1097/00003086-199306000-00004>)
10. Jaggi A, Noorani A, Malone A, Cowan J, Lambert S & Bayley I. Muscle activation patterns in patients with recurrent shoulder instability. *International Journal of Shoulder Surgery* 2012 **6** 101–107. (<https://doi.org/10.4103/0973-6042.106221>)
11. Gaskill TR, Taylor DC & Millett PJ. Management of multidirectional instability of the shoulder. *Journal of the American Academy of Orthopaedic Surgery* 2011 **19** 758–767. (<https://doi.org/10.5435/00124635-201112000-00006>)
12. von Eisenhart-Rothe R, Mayr HO, Hinterwimmer S & Graichen H. Simultaneous 3D assessment of glenohumeral shape, humeral head centering, and scapular positioning in atraumatic shoulder instability: a magnetic resonance–based in vivo analysis. *American Journal of Sports Medicine* 2010 **38** 375–382. (<https://doi.org/10.1177/0363546509347105>)
13. Lee HJ, Kim NR, Moon SG, Ko SM & Park JY. Multidirectional instability of the shoulder: rotator interval dimension and capsular laxity evaluation using MR arthrography. *Skeletal Radiology* 2013 **42** 231–238. (<https://doi.org/10.1007/s00256-012-1441-2>)
14. Uthoff HK & Piscopo M. Anterior capsular redundancy of the shoulder: congenital or traumatic? An embryological study. *Journal of Bone and Joint Surgery. British Volume* 1985 **67** 363–366. (<https://doi.org/10.1302/0301-620X.67B3.3997941>)
15. Burkhead Jr WZ & Rockwood Jr CA. Treatment of instability of the shoulder with an exercise program. *Journal of Bone and Joint Surgery. American Volume* 1992 **74** 890–896. (<https://doi.org/10.2106/00004623-199274060-00010>)
16. Guerrero P, Busconi B, Deangelis N & Powers G. Congenital instability of the shoulder joint: assessment and treatment options. *Journal of Orthopaedic and Sports Physical Therapy* 2009 **39** 124–134. (<https://doi.org/10.2519/jospt.2009.2860>)
17. Mallon WJ & Speer KP. Multidirectional instability: current concepts. *Journal of Shoulder and Elbow Surgery* 1995 **4** 54–64. ([https://doi.org/10.1016/s1058-2746\(10\)80009-6](https://doi.org/10.1016/s1058-2746(10)80009-6))

- 18. Bateman M, Smith BE, Osborne SE & Wilkes SR.** Physiotherapy treatment for atraumatic recurrent shoulder instability: early results of a specific exercise protocol using pathology-specific outcome measures. *Shoulder and Elbow* 2015 **7** 282–288. (<https://doi.org/10.1177/1758573215592266>)
- 19. Misamore GW, Sallay PI & Didelot W.** A longitudinal study of patients with multidirectional instability of the shoulder with seven- to ten-year follow-up. *Journal of Shoulder and Elbow Surgery* 2005 **14** 466–470. (<https://doi.org/10.1016/j.jse.2004.11.006>)
- 20. Nyiri P, Illyés A, Kiss R & Kiss J.** Intermediate biomechanical analysis of the effect of physiotherapy only compared with capsular shift and physiotherapy in multidirectional shoulder instability. *Journal of Shoulder and Elbow Surgery* 2010 **19** 802–813. (<https://doi.org/10.1016/j.jse.2010.05.008>)
- 21. Barden JM, Balyk R, Raso VJ, Moreau M & Bagnall K.** Atypical shoulder muscle activation in multidirectional instability. *Clinical Neurophysiology* 2005 **116** 1846–1857. (<https://doi.org/10.1016/j.clinph.2005.04.019>)
- 22. Illyés A, Kiss J & Kiss RM.** Electromyographic analysis during pull, forward punch, elevation and overhead throw after conservative treatment or capsular shift at patient with multidirectional shoulder joint instability. *Journal of Electromyography and Kinesiology* 2009 **19** e438–e447. (<https://doi.org/10.1016/j.jelekin.2008.09.008>)
- 23. Schenk TJ & Brems JJ.** Multidirectional instability of the shoulder: pathophysiology, diagnosis, and management. *Journal of the American Academy of Orthopaedic Surgeons* 1998 **6** 65–72. (<https://doi.org/10.5435/00124635-199801000-00007>)
- 24. Lebe M, Burns SA, Falworth M, Higgs DS, Rudge WB & Majed A.** Atraumatic shoulder instability: patient characteristics, comorbidities, and disability. *JSES International* 2021 **5** 955–959. (<https://doi.org/10.1016/j.jseint.2021.08.001>)
- 25. Jacobson ME, Rigenbach M, Wooldridge AN & Bishop JY.** Open capsular shift and arthroscopic capsular plication for treatment of multidirectional instability. *Arthroscopy* 2012 **28** 1010–1017. (<https://doi.org/10.1016/j.arthro.2011.12.006>)
- 26. Longo UG, Rizzello G, Loppini M, Locher J, Buchmann S, Maffulli N & Denaro V.** Multidirectional instability of the shoulder: a systematic review. *Arthroscopy* 2015 **31** 2431–2443. (<https://doi.org/10.1016/j.arthro.2015.06.006>)
- 27. Chen D, Goldberg J, Herald J, Critchley I & Barmare A.** Effects of surgical management on multidirectional instability of the shoulder: a meta-analysis. *Knee Surgery, Sports Traumatology, Arthroscopy* 2016 **24** 630–639. (<https://doi.org/10.1007/s00167-015-3901-4>)
- 28. Scheibel M & Habermeyer P.** Subscapularis dysfunction following anterior surgical approaches to the shoulder. *Journal of Shoulder and Elbow Surgery* 2008 **17** 671–683. (<https://doi.org/10.1016/j.jse.2007.11.005>)
- 29. Jobe FW, Giangarra CE, Kvitne RS & Glousman RE.** Anterior capsulolabral reconstruction of the shoulder in athletes in overhand sports. *American Journal of Sports Medicine* 1991 **19** 428–434. (<https://doi.org/10.1177/036354659101900502>)
- 30. Cordasco FA.** Understanding multidirectional instability of the shoulder. *Journal of Athletic Training* 2000 **35** 278–285.
- 31. Merolla G, Ceriello S, Chillemi C, Paladini P, De Santis E & Porcellini G.** Multidirectional instability of the shoulder: biomechanics, clinical presentation, and treatment strategies. *European Journal of Orthopaedic Surgery and Traumatology: Orthopedie Traumatologie* 2015 **25** 975–985. (<https://doi.org/10.1007/s00590-015-1606-5>)
- 32. Miller MD, Larsen KM, Luke T, Leis HT & Plancher KD.** Anterior capsular shift volume reduction: an in vitro comparison of 3 techniques. *Journal of Shoulder and Elbow Surgery* 2003 **12** 350–354. ([https://doi.org/10.1016/s1058-2746\(02\)86805-7](https://doi.org/10.1016/s1058-2746(02)86805-7))
- 33. Best MJ & Tanaka MJ.** Multidirectional instability of the shoulder: treatment options and considerations. *Sports Medicine and Arthroscopy Review* 2018 **26** 113–119. (<https://doi.org/10.1097/JSA.000000000000199>)
- 34. Ruiz Ibán MA, Díaz Heredia J, García Navlet M, Serrano F & Santos Oliete M.** Multidirectional shoulder instability: treatment. *Open Orthopaedics Journal* 2017 **11** 812–825. (<https://doi.org/10.2174/1874325001711010812>)
- 35. Kim SH, Noh KC, Park JS, Ryu BD & Oh I.** Loss of chondrolabral containment of the glenohumeral joint in atraumatic posteroinferior multidirectional instability. *Journal of Bone and Joint Surgery. American Volume* 2005 **87** 92–98. (<https://doi.org/10.2106/JBJS.C.01448>)
- 36. Provencher MT, Verma N, Obopilwe E, Rincon LM, Tracy J, Romeo AA & Mazzocca A.** A biomechanical analysis of capsular plication versus anchor repair of the shoulder: can the labrum be used as a suture anchor? *Arthroscopy* 2008 **24** 210–216. (<https://doi.org/10.1016/j.arthro.2007.08.013>)
- 37. Cohen SB, Wiley W, Goradia VK, Pearson S & Miller MD.** Anterior capsulorrhaphy: an in vitro comparison of volume reduction—arthroscopic plication versus open capsular shift. *Arthroscopy* 2005 **21** 659–664. (<https://doi.org/10.1016/j.arthro.2005.02.014>)
- 38. Karas SG, Creighton RA & DeMorat GJ.** Glenohumeral volume reduction in arthroscopic shoulder reconstruction: a cadaveric analysis of suture plication and thermal capsulorrhaphy. *Arthroscopy* 2004 **20** 179–184. (<https://doi.org/10.1016/j.arthro.2003.11.004>)
- 39. Flanigan DC, Forsythe T, Orwin J & Kaplan L.** Volume analysis of arthroscopic capsular shift. *Arthroscopy* 2006 **22** 528–533. (<https://doi.org/10.1016/j.arthro.2006.01.010>)
- 40. Sekiya JK, Willobee JA, Miller MD, Hickman AJ & Willobee A.** Arthroscopic multi-pleated capsular plication compared with open inferior capsular shift for reduction of shoulder volume in a cadaveric model. *Arthroscopy* 2007 **23** 1145–1151. (<https://doi.org/10.1016/j.arthro.2007.05.019>)
- 41. Lubiawski P, Długosz J, Ślęzak M, Ogrodowicz P, Stefaniak J, Walecka J & Romanowski L.** Effect of arthroscopic techniques on joint volume in shoulder instability: Bankart repair versus capsular shift. *International Orthopaedics* 2017 **41** 149–155. (<https://doi.org/10.1007/s00264-016-3275-3>)
- 42. Metcalf MH, Pon JD, Harryman II DT, Loutzenheiser T & Sidles JA.** Capsulolabral augmentation increases glenohumeral stability in the cadaver shoulder. *Journal of Shoulder and Elbow Surgery* 2001 **10** 532–538. (<https://doi.org/10.1067/mse.2001.118411>)
- 43. Kim SH, Kim HK, Sun JI, Park JS & Oh I.** Arthroscopic capsulolabroplasty for posteroinferior multidirectional instability of the shoulder. *American Journal of Sports Medicine* 2004 **32** 594–607. (<https://doi.org/10.1177/0363546503262170>)
- 44. Gartsman GM, Roddey TS & Hammerman SM.** Arthroscopic treatment of multidirectional glenohumeral instability: 2- to 5-year follow-up. *Arthroscopy* 2001 **17** 236–243. (<https://doi.org/10.1053/jars.2001.21529>)
- 45. Baker CL, Mascarenhas R, Kline AJ, Chhabra A, Pombo MW & Bradley JP.** Arthroscopic treatment of multidirectional shoulder instability in athletes: a retrospective analysis of 2- to 5-year clinical outcomes. *American Journal of Sports Medicine* 2009 **37** 1712–1720. (<https://doi.org/10.1177/0363546509335464>)
- 46. Yeargan III SA, Briggs KK, Horan MP, Black AK & Hawkins RJ.** Determinants of patient satisfaction following surgery for multidirectional instability. *Orthopedics* 2008 **31** 647. (<https://doi.org/10.3928/01477447-20110505-20>)

- 47. Provencher MT, Mologne TS, Hongo M, Zhao K, Tasto JP & An KN.** Arthroscopic versus open rotator interval closure: biomechanical evaluation of stability and motion. *Arthroscopy* 2007 **23** 583–592. (<https://doi.org/10.1016/j.arthro.2007.01.010>)
- 48. Farber AJ, ElAttrache NS, Tibone JE, McGarry MH & Lee TQ.** Biomechanical analysis comparing a traditional superior-inferior arthroscopic rotator interval closure with a novel medial-lateral technique in a cadaveric multidirectional instability model. *American Journal of Sports Medicine* 2009 **37** 1178–1185. (<https://doi.org/10.1177/0363546508330142>)
- 49. Price MR, Tillett ED, Acland RD & Nettleton GS.** Determining the relationship of the axillary nerve to the shoulder joint capsule from an arthroscopic perspective. *Journal of Bone and Joint Surgery. American Volume* 2004 **86** 2135–2142. (<https://doi.org/10.2106/00004623-200410000-00003>)
- 50. Uno A, Bain GI & Mehta JA.** Arthroscopic relationship of the axillary nerve to the shoulder joint capsule: an anatomic study. *Journal of Shoulder and Elbow Surgery* 1999 **8** 226–230. ([https://doi.org/10.1016/s1058-2746\(99\)90133-7](https://doi.org/10.1016/s1058-2746(99)90133-7))
- 51. Provencher MT, Dewing CB, Bell SJ, McCormick F, Solomon DJ, Rooney TB & Stanley M.** An analysis of the rotator interval in patients with anterior, posterior, and multidirectional shoulder instability. *Arthroscopy* 2008 **24** 921–929. (<https://doi.org/10.1016/j.arthro.2008.03.005>)
- 52. Schaeffeler C, Waldt S, Bauer JS, Kirchhoff C, Haller B, Schröder M, Rummeny EJ, Imhoff AB & Woertler K.** MR arthrography including abduction and external rotation images in the assessment of atraumatic multidirectional instability of the shoulder. *European Radiology* 2014 **24** 1376–1385. (<https://doi.org/10.1007/s00330-014-3133-x>)
- 53. Harryman DT, Sidles JA, Harris SL & Matsen FA.** The role of the rotator interval capsule in passive motion and stability of the shoulder. *Journal of Bone and Joint Surgery. American Volume* 1992 **74** 53–66. (<https://doi.org/10.2106/00004623-199274010-00008>)
- 54. Mologne TS, Zhao K, Hongo M, Romeo AA, An KN & Provencher MT.** The addition of rotator interval closure after arthroscopic repair of either anterior or posterior shoulder instability: effect on glenohumeral translation and range of motion. *American Journal of Sports Medicine* 2008 **36** 1123–1131. (<https://doi.org/10.1177/0363546508314391>)
- 55. Kim SH, Ha KI, Yoo JC & Noh KC.** Kim's lesion: an incomplete and concealed avulsion of the posteroinferior labrum in posterior or multidirectional posteroinferior instability of the shoulder. *Arthroscopy* 2004 **20** 712–720. (<https://doi.org/10.1016/j.arthro.2004.06.012>)
- 56. Gartsman GM, Taverna E & Hammerman SM.** Arthroscopic rotator interval repair in glenohumeral instability: description of an operative technique. *Arthroscopy* 1999 **15** 330–332. ([https://doi.org/10.1016/s0749-8063\(99\)70045-9](https://doi.org/10.1016/s0749-8063(99)70045-9))
- 57. Savoie III FH & Field LD.** Thermal versus suture treatment of symptomatic capsular laxity. *Clinics in Sports Medicine* 2000 **19** 63–75. ([https://doi.org/10.1016/s0278-5919\(05\)70296-9](https://doi.org/10.1016/s0278-5919(05)70296-9))
- 58. D'Alessandro DF, Bradley JP, Fleischli JE & Connor PM.** Prospective evaluation of thermal capsulorrhaphy for shoulder instability: indications and results, two- to five-year follow-up. *American Journal of Sports Medicine* 2004 **32** 21–33. (<https://doi.org/10.1177/0095399703258735>)
- 59. Hawkins RJ, Krishnan SG, Karas SG, Noonan TJ & Horan MP.** Electrothermal arthroscopic shoulder capsulorrhaphy: a minimum 2-year follow-up. *American Journal of Sports Medicine* 2007 **35** 1484–1488. (<https://doi.org/10.1177/0363546507301082>)
- 60. Yin B, Levy D, Meadows M, Moen T, Gorroochurn P, Cadet ER, Levine WN & Ahmad CS.** How does external rotation bracing influence motion and functional scores after arthroscopic shoulder stabilization? *Clinical Orthopaedics and Related Research* 2014 **472** 2389–2396. (<https://doi.org/10.1007/s11999-013-3343-6>)
- 61. Wilk KE & Macrina LC.** Nonoperative and postoperative rehabilitation for glenohumeral instability. *Clinics in Sports Medicine* 2013 **32** 865–914. (<https://doi.org/10.1016/j.csm.2013.07.017>)
- 62. Forsythe B, Ghodadra N, Romeo AA & Provencher MT.** Management of the failed posterior/multidirectional instability patient. *Sports Medicine and Arthroscopy Review* 2010 **18** 149–161. (<https://doi.org/10.1097/JSA.0b013e3181ec4397>)
- 63. Zabinski SJ, Callaway GH, Cohen S & Warren RF.** Revision shoulder stabilization: 2- to 10-year results. *Journal of Shoulder and Elbow Surgery* 1999 **8** 58–65. ([https://doi.org/10.1016/s1058-2746\(99\)90057-5](https://doi.org/10.1016/s1058-2746(99)90057-5))