


Contents lists available at [ScienceDirect](https://www.sciencedirect.com)

## International Journal of Surgery Case Reports

journal homepage: [www.casereports.com](http://www.casereports.com)

## Unicompartmental knee arthroplasty combined with high tibial osteotomy in anteromedial osteoarthritis: A case report

Vahdet Ucan\*, Anil Pulatkan, Ibrahim Tuncay

Department of Orthopedics and Traumatology, Bezmialem Vakif University School of Medicine, Vatan Cd, Fatih, 34093, Istanbul, Turkey

## ARTICLE INFO

## Article history:

Received 13 February 2021  
 Received in revised form 6 March 2021  
 Accepted 9 March 2021  
 Available online 11 March 2021

## Keywords:

Anteromedial osteoarthritis  
 Varus deformity  
 Unicompartmental knee arthroplasty  
 High tibial osteotomy  
 Case report

## ABSTRACT

**INTRODUCTION AND IMPORTANCE:** Anteromedial osteoarthritis (AMOA) is a common knee pathology. However, the best treatment of AMOA remains unclear. Unicompartmental knee arthroplasty (UKA) and high tibial osteotomy (HTO) are surgical options for AMOA patients who do not benefit from conservative treatment. We aimed to show an unusual treatment option where UKA and HTO are performed simultaneously.

**CASE PRESENTATION:** We present a 52-year-old man with AMOA secondary to spontaneous osteonecrosis of the knee (SONK) and metaphyseal tibial varus malalignment, who was successfully treated with a combined UKA and HTO. His functional scores were excellent at the 5-year follow-up.

**CLINICAL DISCUSSION:** Advanced SONK that causes AMOA can be treated with osteochondral autograft transplantation (OAT), HTO, UKA, or total knee arthroplasty (TKA). Although good results have been reported selecting appropriate patients for all of these methods, the best treatment method remains unclear.

**CONCLUSION:** Although HTO and UKA are alternative treatments for AMOA, successful results can be obtained using both in individual cases.

© 2021 The Authors. Published by Elsevier Ltd on behalf of IJS Publishing Group Ltd. This is an open access article under the CC BY-NC-ND license (<http://creativecommons.org/licenses/by-nc-nd/4.0/>).

## 1. Introduction

In the 1970s, unicompartmental knee arthroplasty (UKA) was introduced as an alternative to high tibial osteotomy (HTO) for patients in whom conservative treatment failed in isolated anteromedial osteoarthritis (AMOA) [1]. UKA has become popular due to its advantages, such as preserving the non-degenerate part of the joint, maintaining bone stock and native knee kinematics, and allowing immediate postoperative weight-bearing.

Currently, the accepted indications for UKA are AMOA or spontaneous osteonecrosis of the knee (SONK) accompanied by bone-on-bone deformity, functionally normal anterior cruciate (ACL) and medial collateral ligaments, intact full-thickness lateral cartilage, and a patellofemoral compartment with no lateral grooving or bone loss [2].

A medial opening wedge HTO is realignment surgery that transfers the load from the medial compartment of the knee with arthritis to the less affected lateral compartment. The symptoms regress, the progression of AMOA is inhibited, and the damaged cartilage tissue can heal [3,4]. Generally, HTO is preferred to UKA for the treatment of active, relatively young patients with varus aligned AMOA [5,6].

It is essential to choose the appropriate method for patients. Here, we present the long-term results of a patient who was treated by UKA combined with HTO for AMOA secondary to SONK.

## 2. Presentation of case

A 52-year-old man presented to our orthopedics outpatient clinic with pain, difficulty walking, and deformity in the left knee. He was admitted to the hospital because he had not benefited from conservative treatment with nonsteroidal anti-inflammatory drugs, 10 physiotherapy sessions, and two platelet-rich plasma injections.

Physical examination revealed bilateral metaphyseal tibial varus malalignment, tenderness on the medial femoral condyle without lateral and patellofemoral compartment tenderness, 10° flexion contracture, and 10–100° painful range of motion (ROM) (Fig. 1). No knee instability was detected on physical examination, and both the ACL and collateral ligament were intact.

Multiple moderately sized osteophytes, definite narrowing of the medial joint space without lateral involvement, a subchondral cyst and radiolucent focus in the subchondral bone, and a peripheral zone of osteosclerosis in distal femur were detected in X-rays. The osteoarthritis was Kellgren–Lawrence grade 3. Orthoroentgenography showed that the lower extremity mechanical axis passed 68 mm medial to the midline of the knee (mechanical lateral distal femoral angle, 87°; mechanical medial

\* Corresponding author.

E-mail address: [vahdetucan@hotmail.com](mailto:vahdetucan@hotmail.com) (V. Ucan).<https://doi.org/10.1016/j.ijscr.2021.105746>2210-2612/© 2021 The Authors. Published by Elsevier Ltd on behalf of IJS Publishing Group Ltd. This is an open access article under the CC BY-NC-ND license (<http://creativecommons.org/licenses/by-nc-nd/4.0/>).

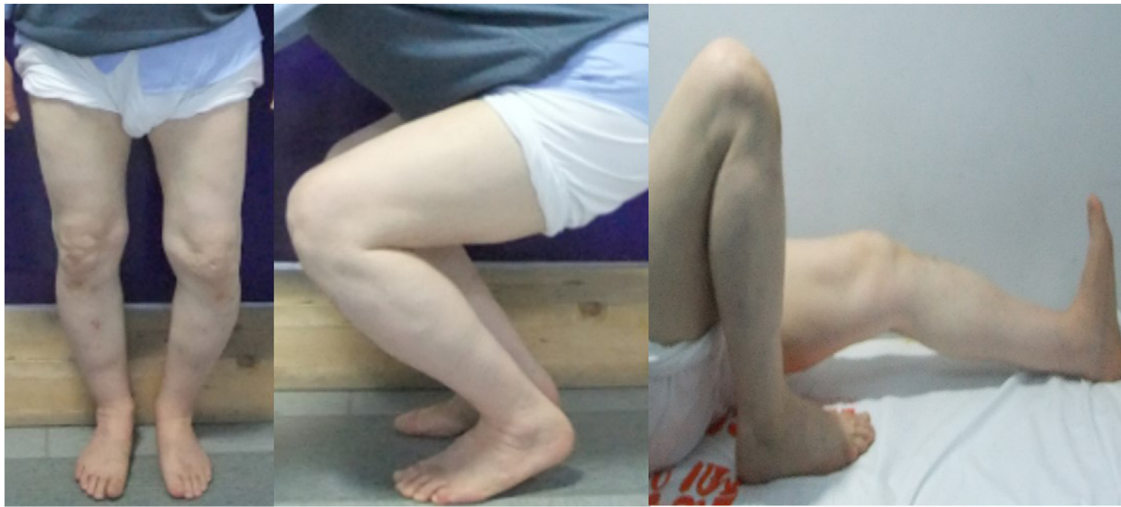

Fig. 1. Preoperative range of motion and varus alignment of the knee.

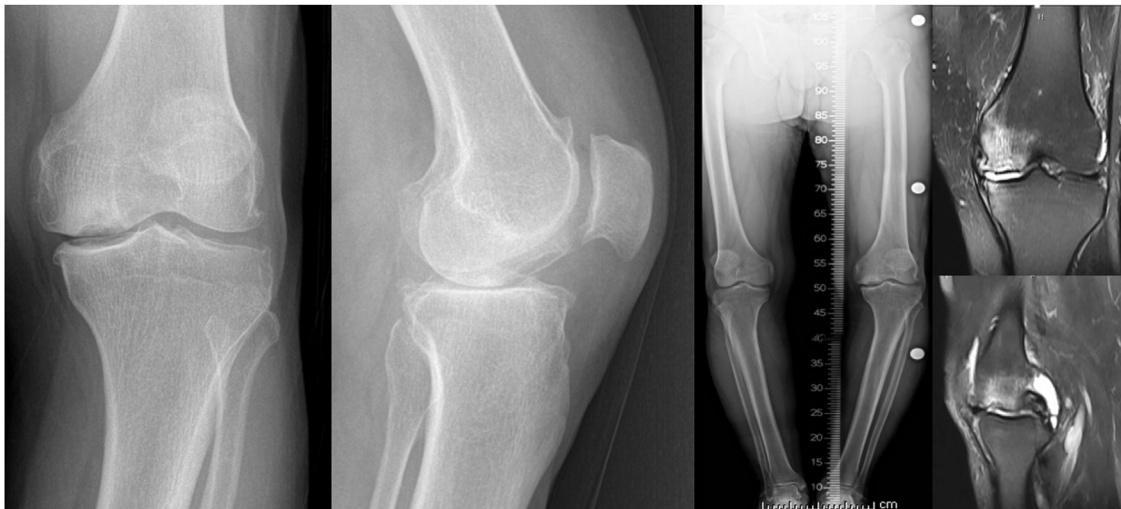


Fig. 2. Osteonecrosis in the medial femoral condyle is prominent in the preoperative radiographs and MRI of the knee.

proximal tibial angle,  $75^\circ$ ). Magnetic resonance imaging (MRI) showed an osteonecrotic crescent-shaped lesion, flattening of the medial femoral condyle, and subchondral bone marrow edema in both the proximal tibia and distal femur, corresponding to Koshino grade 4 SONK (Fig. 2). The patient has no drug history, family history including relevant genetic information, and psychosocial history.

A research physiotherapist determined the Oxford Knee Score (OKS) and International Knee Documentation Committee (IKDC) score preoperatively and at the 5-year follow-up.

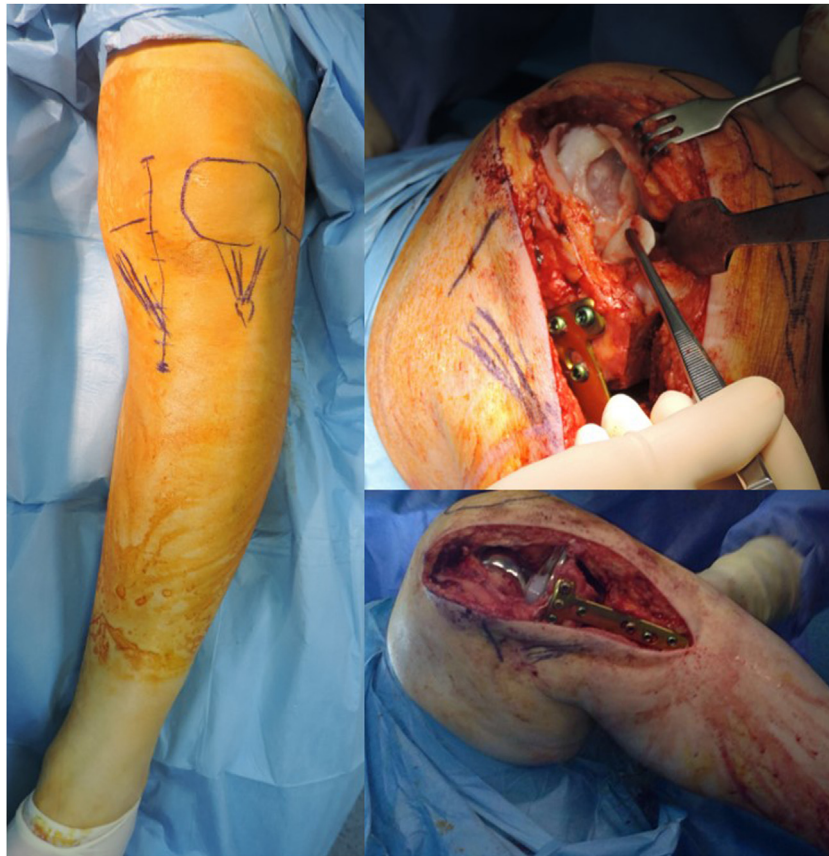The surgery was performed by a high-volume knee surgeon (I.T.) on a standard operating table with a tourniquet in the supine position. The knee was prepped and draped in the standard fashion. A biplanar ascending proximal tibia osteotomy was performed through a longitudinal incision starting from 2 cm medial to the tibial tuberosity. After the deformity was corrected so that the mechanical axis passes through the middle of the medial compartment, osteosynthesis was achieved with a TomoFix® implant (DePuy Synthes, Oberdorf, Switzerland) without using bone grafts. After fluoroscopic examinations, the incision was extended proximally to perform the arthrotomy. The ACL and lateral and patellofemoral compartments were intact. A  $3 \times 2$  cm delaminating cartilage lesion was seen on the medial femoral condyle

(Fig. 3). An uncemented medial mobile-bearing UKA (Oxford UKA, Zimmer-Biomet, Warsaw, IN, USA) was implanted after the tibial and femoral cuts. Finally, the polyethylene insert was placed and the incision was closed after controlling bleeding and ROM.

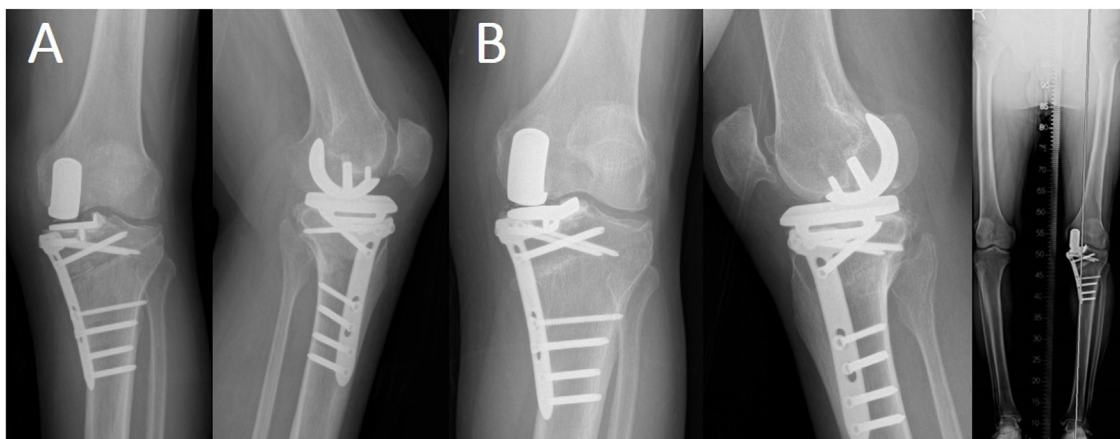
The postoperative rehabilitation included immediate ROM and quadriceps strengthening exercises with the help of a continuous passive motion (CPM) device for the first 2 days. The patient was discharged on the second postoperative day with a home rehabilitation program. The patient was allowed non-weight-bearing walking with crutches after 6 weeks and weight-bearing with crutches after 6 weeks. Knee bending was increased from  $30^\circ$  on the first day to  $90^\circ$  within 2 weeks, and beyond thereafter. The patient was reassessed at 2 weeks, 1, 3, 6, and 12 months, and then annually thereafter with X-rays (Fig. 4).

Five years postoperatively, he had approximately full ROM and was able to kneel without pain (Fig. 5). The OKS and IKDC scores had improved from 18 and 19.2 preoperatively to 38 and 52.9, respectively, postoperatively.

This article has been reported in line with the SCARE criteria, and written informed consent was obtained from the patient for the use and publication of data for academic purposes [7].



**Fig. 3.** Knee varus was obvious during the surgical planning. Delaminated cartilage was seen after arthroscopy with a medial parapatellar incision. Unicompartmental knee arthroplasty was performed after a high tibial osteotomy.



**Fig. 4.** Radiographs A) 1 and B) 5 years postoperatively, with orthoroentgenography.

### 3. Discussion

This case presents the successful functional outcome of a middle-age man with AMOA secondary to metaphyseal tibial malalignment and SONK, who was treated with UKA combined with HTO. Advanced SONK that causes AMOA can be treated with osteochondral autograft transplantation (OAT), HTO, UKA, or total knee arthroplasty (TKA) [8]. Although good results have been reported selecting appropriate patients for all of these methods, the best treatment method remains unclear.

OAT is an alternative in SONK treatment and involves the transfer of osteochondral grafts from less weight-bearing areas of

the articular surface to the cartilage defect, and is recommended for patients with lesions  $> 4 \text{ cm}^2$ . Some studies have obtained poor results in patients more than 50 years old [9,10]. Furthermore, isolated OAT is unsuitable for advanced varus knees, because the necrotic lesion may not heal spontaneously under excessive weight-bearing pressure. Although Kumagi et al. reported good functional results after OAT combined with HTO [11], we did not choose this method for our patient, who was over 50 years old and had kissing lesions. Unfortunately, there are no more reports on HTO combined with OAT.

HTO unloads the affected compartment and potentially contributes to lesion healing [12]. HTO is indicated in younger or

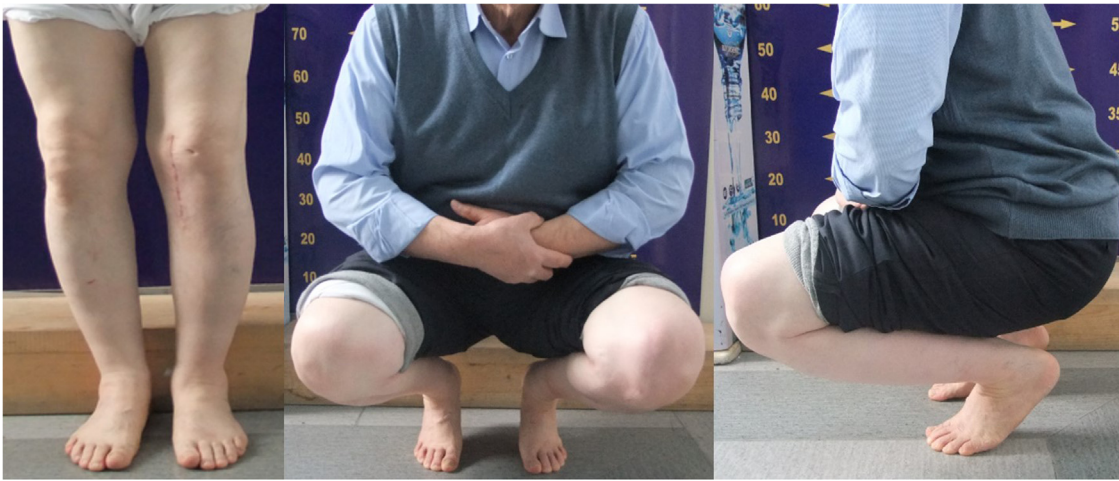


Fig. 5. Range of motion and alignment of the knee 5 years postoperatively.

active patients [13]. However, for advanced AMOA accompanied by kissing lesions, isolated HTO has poor results and is relatively contraindicated; UKA is preferred [12,14]. Thus, joint arthroplasty is the most reasonable treatment for late SONK with secondary joint collapse [15]. For our patient, UKA seemed to be more appropriate than TKA, as it does not require ACL resection or damage the cartilage in the normal compartment [16]. TKA may be the only successful alternative for patients who have extensive SONK disease affecting multiple compartments [15]. Furthermore, in societies where kneeling is common in daily life, TKA may cause difficulties in relatively young patients [17].

One of the main factors contributing to the success of UKA is that the mechanical axis passes through the prosthesis so that the prosthesis carries the load [18]. The aim of UKA is to restore knee kinematics by restoring ligament tension without correcting the axis [19]. Patients with a preoperative frontal deformity  $> 15^\circ$  may not be ideal candidates for UKA, because the postoperative axis will exceed  $8\text{--}10^\circ$ , leading to possible failure due to polyethylene wear and implant loosening [18]. However, in patients with AMOA and metaphyseal tibial varus malalignment, the load does not pass through the prosthesis after UKA implantation. Residual varus malalignment decreases prosthesis survival by causing polyethylene wear [19,20].

Recently, Jones et al. described UKA combined with revision HTO, which is similar to our technique, in four patients with failed HTO. They obtained good short-term results and concluded that their technique was a successful alternative to TKA in young patients [21]. In our case, unlike their series, the surgical intervention was not secondary to a failed surgery, but it was the primary surgical intervention for SONK and metaphyseal tibial varus malalignment, and the patient has long-term follow-up results. Comparing the surgical techniques, we started with HTO, while Jones et al. performed UKA first.

#### 4. Conclusion

This unique case had a good functional outcome for combined mobile-bearing UKA with medial opening HTO for the treatment of AMOA secondary to SONK and metaphyseal tibial varus malalignment. Studies of more cases are needed to assess the functional outcome of this unusual treatment method.

#### Declaration of Competing Interest

All authors declare that there is no conflict of interest regarding this case report.

#### Funding

All authors declare that there is no funding regarding this case report.

#### Ethical approval

The study is exempt from ethical approval in our institution.

#### Consent

Written informed consent was obtained from the patient for publication of this case report and accompanying images. A copy of the written consent is available for review by the Editor-in-Chief of this journal on request.

#### Author contribution

Vahdet Ucan MD: Data collection, writing the paper  
Anil Pulatkan MD: Data analysis and interpretation, data collection  
Ibrahim Tuncay MD: Study concept and design

#### Registration of research studies

Not applicable.

#### Guarantor

Ibrahim Tuncay, MD

#### Provenance and peer review

Not commissioned, externally peer-reviewed.

#### References

- [1] J. Insall, P. Aglietti, A five to seven-year follow-up of unicondylar arthroplasty, *J. Bone Joint Surg. Am.* 62 (8) (2010) 1329–1337.

- [2] T.W. Hamilton, J.M. Rizkalla, L. Kontochristos, et al., The interaction of caseload and usage in determining outcomes of unicompartmental knee arthroplasty: a meta-analysis, *J. Arthroplasty* 32 (10) (2017) 3228–3237.e2, <http://dx.doi.org/10.1016/j.arth.2017.04.063>.
- [3] W.H. Jung, R. Takeuchi, C.W. Chun, et al., Second-look arthroscopic assessment of cartilage regeneration after medial opening-wedge high tibial osteotomy, *Arthroscopy* 30 (1) (2014) 72–79, <http://dx.doi.org/10.1016/j.arthro.2013.10.008>.
- [4] S. Wakabayashi, S. Akizuki, T. Takizawa, Y. Yasukawa, A comparison of the healing potential of fibrillated cartilage versus eburnated bone in osteoarthritic knees after high tibial osteotomy: an arthroscopic study with 1-year follow-up, *Arthroscopy* 18 (3) (2002) 272–278, <http://dx.doi.org/10.1053/jars.2002.30488>.
- [5] I.J. Koh, M.S. Kim, S. Sohn, et al., Predictive factors for satisfaction after contemporary unicompartmental knee arthroplasty and high tibial osteotomy in isolated medial femorotibial osteoarthritis, *Orthop. Traumatol. Surg. Res.* 105 (1) (2019) 77–83, <http://dx.doi.org/10.1016/j.otsr.2018.11.001>.
- [6] K. Trieb, J. Grohs, B. Hanslik-Schnabel, T. Stulnig, J. Panotopoulos, A. Waniwenhaus, Age predicts outcome of high-tibial osteotomy, *Knee Surg. Sports Traumatol. Arthrosc.* 14 (2) (2006) 149–152, <http://dx.doi.org/10.1007/s00167-005-0638-5>.
- [7] R.A. Agha, T. Franchi, C. Sohrabi, G. Mathew, for the SCARE Group, The SCARE 2020 guideline: updating consensus surgical CAse REport (SCARE) guidelines, *Int. J. Surg.* 84 (2020).
- [8] J.R. Young, A.G. Shamrock, A.J. Rosenbaum, Spontaneous osteonecrosis of the knee (SONK), in: *StatPearls*, StatPearls Publishing, 2020.
- [9] T.Y. Emre, T. Ege, O. Kose, et al., Factors affecting the outcome of osteochondral autografting (mosaicplasty) in articular cartilage defects of the knee joint: retrospective analysis of 152 cases, *Arch. Orthop. Trauma Surg.* 133 (4) (2013) 531–536, <http://dx.doi.org/10.1007/s00402-013-1680-2>.
- [10] L. Hangody, P. Füles, Autologous osteochondral mosaicplasty for the treatment of full-thickness defects of weight-bearing joints: ten years of experimental and clinical experience, *J. Bone Jt. Surg.* 85-A (Suppl 2) (2003) 25–32, <http://dx.doi.org/10.2106/00004623-200300002-00004>, American volume.
- [11] K. Kumagai, Y. Akamatsu, H. Kobayashi, Y. Kusayama, T. Saito, Mosaic osteochondral autograft transplantation versus bone marrow stimulation technique as a concomitant procedure with opening-wedge high tibial osteotomy for spontaneous osteonecrosis of the medial femoral condyle, *Arthroscopy*. 34 (1) (2018) 233–240, <http://dx.doi.org/10.1016/j.arthro.2017.08.244>.
- [12] I. Ivarsson, R. Myrnerets, J. Gillquist, High tibial osteotomy for medial osteoarthritis of the knee. A 5 to 7 and 11 year follow-up, *J. Bone Joint Surg. Br.* 72 (2) (1990) 238–244.
- [13] K. Trieb, J. Grohs, B. Hanslik-Schnabel, T. Stulnig, J. Panotopoulos, A. Waniwenhaus, Age predicts outcome of high-tibial osteotomy, *Knee Surg. Sports Traumatol. Arthrosc.* 14 (2) (2006) 149–152, <http://dx.doi.org/10.1007/s00167-005-0638-5>.
- [14] D.E. Bonasia, F. Dettoni, G. Sito, et al., Medial opening wedge high tibial osteotomy for medial compartment overload/arthritis in the varus knee: prognostic factors, *Am. J. Sports Med.* 42 (3) (2014) 690–698, <http://dx.doi.org/10.1177/0363546513516577>.
- [15] A.R. Karim, J.J. Cheria, J.J. Jauregui, T. Pierce, M.A. Mont, Osteonecrosis of the knee: review, *Ann. Transl. Med.* 3 (1) (2015) 6, <http://dx.doi.org/10.3978/j.issn.2305-5839.2014.11.13>.
- [16] M.R. O'Rourke, J.J. Gardner, J.J. Callaghan, et al., The John Insall Award: unicompartmental knee replacement: a minimum twenty-one-year followup, end-result study, *Clin. Orthop. Relat. Res.* 440 (2005) 27–37, <http://dx.doi.org/10.1097/01.blo.0000185451.96987.aa>.
- [17] D. Fletcher, A.J. Moore, A.W. Blom, V. Wylde, An exploratory study of the long-term impact of difficulty kneeling after total knee replacement, *Disabil. Rehabil.* 41 (7) (2019) 820–825, <http://dx.doi.org/10.1080/09638288.2017.1410860>.
- [18] M. Vasso, C. Del Regno, A. D'Amelio, et al., Minor varus alignment provides better results than neutral alignment in medial UKA, *Knee* 22 (2) (2015) 117–121, <http://dx.doi.org/10.1016/j.knee.2014.12.004>.
- [19] M.L. Dao Trong, C. Diezi, G. Goerres, N. Helmy, Improved positioning of the tibial component in unicompartmental knee arthroplasty with patient-specific cutting blocks, *Knee Surg. Sports Traumatol. Arthrosc.* 23 (7) (2015) 1993–1998, <http://dx.doi.org/10.1007/s00167-014-2839-2>.
- [20] G.A. Valenzuela, N.A. Jacobson, D.J. Geist, R.G. Valenzuela, R.A. Teitge, Implant and limb alignment outcomes for conventional and navigated unicompartmental knee arthroplasty, *J. Arthroplasty* 28 (3) (2013) 463–468, <http://dx.doi.org/10.1016/j.arth.2012.09.001>.
- [21] G.G. Jones, S. Clarke, M. Jaere, J.P. Cobb, Failed high tibial osteotomy: a joint preserving alternative to total knee arthroplasty, *Orthop. Traumatol. Surg. Res.* 105 (1) (2019) 85–88, <http://dx.doi.org/10.1016/j.otsr.2018.11.004>.

## Open Access

This article is published Open Access at [sciencedirect.com](https://www.sciencedirect.com). It is distributed under the [IJSCR Supplemental terms and conditions](#), which permits unrestricted non commercial use, distribution, and reproduction in any medium, provided the original authors and source are credited.