



Changes in human pulp blood flow during canine retraction

Fidan Alakus Sabuncuoglu & Seyda Ersahan

To cite this article: Fidan Alakus Sabuncuoglu & Seyda Ersahan (2016) Changes in human pulp blood flow during canine retraction, Acta Odontologica Scandinavica, 74:6, 436-442, DOI: 10.3109/00016357.2016.1174295

To link to this article: <https://doi.org/10.3109/00016357.2016.1174295>



Published online: 18 May 2016.



Submit your article to this journal [↗](#)



Article views: 391



View related articles [↗](#)



View Crossmark data [↗](#)



Citing articles: 3 View citing articles [↗](#)

ORIGINAL ARTICLE

Changes in human pulp blood flow during canine retraction

Fidan Alakus Sabuncuoglu^a and Seyda Ersahan^b

^aDepartment of Orthodontics, Center for Dental Sciences, Gulhane School of Medicine, Ankara, Turkey; ^bDepartment of Endodontics, Faculty of Dentistry, Bezmialem Vakif University, Istanbul, Turkey

ABSTRACT

Aim: To evaluate the effects of maxillary canine retraction on pulpal blood flow (PBF) in humans as recorded by laser Doppler flowmetry (LDF).

Methods: Maxillary canines of 24 participants were divided into two groups ($n = 12$ each). Teeth in the study group underwent maxillary canine retraction using mini-implants as anchorage for approximately 4 months, with 100 g of force applied via coil springs. Subjects in the control group received no orthodontic treatment. LDF measurements were recorded at baseline (T0); during retraction, at 24 hours (T1), 3 days (T2), 7 days (T3) and 1 month (T4); and at the end of retraction (T5) in the study group and at similar time-points in control subjects. Data were analyzed using the Friedman, Wilcoxon signed rank and Mann–Whitney U tests, with the significance level set at 0.05.

Results: No significant changes in PBF perfusion units (PU) were observed in the control group over the course of the study. However, PBF in the study group increased significantly from T0 (3.6 ± 0.2 PU) to T1 (3.7 ± 0.2 PU, $p < 0.001$) and decreased severely from T1 to T2 (3.3 ± 0.1 , $p < 0.001$). PBF in the study group was still significantly lower at T3 (3.4 ± 0.1 PU, $p < 0.001$) in comparison to T0; however, at T4 and T5, PBF was found to have returned to pre-retraction levels.

Conclusion: The fact that PBF values returned to initial levels within one month of the initiation of retraction despite short-term, hyperaemic, regressive changes demonstrates that the changes observed in PBF during canine retraction are reversible.

ARTICLE HISTORY

Received 20 January 2016
Revised 22 March 2016
Accepted 29 March 2016
Published online 16 May 2016

KEYWORDS

Canine retraction; laser Doppler flowmetry (LDF); mini-implant; pulpal blood flow (PBF)

Introduction

The application of force to dentition in order to induce orthodontic tooth movement affects the periodontium and dental pulp in a variety of ways. Evidence suggests that orthodontic tooth movement may cause mechanical damage and provoke inflammatory reactions in periodontium [1] as well as a reduction in oxygen levels,[2] cell damage, circulatory disturbances [3,4] and inflammatory changes [5] in dental pulp. While periodontal stimulation is a precondition for orthodontic tooth movement, it is important that this stimulation has a limited effect on dental pulp; however, the lack of collateral circulation makes pulp tissue extremely sensitive, and because orthodontic forces stimulate the entire pulp vascular system, their effect tends to extend beyond simple inflammation to create circulatory disturbances within the pulp.[3] Histological studies have reported dental pulp to exhibit a range of responses to orthodontic movement, from circulatory vascular stasis to necrosis.[3,6,7]

Tooth vitality and pulp-tissue status may be assessed by a variety of techniques, the vast majority of which involve either thermal or electrical stimulation of sensory nerve fibres. However, these tests provide only a measure of pulpal neural response, not pulpal blood flow, which is the true determinant of pulp vitality.[8] Tests of pulpal sensibility conducted during orthodontic treatment are unreliable.[9–12]

Considering that several studies have demonstrated a diminished or total lack of response to electric pulp testing during orthodontic force application, direct measurements of pulpal blood flow (PBF) may be expected to provide a better assessment of pulp vitality than measurements of neural response.

PBF has been measured experimentally using invasive techniques such as radioisotope clearance [13] and H_2 gas desaturation [14] and noninvasive techniques such as laser Doppler flowmetry (LDF),[15] pulse oximetry [8] and dual wavelength spectrophotometry.[16] Invasive techniques are clearly inapplicable to clinical practice, and some noninvasive techniques, such as pulse oximetry and dual wavelength spectrophotometry, are presently unreliable.[16,17] Despite potential problems with signal contamination from gingival and other surrounding tissue,[18,19] as a well-researched and reliable non-invasive, objective and semi-quantitative technique, LDF represents the most promising alternative method of PBF measurement currently available.[20,21]

LDF has been used to monitor PBF changes produced by the application of orthodontic force in animals and humans. Intrusive and extrusive forces, which are assumed to pose more risk to pulp microcirculation than other types of tooth movement, have been widely studied;[3–5] however, little information is available as to how the application of continuous retraction forces affects pulpal vascularity. A single study assessing PBF changes during canine retraction found the

application of a light (50 g) tipping force using a removable appliance caused a transient reduction in PBF;^[22] however, due to the difficulty of accurately repositioning the LDF probe, the study was limited to 72 hours. Changes in PBF resulting from heavier retraction forces (100 g) applied via fixed appliances over a longer period (until the end of retraction) are yet to be evaluated using LDF. Therefore, the present study was conducted using LDF to evaluate blood-flow changes in pulp tissue during the retraction of human maxillary canines using mini-implants as anchorage over a period of approximately 4 months.

Materials and methods

Subjects and orthodontic procedures

After obtaining approval from the Hospital Research Ethics Committee (B.10.4.ISM.4.06.68.49/585), 24 patients (10 males and 14 females; mean age: 21.91 ± 2.89 years; age range: 19–25 years) were selected. Criteria for inclusion were: (1) an Angle Class II molar and canine relationship requiring bilateral extraction of the maxillary first premolars and retraction of the maxillary canines with maximum anchorage control; (2) clinically healthy upper canines (free of caries, restorations, defects, attrition and discoloration) and periodontal tissue (with normal gingival appearance, gingival sulcus depth of <2 mm and no symptomatic mobility); (3) radiographically healthy upper canines (with visible pulp chamber and root canals) and normal periapical tissue with no obliterated root canals, pulp stones (denticles), or diffuse calcifications; (4) no

history of trauma or previous orthodontic treatment; (5) no significant medical history or medication that might influence PBF; and (6) no history of smoking. Study participants were divided into a study group of patients treated with mini-implant-supported maxillary canine retraction ($n=12$) and a control group of subjects who received no orthodontic treatment and tooth extraction ($n=12$), but which was included to account for temporal variability that may occur with repeated blood-flow measurements. After being explained the study purpose and procedures, all patients gave their informed consent for participation.

Following first premolar extractions and subsequent leveling and alignment, a 0.016×0.022 -inch stainless-steel wire was placed in the maxillary arch (0.018 inch preadjusted appliance) in preparation for the bilateral insertion of mini-implants (AbsoAnchor; Dentos, Taegu, Korea; 1.3 mm diameter; 6 mm length), which were used as skeletal anchorage units. Mini-implants were inserted into the buccal alveolus between the maxillary second premolar and the first molar, and their positions in relation to neighboring roots were checked using standard periapical radiographs. Nickel-titanium closed-coil springs (GAC International Inc, Bohemia, NY) were used to attach the alveolar mini-implants to the canine brackets (Figure 1(a)). One week after placement, the mini-implants were loaded, and maxillary canine retraction was performed using orthodontic forces of 100 g. Force levels were checked at monthly appointments using a gram-force gauge (Correx; Ortho Care, Saltire, UK), and any mini-implants that failed were replaced immediately. Canine retraction was accomplished in approximately 4 months, at which

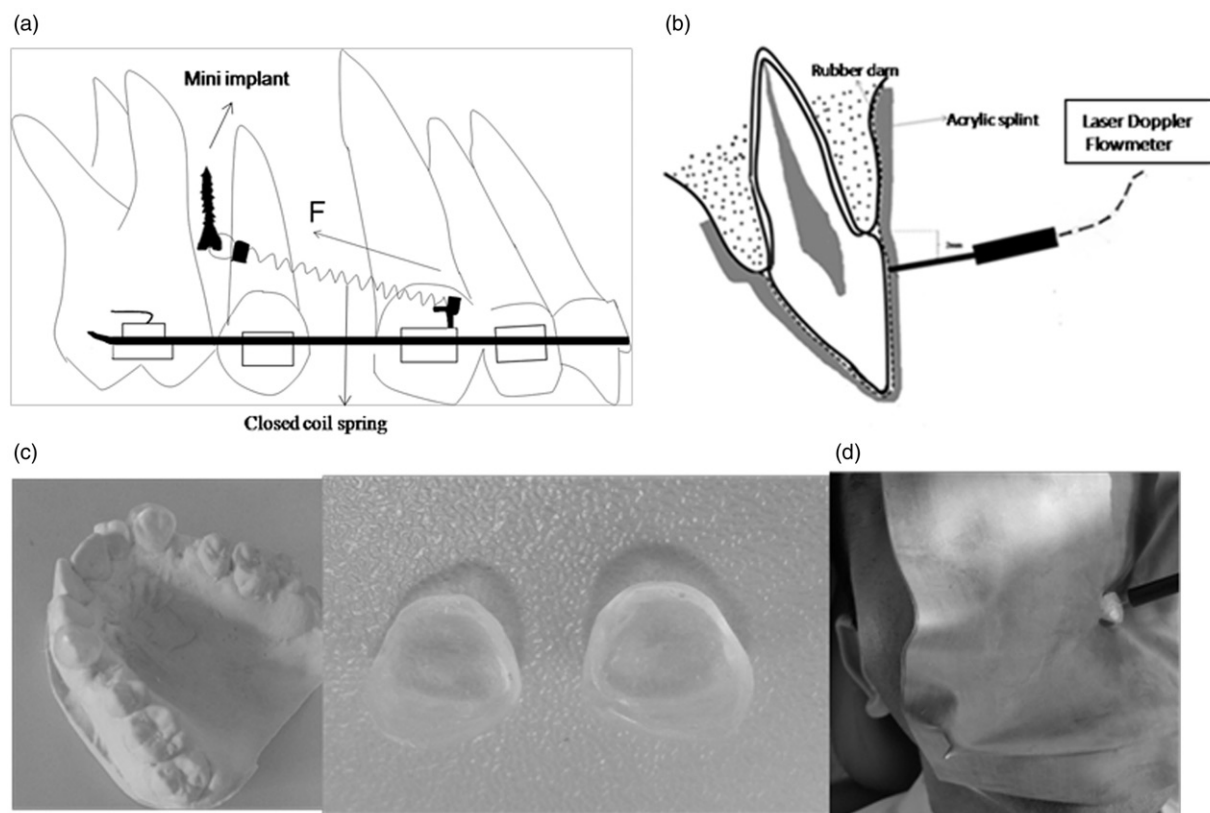


Figure 1. (a) Schematic diagram illustrating the mechanics used for canine distalization; (b) custom acrylic splint for LDF; (c) diagram of the experimental set up; (d) clinical photograph of LDF measurement.

time the mini-implants were removed. No other treatment was performed until after retraction was complete.

Laser Doppler flowmeter

PBF was measured using a Laser Doppler Flowmeter (Periflux PF 4001, Perimed, Järfälla, Sweden). The LDF output signal voltage is linearly related to red-blood-cell flow (number of cells \times average velocity), which is recorded in perfusion units (PU) to provide a relative measurement of blood flow. The LDF used in this study has a 1 mW He-Ne laser with a wavelength of 632.8 nm. A straight probe (PF 416, Perimed, Järfälla, Sweden) with a diameter of 2 mm was used to conduct a light beam of 125 μ m (fiber to-fiber distance: 500 μ m) to the measurement site within the dental pulp and to retrieve the backscattered light to the flowmeter. Prior to each measurement, the probe was calibrated for zero voltage and a motility standard of 250 PU using a plastic block (Perimed, Järfälla, Sweden).

Recording procedures

LDF measurements were recorded just prior to canine retraction (T0); at Hour 24 (T1), Day 3 (T2), Day 7 (T3) and Week 4 (T4) following the initiation of canine retraction; and at the end of retraction (T5, approximately 4 months after the initiation of retraction) and at parallel intervals for the untreated control subjects. Accuracy and reproducibility of measurements were achieved by providing each patient with 2 custom-fabricated splints formulated from self-curing acrylic resin that were used to secure the probe in the appropriate positions approximately 3 mm from the gingival margin of each tooth, with one splint covering the crown of the right canine and the other covering the crown of the left canine (Figure 1(c)). Prior to LDF measurement, the archwire and the brackets were temporarily removed, and an opaque, heavy-gauge rubber dam and both splints were positioned in the patient's mouth, and the patient was allowed to relax in the dental chair in a supine position for approximately 20 minutes (Figure 1(b)). PBF was measured in right and left canine teeth at the same session (Figure 1(d)); however, because only one probe was available, measurements were performed consecutively, with the probe remaining on one tooth for approximately 1 minute before being transferred to the contralateral tooth. For each tooth, LDF measurements were taken continuously until 2 min of stable data-values were registered on the flowmeter screen. All measurements were performed by the same operator under standardized environmental conditions at a constant room temperature. Attempts were made to

minimize bias due to movement of subject and probe, and pulse rate and blood pressure were recorded throughout the measurement sessions. None of the participants reported any pain or discomfort during the procedure. After obtaining a constant reading, the splints and rubber dam were removed, the brackets were repositioned on the canines and the archwire was replaced on the teeth. For each measurement session, the mean PU for each tooth was calculated based on the phase of stable values, excluding peaks attributable to movement artefacts. LDF data was transferred to a computer connected to the RS-232 port of the flowmeter using the system's own software (PeriSoft for Windows, Perimed) and stored for analysis at a later date.

Statistical analysis

Statistical analysis was performed using the MedCalc 13.0 software program (MedCalc Software bvba, Ostend, Belgium; <http://www.medcalc.org>; 2014). Differences between the PBF values of the study and control groups for each measurement session were analyzed using the Friedman test. Changes in PBF within and between groups were assessed by the Wilcoxon signed rank and Mann-Whitney *U* tests, respectively, with statistical significance set at $p < 0.05$.

Results

Mean treatment duration for canine retraction was 3.88 ± 0.30 months, and mean canine retraction was 4.09 mm. Of the 24 mini-implants inserted, mobility was observed in the first month in 1 implant, which was immediately replaced. The overall success rate of the mini-implants was 95.8%. None of the subjects complained of pain or tooth discoloration during the study period, and periapical radiographs of the patients in the study group showed no signs of root resorption.

Table 1 shows the maxillary canine PBF values at T0, T1, T2, T3, T4 and T5 for the study and control groups. Whereas no significant changes in PBF were observed in the control group, the Friedman test showed that mean PBF in the study group increased significantly from T0 [3.6 ± 0.1 perfusion units (PU) and 3.6 ± 0.1 PU, respectively for right and left canines] to T1 (3.7 ± 0.1 PU and 3.7 ± 0.1 PU, respectively for right and left canines, $p < 0.001$), decreased severely at T2, and remained significantly lower than baseline at T2 and T3 (3.3 ± 0.1 and 3.4 ± 0.1 PU, respectively, $p < 0.001$). At T4 and T5, PBF was again similar to levels measured prior to retraction. The Wilcoxon Signed Rank test showed no statistically significant differences in PBF between T0 and T4 ($p = 0.192$), T0 and T5 ($p = 0.141$), or T4 and T5 ($p = 0.062$). The changes

Table 1. Mean perfusion units and SDs of maxillary canine LDF measurements.

Med (min-max) Mean \pm SD	T0	T1	T2	T3	T4	T5	<i>p</i> Value ^a
Study group <i>n</i> = 24 Med (min-max)	3.6 (3.4-3.9)	3.7 (3.4-4)	3.3 (3.0-3.5)	3.5 (3.2-3.7)	3.7 (3.4-3.9)	3.7 (3.4-3.9)	<0.001*
Mean \pm SD	3.6 \pm 0.2	3.7 \pm 0.2	3.3 \pm 0.1	3.4 \pm 0.1	3.6 \pm 0.2	3.6 \pm 0.2	
Control group <i>n</i> = 24 Med (min-max)	3.7 (3.4-4)	3.7 (3.3-3.9)	3.7 (3.3-4)	3.6 (3.4-4)	3.6 (3.4-3.9)	3.6 (3.4-4)	0.331
Mean \pm SD	3.7 \pm 0.1	3.7 \pm 0.2	3.7 \pm 0.2	3.7 \pm 0.2	3.6 \pm 0.2	3.7 \pm 0.2	
<i>p</i> Value ^b	0.967	0.577	<0.001*	<0.001*	0.918	0.718	

^aFriedman test.

^bMann Whitney *U* test.

* $p < 0.005$.

in canine PBF over time in the study group compared with the relatively constant PBF in the control group are illustrated in Figure 2.

Discussion

The current study compared LDF data for maxillary canines of subjects undergoing mini-implant-supported maxillary canine retraction with data for a non-orthodontic control group over a period of approximately 4 months. Whereas baseline PBF values (T0) did not differ significantly between groups, PBF values after initiation of canine retraction were significantly lower in the study group than in the control group at Day 3 (T2) and Day 7 (T3). PBF in the study group returned to baseline levels at T4 and remained at these levels at T5; thus, no differences in PBF were observed between the study and control groups at either T4 or T5. No statistically significant mean change in maxillary canine PBF was observed over the course of the study period in the control group, indicating the reduction in PBF registered in subjects undergoing retraction to be unrelated to repeated measurement, flowmeter calibration, or test sensitivity.

Mean PBF of maxillary canines in the study group increased slightly 24 h after the initiation of retraction ($101.2 \pm 1.1\%$ of the baseline). This increase can be attributed to an acute inflammatory reaction triggered by the force applied to the tooth, including blood-vessel dilatation and increased blood circulation that normally occur during the initial stages of the inflammation and tissue-repair processes.[23] Fortunately, this hypervascular episode was brief and followed by an ischemic phase; had the hypervascular episode continued, the increased PBF would likely have resulted in increased tissue pressure and, ultimately, pulpal injury or death.[24] The most significant change in PBF was observed in the study group 3 days after the onset of retraction, when PBF dropped severely to $89.4 \pm 0.4\%$ of mean baseline levels, possibly due to a significant compression of the blood-supplying vessels due to transient apical displacement of the tooth caused by

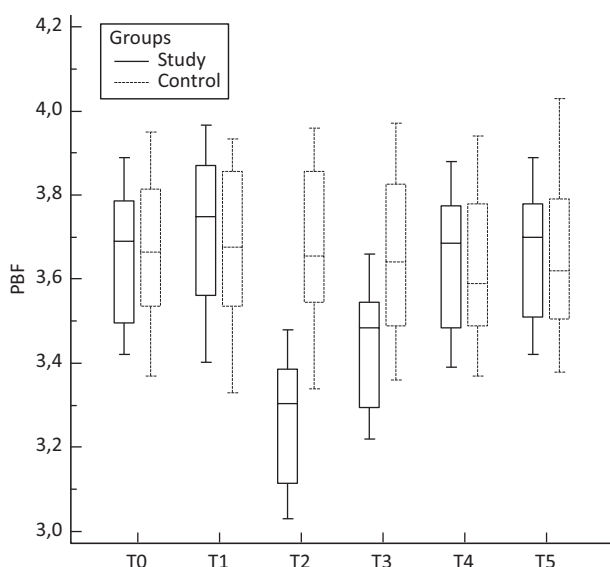


Figure 2. Mean PBF changes over time for study and control groups.

retraction.[25] PBF values gradually increased, reaching $94.3 \pm 0.5\%$ of baseline at Day 7 and $99.7 \pm 0.2\%$ of baseline at Month 1. Pulpal perfusion was measured to be slightly higher than baseline ($100.2 \pm 0.2\%$) when the orthodontic force was removed at the end of retraction, but this increase was insignificant.

The changes observed at Day 7 may be explained by a revitalization of capillaries present in the pulp following some type of stimulation that represents a transition from the acute to chronic phase of the inflammatory process.[26,27] Force decay due to a loss of mechanical properties of the NiTi coil springs used for space closure may also have contributed to the recovery in PBF.[28] These findings demonstrate the capacity of pulp tissue to adapt to the application of 100 g of force during canine retraction after 1 month.

The present study's findings that changes in blood flow are temporary and are followed by a pattern of gradual recovery over time – with a marked increase in PBF after 7 days and a return to normal within 1 month – are supported by numerous previous animal studies as well as histological studies conducted on human teeth.[29–35] In an immunohistochemical study by Vandevska-Radunovic et al. [33] that evaluated changes in blood-vessel density of rat pulp after mesial tipping, inflammatory vascular reactions were observed to subside within 3 weeks in all tissue. Rohaya et al. [34] reported gingival crevicular fluid levels of aspartate aminotransferase, an intracellular enzyme released to the extracellular environment upon cell death, to be highest in the first week of intrusion and gradually decrease over a 3-week period. This also supports the hypothesis that orthodontic treatment can cause temporary, reversible metabolic changes in pulp tissue. Similarly, Grunheid et al. [32] found that a number of pathological signs in rat pulp tissue peaked at 24 and 72 hours after force application, but returned to initial levels after 168 hours; considering that tissue regeneration was initiated almost immediately after the onset of tooth movement, the authors concluded that controlled mechanical forces during orthodontic treatment, if not excessive, cause only transient pulpal changes. In contrast, many studies have indicated that injury to dental pulp can be permanent and lead to an eventual loss of vitality.[2,36,37]

Despite the conclusion reached by numerous animal studies that orthodontic forces can have an iatrogenic effect on pulpal circulation, it is difficult to correlate these findings with those of the present study given the differences in physiological and/or methodological parameters. Only a few human studies have evaluated the response of dental pulp to orthodontic forces using LDF.[25,29,38,39] Ikawa et al. [35] reported that brief application of intrusive force significantly reduced PBF. Similarly, Brodin et al. [39] showed orthodontic intrusion to evoke a temporary reduction in PBF, whereas extrusion had no effect on PBF. In a study examining the effects of the continuous application of intrusive force on dental pulp, Sano et al. [25] found PBF to decrease significantly after 3 days, but to return to near-baseline values after 3 weeks. These findings match those of the present study. In contrast, Barwick and Ramsay [29] indicated that the application of intrusive force did not alter PBF. It should be noted that the previous LDF studies demonstrating temporary detrimental

changes in human pulp subjected to orthodontic force, while supporting the findings of the present study, evaluated a large variety of tooth movements, including extrusion and intrusion, whereas the present study evaluated changes in PBF following orthodontic retraction. Given that the response of pulp tissue may vary according to the type of tooth movement, it is not appropriate to compare the findings of these earlier studies with those of the present one.

Currently, only one published study has evaluated PBF values of human teeth after the application of retractive force. In that study, McDonald and Pitt Ford [22] found an initial, brief decrease in PBF lasting approximately 32 minutes, followed by a period in which PBF increased to above-baseline values; although PBF remained at high levels for 48 hours, it returned to normal within 72 h following canine retraction. Similar to McDonald and Pitt Ford,[22] the present study observed pulpal hyperemia 24 hours after the application of retractive force; however, rather than returning to baseline at 72 hours, PBF in the present study dropped severely at Day 3 and did not return to baseline levels for one month.

Given the great variations in methodologies between the two studies, it would be wrong to correlate our results with those of McDonald and Pitt Ford.[22] Whereas, McDonald and Pitt Ford [22] applied a retraction force of 50 g with a simple removable appliance attached to the palatal surface of canines using posterior teeth as dental anchorage, we applied a retractive force of 100 g using mini-implant-supported fixed appliances as a skeletal anchorage unit to retract the canines with maximum anchorage control. Since the mini-implants are inserted more apically than the molar hooks used for dental anchorage, this type of skeletal anchorage produces a more vertical vector of force that is likely to result in an intrusive effect in association with canine retraction and could thus be expected to promote greater stress in the canine apical region than the use of dental anchorage.[40] The higher degree of stress could pose a greater risk to pulp microcirculation, which would explain the depression in PBF observed in our study.

In addition to differences related to retraction methodology, the two studies also differed in terms of LDF methodology, with McDonald and Pitt Ford [22] using a silicone splint made from rubber putty impression material and our study using a rubber dam together with custom-made acrylic splints. Due to difficulties associated with LDF measurements, McDonald and Pitt Ford [22] were able to measure PBF for 72 hours only, and the lack of optic isolation resulted in mean PBF values that were extremely high, even in relation to other studies that measured PBF levels without a rubber dam (7.6–14 PU).[18,41] In our study, the use of custom-made acrylic splints in combination with a rubber dam allowed us to measure PBF until the completion of canine retraction (approximately 4 months).

Finally, differences in subject age between the two studies may have played the most important role in the differences in study findings. In McDonald and Pitt Ford's study,[22] patients were between 11 and 13.5 years of age, with a mean age of 12.6 years, whereas our patients ranged in age between 19–25 years, with a mean age of 21.91 years. Although the issue of apex closure was not mentioned, it is likely that apical closure

had not yet been completed in the orthodontically moved teeth in the previous study, given the younger age of patients.[22] Wider apical foramen would have not only prevented orthodontic treatment from compromising pulpal circulation, it could even explain the hyperaemia observed at 48 h in their study.[22] Hamersky et al. [2] have suggested that in the case of an open apex, both the ability of larger vessels to enter the pulp and the increased amount of loose connective tissue stroma in the area may help to minimize the decrease in blood flow during the application of orthodontic force. Conversely, limited pulp access for larger vessels and fewer stroma present with a mature apex could exacerbate the effects of orthodontic force on pulpal blood flow. This theory is supported by previous studies. In a radiorespirometric study by Unsterseher et al. [30] the relative amount of depression in pulpal respiratory rates increased with increases in subject age. Similarly, Stenvik and Mjor [7] noted that the degree of pulpal reaction to orthodontic forces was dependent upon the degree of root development, with more severe histologic disturbances found in teeth with smaller apical foramina. These results seem to indicate a relationship between the biological repercussions of orthodontic force and tooth maturity, particularly in terms of pulp dentinogenic activity. In other words, a high degree of dentinogenic activity coupled with a large apical foramen may be expected to reduce the detrimental effects of orthodontic force.

Retraction of the maxillary canines after first premolar extraction is a very common orthodontic procedure used in cases of crowding and for the correction of a large overjet. The process is a slow one, and it is heavy on anchorage requirements. Maintaining the space obtained through extractions may necessitate various intraoral as well as extraoral anchorage mechanics, requiring maximum anchorage. The mini-implants used as skeletal anchorage during canine retraction in the present study are easy to place and eliminate problems related to patient compliance associated with extraoral devices,[42,43] while at the same time shortening the length of orthodontic treatment.[42]

In addition to retraction methodology, differences in the magnitude and duration of applied force may also account for the differences in the changes in pulp circulation reported to occur in response to orthodontic treatment. The optimal magnitude of force for canine retraction has not yet been established. While Storey and Smith [43] recommend a force of 150–200 g, Boester and Johnston [44] used a force of 140–300 g and Paulsen et al. [45] a force of 50–75 g. Given that an increase in the amount of force applied has been shown to have minimal effect on the rate of retraction,[43,44] the present study applied a relatively light force (100 g) during canine retraction in order to minimise the possibility of root resorption.

According to Kumar et al. [46] it is not the magnitude of force applied, but its duration, that is important for good biologic tooth response. Orthodontic treatment does not take place overnight, making it of vital importance that pulpal reaction be evaluated over a long time span of at least 3 months. In the present study, PBF measurements started one day after mini-implant loading and continued until the end of retraction (approximately 4 months). Measuring PBF three

times during the first week made it possible to observe gradual signs of inflammation due to light force, whereas measurements taken at 1 and 3 months were designed to capture possible chronic changes.[46,47]

LDF testing

While LDF may be the most appropriate method for accurately determining pulp vitality, LDF assessment of PBF is highly susceptible to environmental and technical factors, such as flowmeter characteristics,[48,49] gingival isolation device,[21,41] ambient temperature, probe position and patient position and rest status.[21,41,50] Other patient-related factors such as those associated with stress, medication and age can also affect LDF measurements of PBF.[51,52] Laser wavelength is also an issue: Although lasers with longer wavelengths produce higher flux readings (probably due to their greater penetration through tooth tissue), the inclusion of non-pulpal blood flow within the signal may reduce the vital-to-nonvital signal ratio.[50] For this reason, the present study used a 632.8 nm laser source rather than a 780 nm or 810 nm laser. Furthermore, custom-made acrylic-resin splints were used to stabilise the probe, maintain it in contact with teeth and create reproducible positions for follow-up measurements. In a technique successfully employed in earlier studies,[52,53] an opaque rubber dam was used in conjunction with the splints in order to minimise the contribution of neighbouring pulp and gingiva to the flux signal. To further ensure the validity of the measurements, special care was taken to maintain ambient temperatures and patient-related factors such as position, rest and stress levels.

Despite the various precautions taken to eliminate possible problems associated with LDF measurements of maxillary canines, contralateral canines in the same subject could not be used as control teeth because of the malocclusion being treated. Therefore, canines from different patients were used as controls. Considering that numerous patient-related biological factors can influence pulpal response, extrapolation of results to the experimental canines may be problematic. This is an important aspect that requires further study.[54,55]

Conclusion

This study provides strong evidence that following “hypervascular” pulpal response at 24 h after the initiation of canine retraction, PBF undergoes a significant decline over the long term, returning to near-baseline levels within one month. These findings demonstrate that the changes in PBF observed to occur during canine retraction are reversible.

Disclosure statement

The authors report no conflicts of interest. The authors alone are responsible for the content and writing of this article.

References

- [1] Rygh P, Bowling K, Hovlandsdal L, et al. Activation of the vascular system: a main mediator of periodontal fiber remodeling in orthodontic tooth movement. *Am J Orthod.* 1986;89:453–468.
- [2] Hamersky PA, Weimer AD, Taintor JF. The effect of orthodontic force application on the pulpal tissue respiration rate in the human premolar. *Am J Orthod.* 1980;77:368–378.
- [3] Mostafa YA, Iskander KG, El-Maangoury NH. Iatrogenic pulpal reactions to orthodontic extrusion. *Am J Orthod Dentofacial Orthop.* 1991;99:30–34.
- [4] Nixon CE, Saviano JA, King GJ, et al. Histomorphometric study of dental pulp during orthodontic tooth movement. *J Endod.* 1993;19:13–16.
- [5] Cooper SM, Sims MR. Evidence of acute inflammation in the periodontal ligament subsequent to orthodontic tooth movement in rats. *Aust Orthod J.* 1989;11:107–109.
- [6] Butcher EO, Taylor AC. The vascularity of the incisor pulp of the monkey and its alteration by tooth retraction. *J Dent Res.* 1952;31:239–247.
- [7] Stenvik A, Mjor IA. Pulp and dentine reactions to experimental tooth intrusion. A histologic study of the initial changes. *Am J Orthod.* 1970;57:370–385.
- [8] Karayilmaz H, Kirzioğlu Z. Comparison of the reliability of laser Doppler flowmetry, pulse oximetry and electric pulp tester in assessing the pulp vitality of human teeth. *J Oral Rehabil.* 2011;38:340–347.
- [9] Alomari FA, Al-Hababeh R, Alsakarna BK. Responses of pulp sensibility tests during orthodontic treatment and retention. *Int Endod J.* 2011;44:635–643.
- [10] Chen E, Goonewardene M, Abbott P. Monitoring dental pulp sensibility and blood flow in patients receiving mandibular orthognathic surgery. *Int Endod J.* 2012;45:215–223.
- [11] Alghathiy RA, Qualtrough AJ. Pulp sensibility and vitality tests for diagnosing pulpal health in permanent teeth: a critical review. *Int Endod J.* 2016. Doi:10.1111/iej.12611.
- [12] Karayilmaz H, Kirzioğlu Z. Evaluation of pulpal blood flow changes in primary molars with physiological root resorption by laser Doppler flowmetry and pulse oximetry. *J Clin Pediatr Dent.* 2011;36:139–144.
- [13] Kim S, Schuessler G, Chien S. Measurement of blood flow in the dental pulp of dogs with the ¹³³Xenon washout method. *Arch Oral Biol.* 1983;28:501–505.
- [14] Tønder KJH, Aukland K. Blood flow in the dental pulp in dogs measured by local H₂ gas desaturation technique. *Arch Oral Biol.* 1974;20:73–79.
- [15] Gazelius B, Olgart L, Edwall B, et al. Non-invasive recording of blood flow in human dental pulp. *Endod Dent Traumatol.* 1986;2:219–221.
- [16] Nissan R, Trope M, Zhang C-D. Chance. Dual wavelength spectrophotometry as a diagnostic test of the pulp chamber contents. *Oral Surg Oral Med Oral Pathol.* 1992;74:508–514.
- [17] Kahan RS, Gulabivala K, Snook M, et al. Evaluation of a pulse oximeter and customized probe for pulp vitality testing. *J Endod.* 1996;22:105–109.
- [18] Olgart L, Gazelius B, Lindh-Stromberg U. Laser Doppler flowmetry in assessing vitality in luxated permanent teeth. *Int Endod J.* 1988;21:300–306.
- [19] Wilder-Smith PE. A new method for the non-invasive measurement of pulpal blood flow. *Int Endod J.* 1988;21:307–312.
- [20] Vongsavan V, Matthews B. Experiments in pigs on the sources of laser Doppler blood-flow signals recorded from teeth. *Arch Oral Biol.* 1996;41:97–103.
- [21] Hartmann A, Azerad J, Boucher Y. Environmental effects on laser Doppler pulpal blood-flow measurements in man. *Arch Oral Biol.* 1996;41:333–339.
- [22] McDonald F, Pitt Ford TR. Blood flow changes in permanent maxillary canines during retraction. *Eur J Orthod.* 1994;16:1–9.
- [23] Krishnan V, Park Y, Davidovitch Z. Biology of orthodontic tooth movement: an overview. In: Krishnan V, Davidovitch Z, editors. *Biological mechanisms of tooth movement.* Chichester, United Kingdom: Wiley-Blackwell; 2009. p. 19–43.
- [24] Watson AD, Pitt Ford TR, McDonald F. Blood flow changes in the dental pulp during limited exercise measured by laser Doppler flowmetry. *Int Endod J.* 1992;25:82–87.

- [25] Sano Y, Ikawa M, Sugawara J, et al. The effect of continuous intrusive force on human pulpal blood flow. *Eur J Orthod.* 2002;24:159–166.
- [26] Santamaria M Jr, Milagres D, Stuani AS, et al. Initial changes in pulpal microvasculature during orthodontic tooth movement: a stereological study. *Eur J Orthod.* 2006;28:217–220.
- [27] Stanley HR, Weisman MI, Michanowicz AE, et al. Ischemic infarction of the pulp: sequential degenerative changes of the pulp after traumatic injury. *J Endod.* 1978;4:325–335.
- [28] Dixon V, Read MJ, O'Brien KD, et al. A randomized clinical trial to compare three methods of orthodontic space closure. *J Orthod.* 2002;29:31–36.
- [29] Barwick PJ, Ramsay DS. Effect of brief intrusive force on human pulpal blood flow. *Am J Orthod Dentofacial Orthop.* 1996;110:273–279.
- [30] Unterseher RE, Nieberg LG, Weimer AD, et al. The response of human pulpal tissue after orthodontic force application. *Am J Orthod Dentofacial Orthop* 1987;92:220–224.
- [31] Labart WA, Taintor JF, Dyer JK, et al. The effect of orthodontic forces on pulpal respiration in the rat incisor. *J Endod* 1980;9:724–727.
- [32] Grunheid T, Morbach BA, Zentner A. Pulpal cellular reactions to experimental tooth movement in rats. *Oral Surg Oral Med Oral Pathol Oral Radiol Endod.* 2007;104:434–441.
- [33] Vandevska-Radunovic V, Kvinnsland S, Kvinnsland IH. Effect of experimental tooth movement on nerve fibers immunoreactive to calcitonin gene-related peptide, protein gene product 9.5, and blood vessel density and distribution in rats. *Eur J Orthod.* 1997;19:517–529.
- [34] Rohaya MAW, Shahrul Hisham ZA, Khazlina K. Preliminary study of aspartate aminotransferase activity in gingival crevicular fluids during orthodontic tooth movement. *J Appl Sci.* 2009;9:1393–1396.
- [35] Ikawa M, Fujiwara M, Horiuchi H, et al. The effect of short-term tooth intrusion on human pulpal blood flow measured by laser Doppler flowmetry. *Arch Oral Biol.* 2001;46:781–787.
- [36] Derringer KA, Linden RWA. Angiogenic growth factors released in human dental pulp following orthodontic force. *Arch Oral Biol.* 2003;48:285–291.
- [37] Guevara MH, McClugage SG. Effects of intrusive forces upon the microvasculature of the dental pulp. *Angle Orthod.* 1980;50:129–134.
- [38] Aisenberg MS. The tissues and changes involved in orthodontic tooth movements. *Am J Orthod.* 1948;34:854–859.
- [39] Brodin P, Linge L, Aars H. Instant assessment of pulpal blood flow after orthodontic force application. *J Orofac Orthop.* 1996;57:306–309.
- [40] de Assis Claro CA, Chagas RV, Neves AC, et al. Comparative photoelastic study of dental and skeletal anchorages in the canine retraction. *Dental Press J Orthod.* 2014;19:100–105.
- [41] Soo-ampon S, Vongsavan N, Soo-ampon M, et al. The sources of laser Doppler blood-flow signals recorded from human teeth. *Arch Oral Biol.* 2003;48:353–360.
- [42] Kuroda S, Sugawara Y, Deguchi T, et al. Clinical use of miniscrew implants as orthodontic anchorage: success rates and postoperative discomfort. *Am J Orthod Dentofacial Orthop.* 2007;131:9–15.
- [43] Storey E, Smith RE. Force in orthodontics and its relation to tooth movement. *Aust Dent J.* 1952;56:11–13.
- [44] Boester CH, Johnston LE. A clinical investigation of the concepts of differential and optimal force in canine retraction. *Angle Orthod.* 1972;44:113–119.
- [45] Paulsen RC, Speidel TM, Isaacson RJ. A laminagraphic study of cuspid retraction versus molar anchorage loss. *Angle Orthod.* 1970;40:20–27.
- [46] Kumar V, Abbas AK, Fausto N. Robbins and Cotran pathologic basis of disease, 7th ed. Philadelphia, PA: Elsevier Saunders; 2005. p. 5–116.
- [47] Ramazanzadeh BA, Sahhafian AA, Mohtasham N, et al. Histological changes in human dental pulp following application of intrusive and extrusive orthodontic forces. *J Oral Sci.* 2009;51:109–115.
- [48] Ingolfsson AER, Tronstad L, Riva CE. Reliability of laser Doppler flowmetry in testing vitality of human teeth. *Endod Dent Traumatol.* 1994;10:185–187.
- [49] Odor TM, Pitt Ford TR, McDonald F. Effect of wavelength and bandwidth on the clinical reliability of laser Doppler recordings. *Endod Dent Traumatol.* 1996;12:9–15.
- [50] Ikawa M, Komatsu H, Ikawa K, et al. Age-related changes in the human pulpal blood flow measured by laser Doppler flowmetry. *Dent Traumatol.* 2003;19:36–40.
- [51] Olgart LM, Edwall B, Gazelius B. Neurogenic mediators in control of pulpal blood flow. *J Endod.* 1989;15:409–412.
- [52] Kijssamanmith K, Timpawat S, Vongsavan N, et al. Pulpal blood flow recorded from human premolar teeth with a laser Doppler flow meter using either red or infrared light. *Arch Oral Biol.* 2011;56:629–633.
- [53] Anderson KK, Vanarsdall RL, Kim S. Measurement of pulpal blood flow in humans using laser Doppler flowmetry: a technique allowing stability and repeatability of pulpal blood flow measurement during surgical manipulations. *Int J Adult Orthodon Orthognath Surg.* 1995;10:247–254.
- [54] Lundgren D, Owman-Moll P, Kurol J. Early tooth movement pattern after application of a controlled continuous orthodontic force. A human experimental model. *Am J Orthod Dentofacial Orthop.* 1996;110:287–294.
- [55] Konno Y, Daimaruya T, Likubo M, et al. Morphologic and hemodynamic analysis of dental pulp in dogs after molar intrusion with the skeletal anchorage system. *Am J Orthod Dentofacial Orthop.* 2007;132:199–207.