

Effect of Platelet-Rich Plasma on Fibrocartilage, Cartilage, and Bone Repair in Temporomandibular Joint

Nükhet Kütük, PhD, DDS, *Burcu Baş, PhD, DDS, †Emrah Soylu, DDS, ‡Zeynep Burçin Gönen, DDS, ‡Canay Yılmaz, DDS, ‡Esra Balcıoğlu, MSc, §Saim Özdamar, PhD, MD, || and Alper Alkan, DDS, PhD ¶

Purpose: The purpose of the present study was to explore the potential use of platelet-rich-plasma (PRP) in the treatment of temporomandibular joint osteoarthritis (TMJ-OA).

Materials and Methods: Surgical defects were created bilaterally on the condylar fibrocartilage, hyaline cartilage, and bone to induce an osteoarthritic TMJ in rabbits. PRP was applied to the right joints of the rabbits (PRP group), and the left joints received physiologic saline (control group). After 4 weeks, the rabbits were sacrificed for histologic and scanning electron microscopy (SEM) examinations. The data were analyzed statistically.

Results: The new bone regeneration was significantly greater in the PRP group ($P < .011$). Although the regeneration of the fibrocartilage and hyaline cartilage was greater in the PRP group, no statistically significant difference was found between the 2 groups. SEM showed better ultrastructural architecture of the collagen fibrils in the PRP group.

Conclusions: PRP might enhance the regeneration of bone in TMJ-OA.

© 2014 American Association of Oral and Maxillofacial Surgeons
J Oral Maxillofac Surg 72:277-284, 2014

Osteoarthritis (OA) refers to an inflammatory condition that results in erosion and fibrillation of the articular cartilage and degeneration of the underlying subcondylar bone.¹ Temporomandibular joint (TMJ)-OA is a subtype of temporomandibular disorders characterized by severe pain and dysfunction of the TMJ.² Women have a higher incidence of OA. The typical symptoms include joint clicking and crepitus, joint and muscle tenderness, restricted mouth opening, and deviation of the mandible during opening.^{3,4}

The initial treatment of TMJ-OA is noninvasive and includes physiotherapy and/or medical treatment with acetaminophen and nonsteroidal anti-inflammatory agents.⁵ However, these approaches are palliative and do not permanently influence the biochemical environment of the TMJ. It has been reported that injection of hyaluronic acid (HA) and steroids into the joint space can be beneficial for pain relief. However, their effects on joint structures have been controversial.^{6,7}

*Assistant Professor, Department of Oral and Maxillofacial Surgery, Erciyes University Faculty of Dentistry, Melikgazi, Kayseri, Turkey.

†Associate Professor, Department of Oral and Maxillofacial Surgery, Ondokuz Mayıs University Faculty of Dentistry, Samsun, Turkey.

‡Resident, Department of Oral and Maxillofacial Surgery, Erciyes University Faculty of Dentistry, Melikgazi, Kayseri, Turkey.

§Resident, Department of Histology, Erciyes University Faculty of Medicine, Melikgazi, Kayseri, Turkey.

||Professor, Department of Histology, Erciyes University Faculty of Medicine, Melikgazi, Kayseri, Turkey.

¶Professor, Department of Oral and Maxillofacial Surgery, Erciyes University Faculty of Dentistry, Melikgazi, Kayseri, Turkey.

This study was supported by the Scientific and Technological Research Council of Turkey (TUBITAK).

This study was presented at the 7th Oral and Maxillofacial Surgery Society-ACBID Congress, May 29 to June 2, 2013, Antalya, Turkey, as an oral presentation.

Address correspondence and reprint requests to Dr Kütük: Department of Oral and Maxillofacial Surgery, Erciyes University Faculty of Dentistry, Melikgazi, Kayseri 38039 Turkey; e-mail: NCelebi@erciyes.edu.tr

Received July 24 2013

Accepted September 7 2013

© 2014 American Association of Oral and Maxillofacial Surgeons

0278-2391/13/01198-1\$36.00/0

<http://dx.doi.org/10.1016/j.joms.2013.09.011>

The management of chondral disease is challenging because of the low healing potential of cartilage tissue, owing to its lack of vascularization.^{8,9} Therefore, new methods of stimulating the repair of cartilage are being investigated, including matrix metalloproteinase and cytokine inhibitors, calcitonin, bisphosphonates, and growth factors (GFs).^{10,11} Among these, GFs offer promise, because they stimulate cellular division, growth, and differentiation.¹¹ GFs are a group of biologically active polypeptides produced by the body. Previous studies have demonstrated that specialized secretory granules of platelets contain large reservoirs of GFs, such as platelet-derived growth factor AB, transforming GF- β (TGF- β), insulin-like GF-I (IGF-I), epidermal GF, and endothelial cell GF. These factors are released when platelets are activated by stimulus or aggregated by some activators.^{12,13} In the articular cartilage, numerous GFs regulate tissue healing throughout life.

Platelet-rich plasma (PRP) is blood plasma with highly concentrated platelets.¹⁴ Although a normal concentration of platelets circulating in the blood is 200,000/ μ L, the platelet count in PRP can exceed 2 million/ μ L.¹⁵ PRP has recently been used successfully for the treatment of knee degenerative pathologic disorders, because it is safe and has the potential to reduce pain and improve function.^{16,17} The application of PRP in cartilage repair is relatively new, and no published studies have investigated its use in the treatment of TMJ degenerative disease.

The purpose of the present study was to explore the potential use of PRP in the treatment of TMJ-OA. Our hypothesis was that PRP might enhance the healing of the degenerated tissues because it contains several bioactive GFs in large amounts. Our aim was to determine whether this novel approach would be effective for the regeneration of hyaline cartilage, fibrocartilage, and bone in experimentally induced OA in rabbits.

Materials and Methods

ANIMALS

The local animal ethics committee of Erciyes University approved the study protocol. A total of 16 New Zealand white rabbits (weight 2.84 ± 0.16 kg, aged 12 months) were used in the present study. They were kept in a dedicated animal holding facility in the laboratory animal unit and were housed individually in stainless steel cages. The rabbits were fed with standard laboratory rabbit chow and water, ad libitum. All the rabbits received antibiotics (0.6 mg/kg, lincomycin 600 mg, İbrahim Etem Ulagay İlaç Sanayi, Turk AŞ, Istanbul, Turkey) and analgesics (0.5 mg/kg, Adiljin, Sanovel, Istanbul, Turkey) as a single intramuscular injection preoperatively and for 3 consecutive days postoperatively.

PRP PREPARATION

A total of 18 mL of blood was collected from the marginal vein of the ear and mixed with 2 mL of citrate dextrose formula to prevent early clotting. The anticoagulated blood mixture was placed in a platelet separation kit (Harvest SmartPrep, Plymouth, MA) in accordance with the system instructions and centrifuged for 14 minutes. After centrifugation, the PRP was collected from the disposable, and 1 mL of PRP was diluted and sent to the laboratory for the platelet count. For gelatinous formation, 10% calcium chloride solution (Adeka İlaç Sanayi, Samsun, Turkey) was added to the PRP, and 1 mL of PRP was applied to the defect area.

SURGICAL PROCEDURES

Of the 16 rabbits, 14 underwent bilateral TMJ surgical procedures and 2 were used as intact controls. The rabbits were anesthetized with 20 mg/kg xylazine (Rompun 2%, Bayer, Istanbul, Turkey) and 4 mg/kg sodium ketamine hydrochloride (Ketalar, Pfizer, Istanbul, Turkey). The preauricular area was shaved and infiltrated with 1 mL of articaine hydrochloride (Ultracaine DS, Sanofi Aventis, Istanbul, Turkey). The surgical technique was adopted from the study by Takafuji et al.¹⁸ A horizontal skin incision was made from just posterior to the lateral canthus of the eye to a point anterior to the external acoustic meatus. After soft tissue dissection, the zygomatic-squamosal suture line and zygomatic process overlying the TMJ were exposed. The zygomatic process was then carefully removed. After exposure of the superior joint space, standardized defects were created using a standard round bur (5 mm in diameter) under copious irrigation through the articular disk on the condyle, including the articular cartilage and subcondylar bone (Fig 1). The defects were 5 mm anteroposteriorly and 2.5 mm in depth. To minimize the risk of interindividual variations, the right joints of the rabbits received PRP and the left joints received physiologic saline. The joint capsule and skin were then closed in layers.

After 4 weeks, the rabbits were sacrificed, and the mandibular condyles and articular disk were excised. 10 mandibular condyles that were treated with PRP (PRP group), 10 that were treated with saline (control group), and 2 intact condyles were used for histologic examination. The remaining 10 condyles were used for scanning electron microscopy (SEM) examination.

HISTOLOGIC ANALYSIS

The specimens reserved for histologic examination were fixed in 10% buffered formalin, decalcified with 5% ethylenediamine tetraacetic acid, and embedded in paraffin, uniformly in a standard fashion. The specimens were divided into 2 pieces from the center of

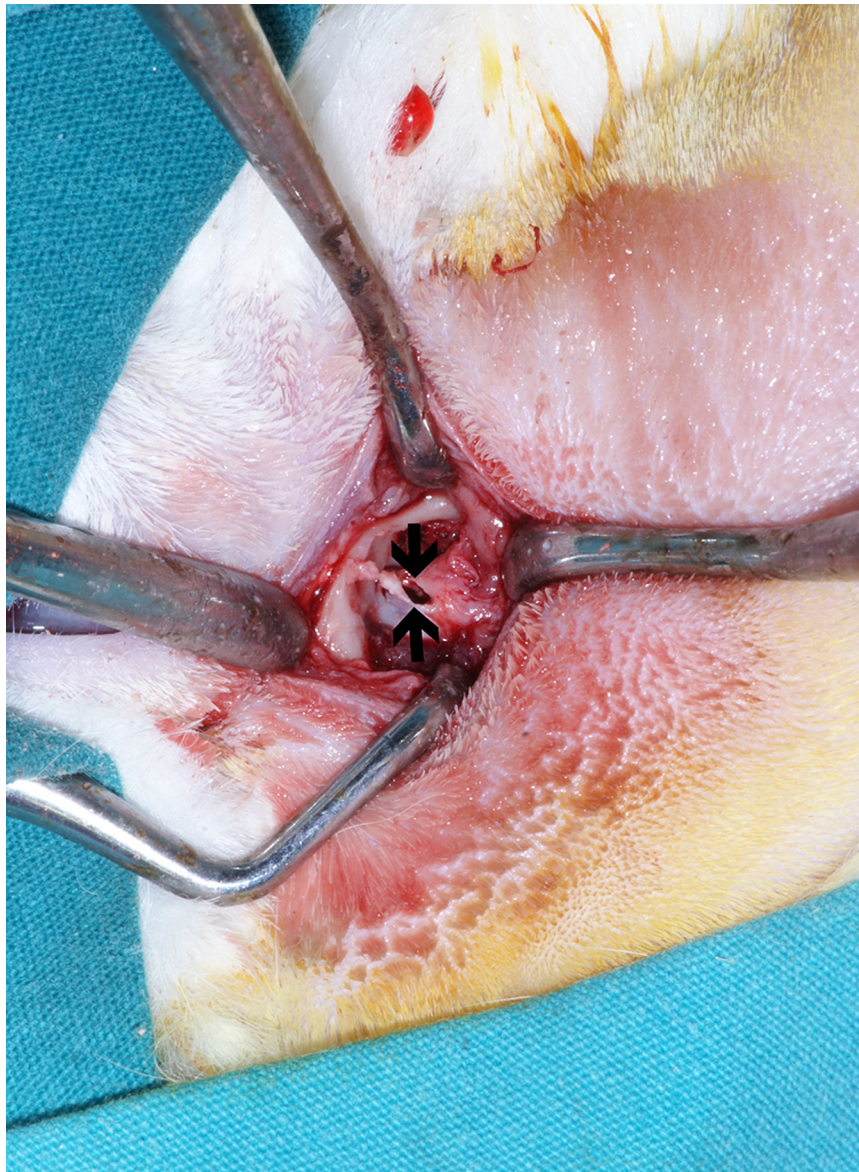

FIGURE 1. A defect was created on the condylar surface through articular disk. Arrows indicate the defect area.

Kütük et al. Effect of PRP on TMJ Repair. J Oral Maxillofac Surg 2014.

the defect. Next, 5- μ m-thick serial sections were cut from each of the 2 parts, and each section was mounted onto individual slides and stained with hematoxylin and eosin for observation using light microscopy. For each specimen, the 5 sections judged to be best were selected from the defect area (as close as possible to the center of the defect) and evaluated by 2 independent blinded observers at 20 \times magnification under a light microscope. The selected sections were subjected to morphometric analyses using a software program (ANALYSIS LS Research, version 5.0, Olympus Soft Imaging Solutions, Münster, Germany). A standard square frame was drawn on the defect area, as close to the center as possible. The connective tissue, fibrocartilage, hyaline cartilage, and bone tissue

areas were separated manually using dots and measured automatically by the software program, giving numeric values in square micrometers (Fig 2). Quantitative analyses were performed to obtain a mean value for each specimen. The relative tissue proportions were then calculated using mean values and expressed in percentiles.

SEM ANALYSES

The specimens reserved for SEM examination were washed in phosphate-buffered saline (PBS, pH 7.2), fixed in 2.5% glutaraldehyde, and washed in PBS for 1 hour. The samples were dehydrated in a series of graded acetones and critically point dried using liquid

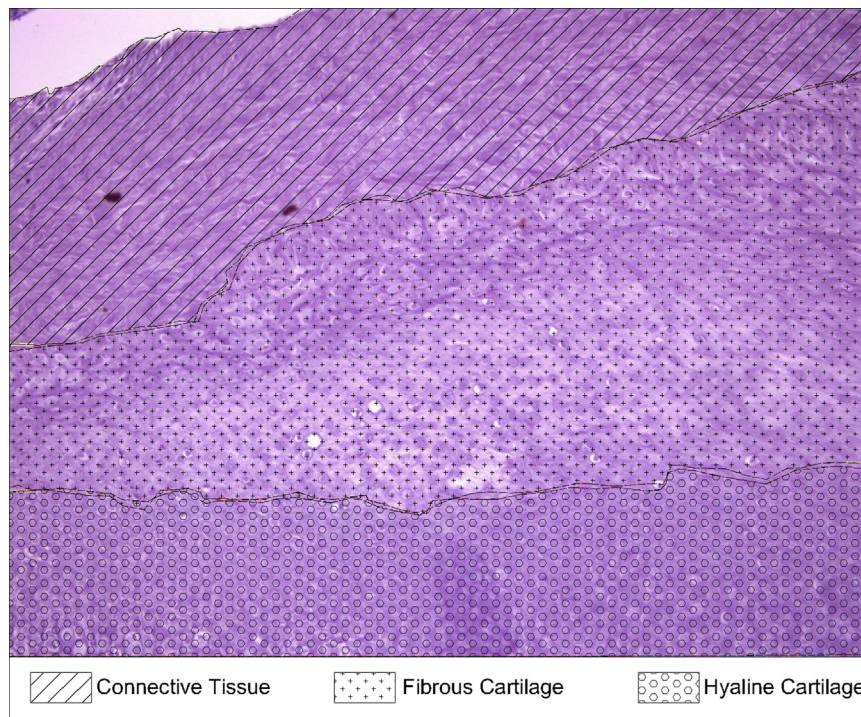


FIGURE 2. Area measurements of bone, hyaline cartilage, fibrocartilage, and connective tissues using light microscopy.

Kütük et al. Effect of PRP on TMJ Repair. J Oral Maxillofac Surg 2014.

carbon dioxide. The samples were then sputter coated with 20 nm gold-palladium for viewing in a scanning electron microscope (LEO 440, Electron Microscopy, Cambridge, UK).

STATISTICAL ANALYSIS

Statistical analyses were performed of the data from the specimens examined histologically using SPSS Statistics for Windows, version 21.0 (IBM, Armonk, NY). The pre-experimental sample size analyses using a power of 0.80 and a significance level of 0.05 indicated the need for 8 animals according to previous studies. Because of the risk of losing animals during the experiment, 10 rabbits were used.

Normalization of the groups was analyzed using the Shapiro-Wilk test, and the differences between the groups were analyzed using the Mann-Whitney *U* test. The data were expressed as the median and minimum to maximum. $P < .05$ was considered statistically significant.

Results

No adverse events such as infection or bleeding were observed, and the rabbits continued their standard nutrition during the healing period. On average, a 5.24-fold increase in the platelet concentration was obtained using the platelet separation kit compared with the whole blood values.

SEM ANALYSIS

All specimens showed the ultrastructure of the mandibular condylar surface. The condylar surface of the intact controls was observed to be smooth without any pathologic changes. In contrast, cracks and irregularities were seen in the PRP and control groups (Fig 3). In the control group, collagen fibrils were arranged as a disorganized network system, and they formed thick and dense bundles (Fig 4A). In the PRP group, the architecture was similar to that of the intact controls, with thin, homogeneous, and well-organized collagen fibrils (Fig 4B).

LIGHT MICROSCOPY ANALYSIS

Under light microscopy, the intact controls showed undamaged surfaces and ordered layers of fibrocartilage, hyaline cartilage, and bone.

In the control group, the surface of the condyle showed an irregular outline with increased fibrosis. A marked reduction in mature hyaline cartilage was observed, and the fibrocartilage that covers the surface was thinner and disorganized. The defects were not filled with tissue in some areas, contributing to the formation of the irregular outline (Fig 5A).

In the PRP group, the hyaline and fibrocartilage were thicker, and the defects had been filled with tissue (Fig 5B). It was apparent that not all the articular disks had been preserved, and remnants of the surgically

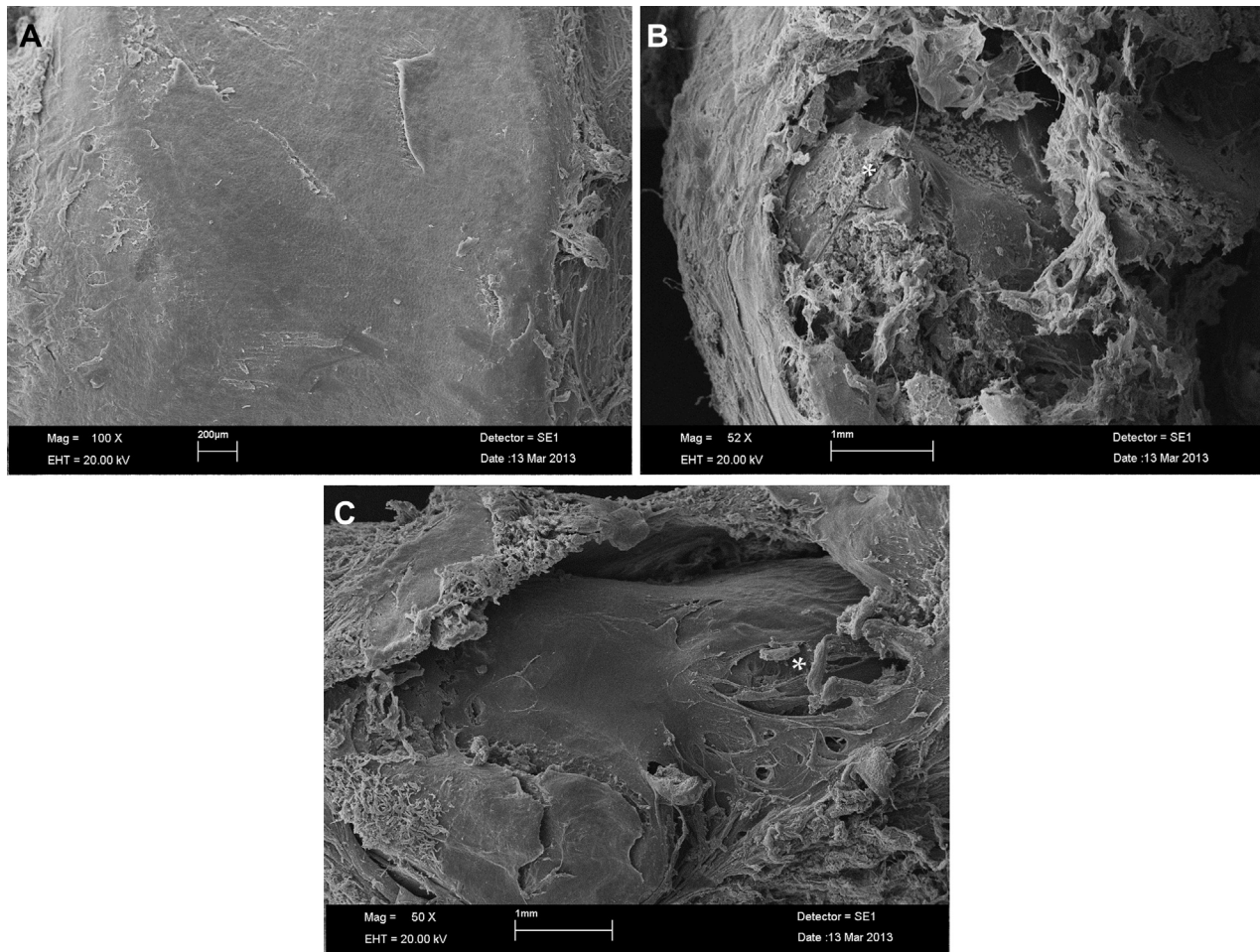


FIGURE 3. Ultrastructure of the condylar surface of the groups on SEM. *A*, Intact control shows the smooth structure of the articular cartilage. *B*, Defect area showing irregularities and structural damage (*asterisk*) in the control group and, *C*, collagen fibrils (*asterisk*) and matrix in PRP group.

Kütük et al. Effect of PRP on TMJ Repair. *J Oral Maxillofac Surg* 2014.

traumatized disk could be seen in some sections in both groups.

The mean proportion of new bone regeneration was significantly greater in the PRP group (0.87%) than in the control group (0.04%; $P = .011$). No statistically significant difference was found between the 2 groups in the regeneration of the fibrocartilage (49.72%; $P = .143$) and hyaline cartilage (31.6%, $P = .579$). The formation of connective tissue was not significantly different between the PRP and control groups (25.70% vs 35.87%, respectively; [Table 1](#)).

Discussion

OA is a degenerative disorder of the synovial joints that affects the articular cartilage and subcondylar bone.¹⁹ Previous studies have attempted to induce a degenerative process or OA of the TMJ using intra-articular injections of biodegrading agents^{20,21} and mechanical²² or surgical^{11,18} methods. Creating a defect in the TMJ

articular structures of rabbits has previously been used successfully as an analog for TMJ-OA in a study by Filinte et al.²³ Similarly, Takafuji et al¹⁸ created a TMJ-OA model by perforating the articular cartilage overlying the mandibular condyle. In the present study, using a modified technique, we created a defect in the articular cartilage through the condylar bone, altering the anatomic structure and distribution of the forces in the TMJ. After 4 weeks, degenerative changes could be seen histologically in the control group. This model of TMJ-OA provided fast and severe destruction of the TMJ articular structures.

Various treatment modalities have been considered to improve the poor healing capacity of degenerated chondrocytes and articular cartilage.^{10,11} In particular, the most recent studies have focused on the tissue biology, indicating the influence of GFs on cartilage repair.^{10,24-27} PRP is a natural source of autologous GFs and has recently been shown to improve cartilage repair in degenerative knee pathologic disorder.^{16,17,28}

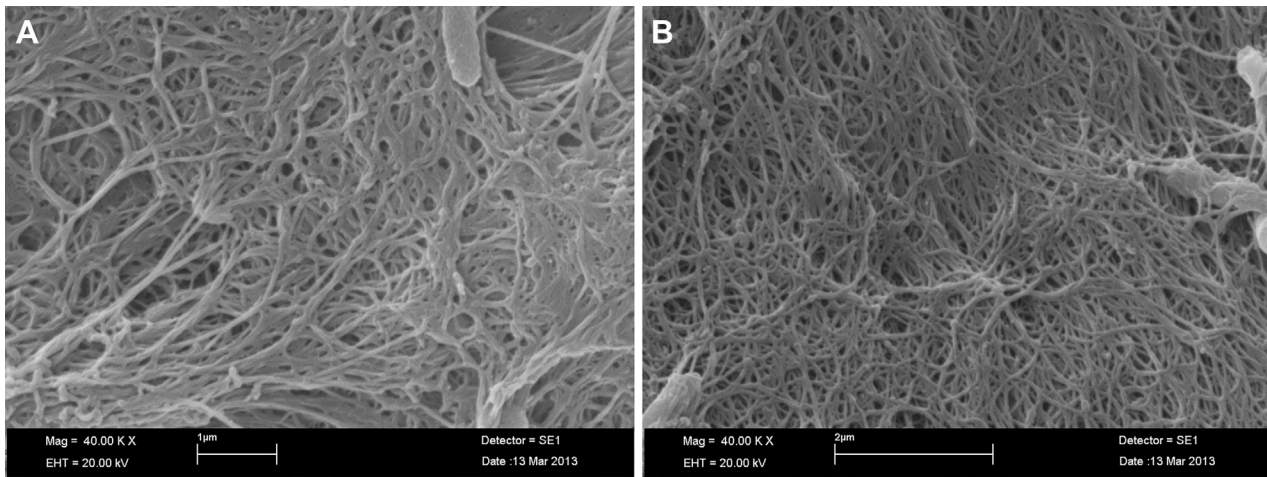


FIGURE 4. SEM showing, *A*, thick and disorganized collagen fibrils in the control group (original magnification $\times 40,000$) and, *B*, thin and well-organized collagen fibrils in the PRP group (original magnification $\times 40,000$).

Kütük et al. Effect of PRP on TMJ Repair. J Oral Maxillofac Surg 2014.

Spakova et al²⁸ treated knee osteoarthritis with PRP and hyaluronic acid in 120 patients and showed significantly better results in the patients treated with PRP. Because no severe adverse events were observed by the investigators, the application of autologous PRP was reported as an effective and safe method for the treatment of the initial stages of knee osteoarthritis.²⁸ The study by Sampson et al²⁹ presented improved function and reduced pain in 14 patients with knee OA 12 months after treatment with PRP injections. Just as with most synovial joints, the knee joint is covered by hyaline cartilage, in which the major collagen species is type II collagen synthesized by chondrocytes. However, the TMJ has a unique structure, in which the articular surfaces are covered by fibrocartilage that is nearly

acellular, with a very tiny volume of chondrocyte-like and fibroblast-like cells. Also, the major collagen species is type I collagen, which is primarily formed by fibroblast-like cells.^{30,31} Therefore, the most important aspect of our study was the investigation of the effects of PRP in the treatment of degenerative TMJ-OA for the first time.

The rationale for the use of PRP was that a great amount of GFs are released from the activated platelets.³² Working synergistically, these biologically active proteins stimulate the proliferation and differentiation of fibroblasts, osteoblasts, chondrocytes, and mesenchymal stem cells.³³ Previous studies have investigated the role of various GFs in chondrogenesis. Takafuji et al¹⁸ showed the therapeutic usefulness of fibroblast GF-2

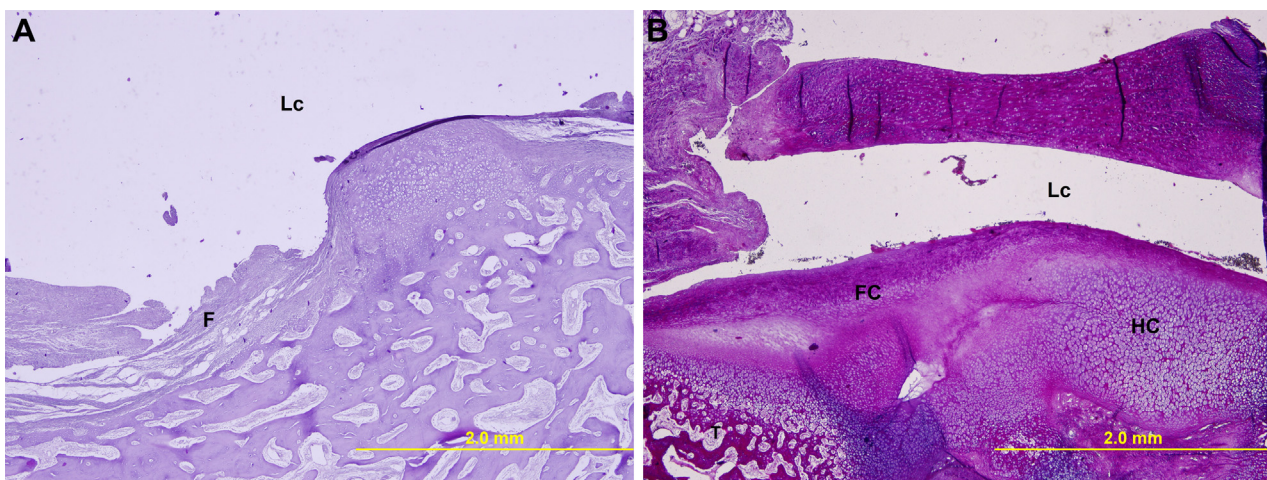


FIGURE 5. Histologic appearance of specimens from PRP- and saline-treated groups. *A*, An irregular outline of the condylar surface owing to increased fibrosis, a reduction in mature hyaline cartilage, and thinner and disorganized fibrocartilage was a typical appearance for the control group. The defect was not filled with tissue in some areas (original magnification $\times 4$). *F*, fibrosis; *Lc*, Lower compartment. *B*, The repair tissue consisted of hyaline cartilage (*HC*), fibrocartilage (*FC*), and bone trabecules (*T*). *HC* and *FC* were thicker in the PRP group. The defect was filled with tissue, with the fibrocartilage forming the superior layer, similar to that of the intact controls (original magnification $\times 4$). *Lc*, lower compartment.

Kütük et al. Effect of PRP on TMJ Repair. J Oral Maxillofac Surg 2014.

Table 1. RATIO OF FIBROCARILAGE, HYALINE CARILAGE, CONNECTIVE TISSUE, AND BONE IN PRP AND CONTROL GROUPS

Group	Parameter (%)			
	FC	HC	CT	B
PRP (n = 10)	49.72 (29.27-56.19)	27.25 (15.52-34.26)	25.70 (10.92-39.24)	0.87 (0.26-1.43)
Control (n = 10)	31.6 (26.68-44.08)	19.63 (11.82-41.32)	35.87 (24.98-56.58)	0.04 (0-0.19)
<i>P</i> value	.143	.579	.143	.011*

Data presented as median (minimum to maximum).

Abbreviations: B, bone; CT, connective tissue; FC, fibrocartilage; HC, hyaline cartilage.

* $P < .05$.

Kütük et al. *Effect of PRP on TMJ Repair: J Oral Maxillofac Surg* 2014.

in the treatment of articular cartilage defects in rabbit TMJs. In another study, Liu et al¹¹ reported that IGF-1 improved the repair of cartilage and subchondral cancellous bone when suspended in HA in TMJ-OA. TGF- β was also shown to effect chondrocyte metabolism.²⁴ Nevertheless, an increasing number of published studies have reported that the use of GFs in combination is needed to achieve proper chondrogenesis. Loeser et al³³ have shown that the use of IGF-1 and osteogenic protein 1, together, enhanced chondrogenesis. Using proinflammatory cytokine-induced arthritic chondrocytes, Wu et al³⁴ showed that PRP, in which greater concentrations of GFs are present, plays a critical role in regulating cell proliferation, chondrogenic and inflammatory gene expression, and matrix remodeling of human articular chondrocytes. In the present study, however, the healing of fibrocartilage and hyaline cartilage was not significantly greater in the PRP group than in the control group. However, the experimental defects represented severe degenerative changes in TMJ-OA. Therefore, 1 of the drawbacks of our study was that we could not show the effects of PRP in treating milder or moderate degenerative disease of the TMJ.

PRP not only improved cartilage regeneration, but also promoted hard tissue healing. This autogenous blood material leads to increased osteoblast activation, resulting in dense and mature bone. Bone grafting materials were shown to initiate a greater response for osteogenesis when mixed with PRP. A total of 15 patients were treated for sinus elevation and/or ridge augmentation using autologous PRP combined with freeze-dried bone allografting, and 32% of cases were considered to be clinically successful, demonstrating complete bone coverage of the implant, no mobility, and a normal radiographic appearance at 12 months postoperatively.³⁵ In the calvarial defects of diabetic rats, bone healing was found to be enhanced qualitatively and quantitatively when treated solely with PRP.³⁶ Also, PRP promoted wound healing and osseous regeneration in human third molar extraction sites.³⁷ The present study showed significantly increased bone regeneration in the defects

after treatment with PRP. Also, the defects tended to have been filled with connective tissue in the control group, but a composition of new bone, hyaline, and fibrocartilage similar to that of the intact controls was recognized in the PRP group.

Clinically, conservative methods such as medical treatment, occlusal splints, or restrictive therapies are used as the first step in the management of TMJ-OA, with quite efficient results. When they fail to relieve the pain and/or improve adequate jaw function, intra-articular injections are generally used as a minimally invasive treatment choice. Currently, HA injection into the joint space is one of the most favored methods of intra-articular applications in the management of TMJ-OA. HA has been shown to reduce the inflammatory reactions of the synovial membrane, inhibit degenerative changes in the chondrocytes and cartilage matrix, and enhance the cartilage proteoglycan content.²⁸ However, it is controversial whether intra-articular HA injection modifies the progression of joint damage in OA and whether the treatment is beneficial or detrimental.²⁹ In the present study, because we induced TMJ-OA by creating surgical defects representing end-stage disease, it was not possible to evaluate the course of the inflammatory process when PRP was applied. However, no adverse effects were seen during the healing period with short-term follow-up.

In conclusion, our study has shown that PRP has potential beneficial effects on bone regeneration in experimentally induced severe degenerative changes of the TMJ in rabbits. Additional research evaluating its effects at the initial stages of TMJ-OA and the long-term results with functional outcomes is needed before clinical application.

Acknowledgements

The authors wish to thank Assistant Professor Ferhan Elmalı (Department of Biostatistics, Erciyes University Faculty of Medicine) for excellent assistance on the statistical analysis. The authors also wish to thank the Scientific and Technological Research Council of Turkey (TUBITAK) for their financial support of our project.

References

- Laskin DM, Grene CS, Hylander WL: Temporomandibular Disorders: An Evidence-Based Approach to Diagnosis and Treatment. Hanover Park, IL, Quintessence Publishing, 2006
- Dworkin SF, LeResche L: Research diagnostic criteria for temporomandibular disorders: review criteria, examinations and specifications, critique. *J Craniomandib Disord* 6:301, 1992
- Agerberg G, Inkapool I: Craniomandibular disorders in an urban Swedish population. *Craniomandib Disord Fac Oral Pain* 4:154, 1990
- Osterberg T, Carlsson GE: Symptoms and signs of mandibular dysfunction in 70 year old men and women in Gothenburg, Sweden. *Commun Dent Oral Epidemiol* 7:315, 1979
- Hochberg MC, Altman RD, Brandt KD, et al: Guidelines for the medical management of osteoarthritis. Part II. Osteoarthritis of the knee. American College of Rheumatology. *Arthritis Rheum* 38:1541, 1995
- George E: Intra-articular hyaluronan treatment for osteoarthritis. *Ann Rheum Dis* 57:637, 1998
- Papachristou G, Anagnostou S, Katsorhis T: The effect of intra-articular hydrocortisone injections on the articular cartilage of rabbits. *Acta Orthop Scand Suppl* 275:132, 1997
- Buckwalter JA, Mankin HJ: Articular cartilage. *J Bone Joint Surg* 79:600, 1997
- Safran MR, Seiber K: The evidence for surgical repair of articular cartilage in the knee. *J Am Acad Orthop Surg* 18:259, 2010
- Frazier A, Bunning RA, Thavarajah M, et al: Studies on type II collagen and aggrecan production in human articular chondrocytes in vitro and effects of transforming growth factor-beta and interleukin-1beta. *Osteoarthr Cartil* 2:235, 1994
- Liu XW, Hu J, Man C, et al: Insulin-like growth factor-1 suspended in hyaluronan improves cartilage and subchondral cancellous bone repair in osteoarthritis of temporomandibular joint. *Int J Oral Maxillofac Surg* 2:184, 2011
- Boswell SG, Cole BJ, Sundman EA, et al: Platelet-rich plasma: a milieu of bioactive factors. *Arthroscopy* 3:429, 2012
- Anitua E, Andia I, Ardanza B, et al: Autologous platelets as a source of proteins for healing and tissue regeneration. *Thromb Haemost* 91:4, 2004
- Pietrzak WS, Eppley BL: Platelet rich plasma: Biology and new technology. *J Craniofac Surg* 16:1043, 2005
- Eppley BL, Woodell JE, Higgins J: Platelet quantification and growth factor analysis from platelet-rich plasma: Implications for wound healing. *Plast Reconstr Surg* 114:1502, 2004
- Sampson S, Reed M, Silvers H, et al: Injection of platelet-rich plasma in patients with primary and secondary knee osteoarthritis: A pilot study. *Am J Phys Med Rehabil* 12:961, 2010
- Kon E, Buda R, Filardo G, et al: Platelet-rich plasma: intra-articular knee injections produced favorable results on degenerative cartilage lesions. *Knee Surg Sports Traumatol Arthrosc* 4: 472, 2010
- Takafuji H, Suzuki T, Okubo Y, et al: Regeneration of articular cartilage defects in the temporomandibular joint of rabbits by fibroblast growth factor-2: A pilot study. *Int J Oral Maxillofac Surg* 10: 934, 2007
- Larheim TA, Westesson PL, (eds): Maxillofacial Imaging. Berlin, Springer-Verlag, 2006
- Williams JM, Rayan V, Sumner DR, Thonar EJ: The use of intra-articular Na-hyaluronate as a potential chondroprotective device in experimentally induced acute articular cartilage injury and repair in rabbits. *J Orthop Res* 2:305, 2003
- Wang XD, Kou XX, He DQ, et al: Progression of cartilage degradation, bone resorption and pain in rat temporomandibular joint osteoarthritis induced by injection of iodoacetate. *PLoS One* 9: e45036, 2012
- Thompson RC Jr, Bassett CA: Histological observations on experimentally induced degeneration of articular cartilage. *J Bone Joint Surg Am* 3:435, 1970
- Filinte GT, Akan M, Bilgic I, et al: Chondrogenic effect of the perichondrium graft on the internal derangement and osteoarthritis of the temporomandibular joint of the rabbit. *J Craniomaxillofac Surg* 5:351, 2011
- Grimaud E, Heymann D, Rédini F: Recent advances in TGF-beta effects on chondrocyte metabolism: Potential therapeutic roles of TGF-beta in cartilage disorders. *Cytokine Growth Factor Rev* 13:241, 2002
- Hickey DG, Frenkel SR, Di Cesare PE: Clinical applications of growth factors for articular cartilage repair. *Am J Orthop* 32: 70, 2003
- Schmidt MB, Chen EH, Lynch SE: A review of the effects of insulin-like growth factor and platelet derived growth factor on in vivo cartilage healing and repair. *Osteoarthr Cartil* 14: 403, 2006
- Song SU, Hong YJ, Oh IS, et al: Regeneration of hyaline articular cartilage with irradiated transforming growth factor beta-1 producing fibroblasts. *Tissue Eng* 10:665, 2004
- Spakova T, Rosocha J, Lacko M, et al: Treatment of knee joint osteoarthritis with autologous platelet-rich plasma in comparison with hyaluronic acid. *Am J Phys Med Rehabil* 91:411, 2012
- Sampson S, Gerhardt M, Mandalaum B: Platelet rich plasma injection grafts for musculoskeletal injuries: A review. *Curr Rev Musculoskelet Med* 1:165, 2008
- Grinnell F, Lamke CR: Reorganization of hydrated collagen lattices by human skin fibroblasts. *J Cell Sci* 66:51, 1984
- Haskin CL, Milam SB, Cameron IL: Pathogenesis of degenerative joint disease in the human temporomandibular joint. *Crit Rev Oral Biol Med* 3:248, 1995
- Fortier LA, Barker JU, Strauss EJ, et al: The role of growth factors in cartilage repair. *Clin Orthop Relat Res* 10:2706, 2011
- Loeser RF, Pacione CA, Chubinskaya S: The combination of insulin-like growth factor 1 and osteogenic protein 1 promotes increased survival of and matrix synthesis by normal and osteoarthritic human articular chondrocytes. *Arthritis Rheum* 48: 2188, 2003
- Wu CC, Chen WH, Zao B, et al: Regenerative potentials of platelet-rich plasma enhanced by collagen in retrieving pro-inflammatory cytokine-inhibited chondrogenesis. *Biomaterials* 25:5847, 2011
- Kassolis JD, Rosen PS, Reynolds MA: Alveolar ridge and sinus augmentation utilizing platelet-rich plasma in combination with freeze-dried bone allograft: Case series. *J Periodontol* 10: 1654, 2000
- Mariano R, Messori M, de Moraes A, et al: Bone healing in critical-size defects treated with platelet-rich plasma: A histologic and histometric study in the calvaria of diabetic rat. *Oral Surg Oral Med Oral Pathol Oral Radiol Endod* 1:72, 2010
- Kaul RP, Godhi SS, Singh A: Autologous platelet rich plasma after third molar surgery: A comparative study. *J Maxillofac Oral Surg* 2:200, 2012