

Sudden post-traumatic sensorineural hearing loss reverted to normal by sneezing

SAGE Open Medical Case Reports
2: 2050313X14564774
© The Author(s) 2014
Reprints and permissions:
sagepub.co.uk/journalsPermissions.nav
DOI: 10.1177/2050313X14564774
sco.sagepub.com



Alper Yenigun

Abstract

An 11-year-old child with sudden post-traumatic sensorineural hearing loss regained his hearing functions after sneezing. This case report is a first in medical literature in describing recovery from hearing loss by sneezing. The therapeutic implications of this rare case deserve further investigation.

Keywords

Head trauma, child, hearing loss, sneezing

Date received: 14 July 2014; accepted: 27 November 2014

Introduction

Each year thousands of children are diagnosed with sensorineural hearing loss (SNHL). Various studies report the bilateral SNHL rate as 1.4–3 per 1000 live births.^{1,2} The etiology of hearing loss in children is reported as 50% genetic, 25% acquired, and 25% idiopathic.³ Hearing loss may present as a sequel of head injury, thus head traumas are cited among the acquired causes of hearing losses.^{4,5} Even minor head injuries may lead to hearing loss, especially of higher frequencies with an emphasis on 4000 Hz, but all hearing frequencies may be affected as well.⁴

Case report

This is a case report. Written informed consent was obtained from patient's parents, and our institution does not require ethics approval for reporting individual cases.

An 11-year-old male patient was referred to our clinic an hour after a ball hit his right ear. He complained of a 5-min long dizziness after the incident, and continuing tinnitus and hearing loss on his right ear. He did not have a previous history of hearing loss or any other ear problems. Otoscopic examination revealed that his tympanic membranes were intact and appeared normal on both sides. The Rinne test was negative on the right, and Weber test was lateralized to the left. The fistula test was negative. No nystagmus was present. The audiogram, otoacoustic emission test and auditory brainstem response test revealed severe SNHL on the right,

involving all frequencies (Figures 1 and 2). Tympanometry revealed increased compliance, with an Ad type tympanogram on the right (Figure 1). Temporal computed tomography (CT) did not reveal any pathologic findings (Figure 3).

The patient was hospitalized to be under close observation, and also for preparation for an exploratory tympanotomy. About 3–4 h after the trauma, the patient announced that his hearing reverted to normal after sneezing. Sneezing was spontaneous, without any apparent sneeze-inducing factors in the environment like strong odors, smoke, dust and abrupt temperature changes, and it was only one strong sneeze.

Control audiometry, otoacoustic emission test, auditory brainstem response test and tympanometry revealed normal findings on right ear (Figures 4 and 5). The patient was dismissed after scheduling an appointment for further follow-up. His hearing and ear examination was normal in the follow-up visit a week later.

Discussion

Head trauma is a worldwide health problem. Most head traumas involve minor injuries and do not require specific medical care, and recover without any sequels or symptoms. About

Otorhinolaryngology Clinic, Konya Hospital, Konya, Turkey

Corresponding Author:

Alper Yenigun, Otorhinolaryngology Clinic, Konya Hospital, Şemsi Tebrizi Mah. Şerafettin Cd. No: 95, 42080 Karatay, Konya, Turkey.
Email: alperyenigun@gmail.com



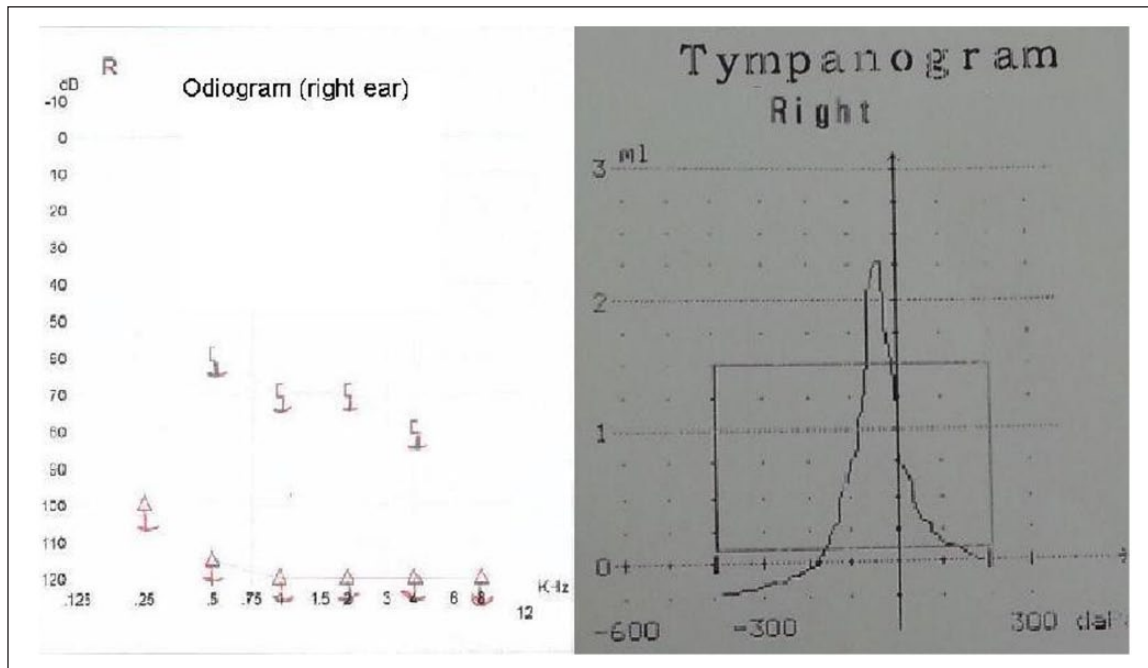


Figure 1. The audiogram and tympanogram after trauma.

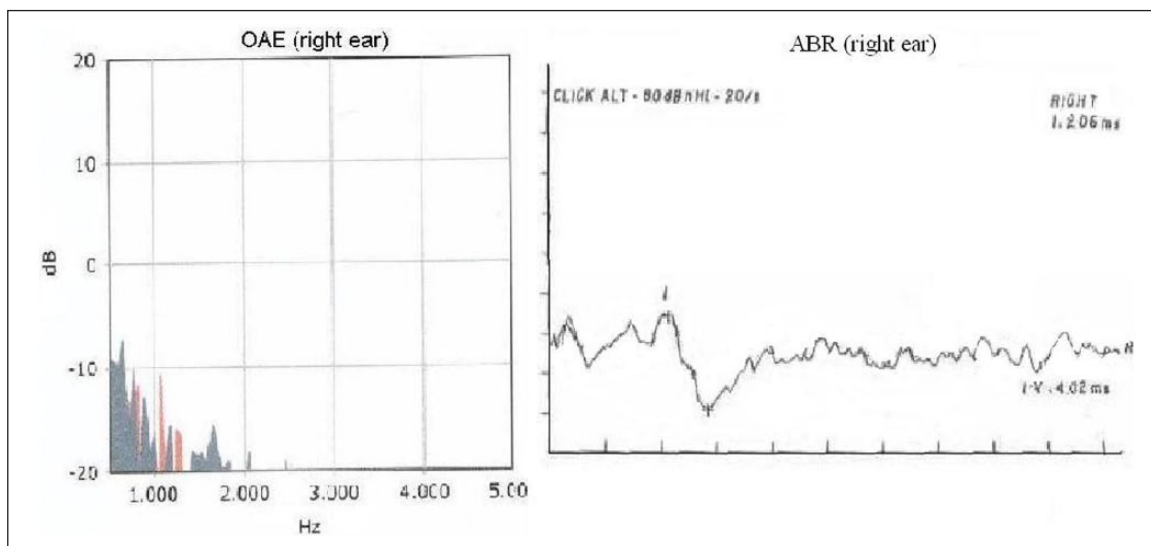


Figure 2. The otoacoustic emission test and auditory brainstem response test after trauma.

one-third of head trauma cases are cared only by emergency department physicians.⁶ Clinical studies have shown that with or without accompanying skull base fractures, head traumas could cause hearing loss.⁴ Transverse temporal bone fractures often lead to total and permanent hearing loss at the affected side. Conductive hearing loss following head traumas without fractures may resolve within 6 months.⁴ Hearing loss accompanying head trauma usually improves in the following month, although rarely, it can also progress to more severe forms.^{7,8}

Our patient did not have any fractures at the temporal bone due his head trauma, yet his audiogram and otoacoustic emission showed SNHL involving all frequencies. His tympanogram showed an Ad curve which points to increased compliance in the affected ear. According to the Jerger⁹ classification, the Ad curve is seen in ossicular chain discontinuity (Figure 1).

A sneeze or sternutation takes place when air expels from the lungs by passing through the nose and mouth. It is a semi-autonomous case which is usually caused by foreign particles irritating the nasal mucosa. This irritation of the nasal mucous

membrane¹⁰ mainly causes sneezing, which is an involuntary explosive and spasmodic action expelling by being forced by air from the mouth and nose. Sneezing can be associated with rapid changes (fall) in temperature, sudden exposure to bright light, cold air breeze, a pretty full stomach or viral infection, and may cause spreading of disease.

Sneezing serves to expel mucus containing irritants or foreign particles, and cleanse the nasal cavity. The soft palate and palatine uvula get lowered while sneezing and back side of the tongue elevates near to the passage from the mouth, so that air coming from the lungs becomes ready to expel through the nose. Since the closing of mouth is partial, a significant amount of this air is generally expelled from the

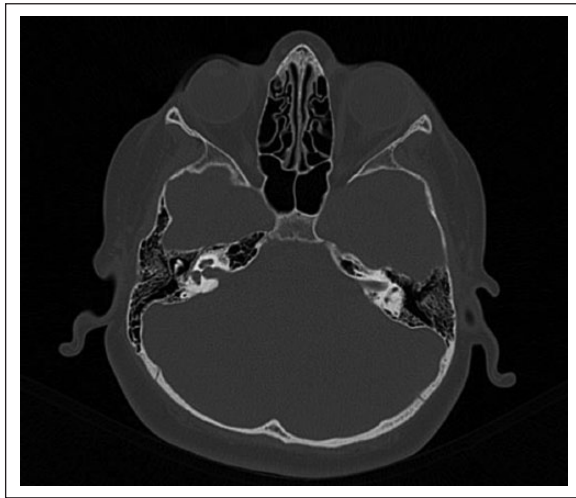

Figure 3. Temporal bone CT.

mouth. Expulsion of the air through the nose varies in terms of force and extent.

In their patient who developed sudden conductive hearing loss after sneezing, Azem and Caldarelli¹¹ found a stapedial fracture in their exploratory surgery and performed a stapedectomy; 6 months later, the patient's hearing reverted to normal. Bonfils et al.¹⁰ reported a case who, while on antihistamine therapy, experienced otalgia and sudden hearing loss in his left ear, following repeated sneezing. The authors explained hearing loss by the micro fractures on the posterior wall of the external ear. Sneezing, when suppressed, can also disrupt inner ear functions. Whitehead E.¹² performed exploratory tympanotomy on three patients with sudden SNHL, due to a suppressed sneeze in two of them, and due to exertion during birth in the third. He found stapedial fractures in all his cases, and also a perilymph fistula in two of them. Schuknecht H.F. and Witt R.L.¹³ also reported two cases with hearing loss and vestibular symptoms due to inner ear damage caused by suppressed sneezing. The authors proposed that the increased pressure, transmitted through the Eustachian tube (ET), might have damaged the round or oval windows, thus affecting the inner ear.

In the middle ear (ME) homeostasis, the ET can perform the following functions: Ventilation of the ME, and draining and clearance of secretions generated in the ME into the nasopharynx, equalize the pressure in the ME with atmospheric pressure and protect the ME from nasopharyngeal sound and secretions. Since cartilage and surrounding tissues have elastic properties, the ET is collapsed normally. Temporary openings can be caused by both voluntary and involuntary actions such as swallowing, yawning, sneezing and shouting.¹⁴

In our case, hearing loss was caused by a head trauma and reverted to normal after one sneeze a couple of hours after the

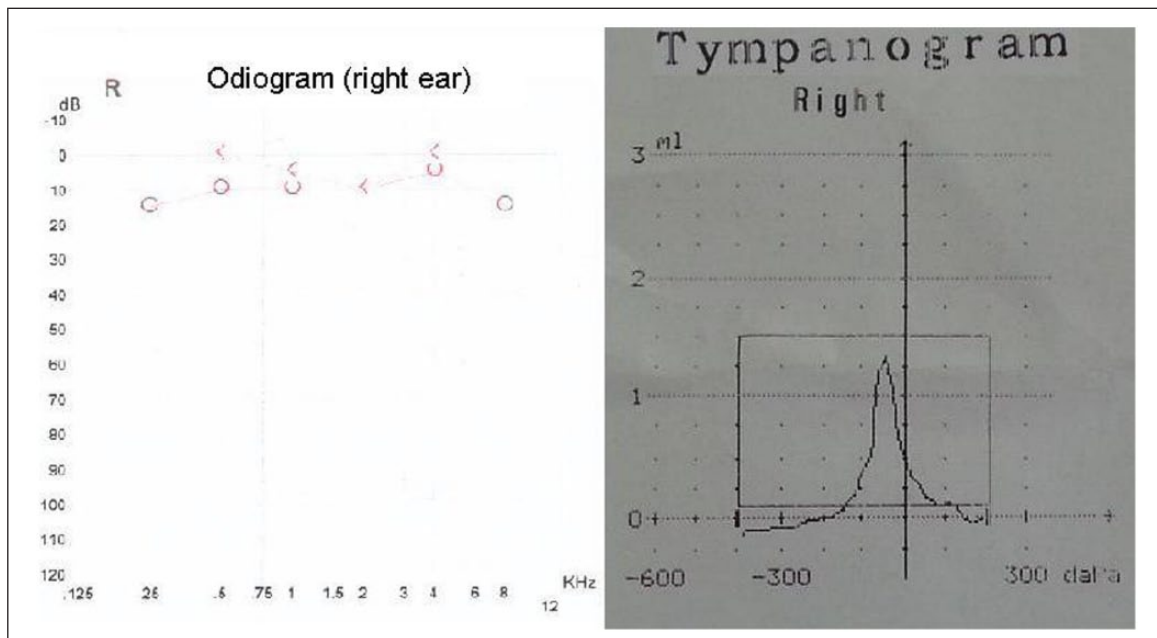


Figure 4. The audiogram and tympanogram after sneezing.

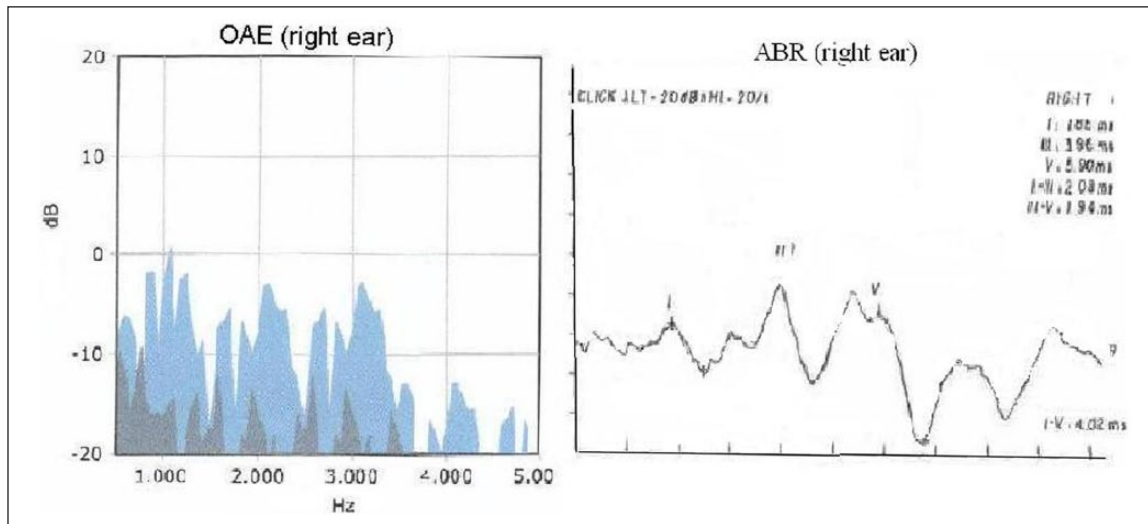


Figure 5. The otoacoustic emission test and auditory brainstem response test after sneezing.

hearing loss, and both the hearing loss and the sudden recovery were confirmed by audiograms, otoacoustic emission test and auditory brainstem response test, the later audiogram showing improvements at all frequencies. The tympanogram curve, which presented an Ad configuration according to the Jerger classification⁶ during the hearing loss, changed to an A configuration with recovery, which showed that compliance of the affected ear returned to normal (Figures 4 and 5). The sudden pressure change brought forward by sneezing with the accompanying opening of the ET, when transmitted to the ME, might have relocated any probable dislocation of the ossicles or might have reverted a probable pathology at the base of the stapes, and may account for the return of hearing. This is an interesting case, and may have significant therapeutic implications if the mechanisms of hearing recovery by sneezing or any other pressure change are elucidated by detailed studies. The main limitation of our report is the lack of CT image, including potentially key structures such as stapes footplate subluxation, modiolus dysplasia or enlarged vestibular aqueduct, and posterior or superior canal dehiscence.

Conclusion

The effects of sneezing on the ME and the ossicles are not well known. In contrast with various articles in medical literature reporting hearing loss after sneezing, our case regained his hearing after one sneeze. Our article is a first in reporting hearing gain after sneezing. The therapeutic implications of this rare case deserve further investigation.

Declaration of conflicting interests

The authors declare that there is no conflict of interest.

Funding

This research received no specific grant from any funding agency in the public, commercial, or not-for-profit sectors.

References

- Mason JA and Herrmann KR. Universal infant hearing screening by automated auditory brainstem response measurement. *Pediatrics* 1998; 101: 221–228.
- Hone SW and Smith RJH. Medical evaluation of pediatric hearing loss: laboratory, radiographic and genetic testing. *Otolaryngol Clin North Am* 2002; 35: 751–764.
- Marres HA. Congenital abnormalities of the inner ear. In: Ludman H and Wright T (eds) *Diseases of the ear*. Bath: Arnold and Oxford University Press, 1998, pp. 288–296.
- Bergemalm OP and Borg E. Long-term objective and subjective audiologic consequences of closed head injury. *Acta Otolaryngol* 2001; 121: 724–734.
- Heid L, Claussen CF, Kersebaum M, et al. Vertigo, dizziness and tinnitus after otobasal fractures. *Int Tinnitus J* 2004; 10: 94–100.
- Møllergaard P and Mathiesen T. Head injuries. In: Møllergaard P and Mathiesen T (eds) *Basic neurosurgery*. Lund: Studentlitteratur, 1998, pp. 189–206.
- Grove WE. Hearing impairment due to craniocerebral trauma. *Ann Otol Rhinol Laryngol* 1947; 56: 264–270.
- Tos M. Prognosis of hearing loss in temporal bone fractures. *J Laryngol Otol* 1971; 85: 147–159.
- Jerger J. Clinical experience with impedance audiometry. *Arch Otolaryngol* 1970; 92: 311–324.
- Bonfils P, Laccourreye O, Durand FX, et al. Sudden deafness following a sternutatory attack. *Eur Ann Otorhinolaryngol Head Neck Dis* 2011; 128: 103–105.
- Azem K and Caldarelli DD. Sudden conductive hearing loss following sneezing. *Arch Otolaryngol* 1973; 97: 413–414.
- Whitehead E. Sudden sensorineural hearing loss with fracture of the stapes footplate following sneezing and parturition. *Clin Otolaryngol Allied Sci* 1999; 24: 462–464.
- Schuknecht HF and Witt RL. Suppressed sneezing as a cause of hearing loss and vertigo. *Am J Otolaryngol* 1985; 6: 468–470.
- Bunne M, Falk B, Magnuson B, et al. Variability of Eustachian tube function: comparison of ears with retraction disease and normal middle ears. *Laryngoscope* 2000; 110: 1389–1395.