

Evaluation of amblyopic eyes with optical coherence tomography angiography and electrophysiological tests

Mualla Hamurcu, Cansu Ekinci¹, Semra Koca², Betül Tugcu¹

Purpose: To investigate the structural and functional changes of the retina and optic nerve in amblyopia. **Methods:** Eighteen patients with unilateral anisometropic amblyopia and 27 age-matched healthy controls were involved in this study. All patients underwent optical coherence tomography angiography (OCTA), pattern visual evoked potential (pVEP), and flash electroretinogram (fERG). **Results:** There was no statistically significant difference in terms of the foveal avascular zone (FAZ), perifoveal superficial density, whole superficial density, parafoveal deep density, perifoveal deep density among the eyes ($P > 0.05$). Significant differences were found only in superficial capillary plexus (SCP) vessel density in whole ($P = 0.029$) and parafoveal ($P = 0.008$) image. In electrophysiological tests, while VEP latencies of the amblyopic eyes increased compared to nonamblyopic eyes and controls ($P = 0.027$), VEP amplitudes decreased in amblyopic and nonamblyopic eyes compared to controls ($P = 0.01$), amplitudes of the rod ($P = 0.027$) and cones ($P < 0.001$) also decreased in amblyopic eyes compared to nonamblyopic and healthy eyes. When we assessed the correlation between the parameters of OCTA and electrophysiological test, only a significant correlation was found between parafoveal SCP vessel density and VEP amplitudes ($r = 0.341$). **Conclusion:** We found a significant decrease only in SCP vessel density of the OCTA parameters in amblyopic eyes compared to healthy eyes. We detected a significant relationship between parafoveal SCP vessel density and VEP parameters, which might be associated with the underlying pathophysiology of the amblyopia.

Key words: Amblyopia, electroretinography, optical coherence tomographic angiography, retina, visual evoked potential

Amblyopia is the reduction of visual acuity in mostly one eye or both eyes despite normal structural findings. It is the most common visual impairment in children, with a worldwide prevalence of 1–4%.^[1] Although its pathophysiology is not yet accurately defined, it is accepted to be the result of abnormal binocular interaction and the lack of appropriate stimulation during visual development.^[2] The neuroanatomical changes of the visual pathway have been assessed in detail in various studies with conflicting results.^[3,4] Additionally, neurophysiological alterations of the visual pathway have been evaluated by visual evoked potential (VEP) in amblyopic subjects with different results.^[5,6]

Despite the consideration of cortical pathology in amblyopia, abnormalities of retinal ganglion cells have been reported in animal studies.^[7,8] Also, structural retinal changes have been observed using the optical coherence tomography (OCT) in subjects with amblyopia in several studies.^[9] Recently with the invention of optical coherence tomographic angiography (OCTA), the vasculature of the retina have been also assessed in amblyopic subjects in limited studies. OCTA

is a noninvasive modality that provides detailed evaluation of vasculature of the retina, which is crucial for its functions.^[10]

Electrophysiological tests provide an assessment of the visual pathway extending from the ganglion cells to the occipital cortex beyond the clinical examination. Pattern VEP is an important indicator of optic nerve functions evaluating the cortical response to a pattern stimulation. Retinal electrical potentials are measured with flash electroretinogram (fERG). Functional assessment of retina and the visual pathway has been also performed using electrophysiologic studies in various studies reporting variable results.^[5]

Retinal structure and function in amblyopia is a topic of broad interest, and previous studies identifying morphofunctional changes on this subject have inconclusive and controversial results. For these reasons, in this study, we aimed to investigate the microvasculature of retinal layers by using OCTA, a newly developed technique. Additionally, we evaluated retina and visual pathways functionally with electrophysiological tests in the unilateral amblyopic patients.

Access this article online

Website:

www.ijo.in

DOI:

10.4103/ijo.IJO_2319_19

Quick Response Code:



Department of Ophthalmology, Ankara City Hospital, Ankara, ¹Department of Ophthalmology, Bezmialem Vakıf University School of Medicine, Istanbul, ²Department of Ophthalmology, Denizli State Hospital, Denizli, Turkey

Correspondence to: Dr. Semra Koca, Department of Ophthalmology, Denizli State Hospital, Denizli, Turkey. E-mail: drsemrakara68@hotmail.com

Received: 17-Dec-2019

Revision: 28-Mar-2020

Accepted: 06-Jun-2020

Published: 15-Dec-2020

This is an open access journal, and articles are distributed under the terms of the Creative Commons Attribution-NonCommercial-ShareAlike 4.0 License, which allows others to remix, tweak, and build upon the work non-commercially, as long as appropriate credit is given and the new creations are licensed under the identical terms.

For reprints contact: WKHLRPMedknow_reprints@wolterskluwer.com

Cite this article as: Hamurcu M, Ekinci C, Koca S, Tugcu B. Evaluation of amblyopic eyes with optical coherence tomography angiography and electrophysiological tests. Indian J Ophthalmol 2021;69:105-10.

Methods

We prospectively examined 45 eyes of 45 (18 of which were amblyopic and 27 were control patients) patients. The study was approved by the ethics committee. The study was compliant with the principles of the Declaration of Helsinki. Informed consent was obtained from all participants.

The amblyopic group included patients with unilateral anisometropic amblyopia. Patients with histories of preterm birth, severe amblyopia, neurological diseases or ocular diseases such as glaucoma or nystagmus, systemic diseases that may affect the eye and visual functions such as diabetes mellitus, subjects who were too young or old to cooperate, inability to fixate, history of previous intraocular surgery or laser therapy were excluded from this study.

All patients and healthy volunteers underwent a complete ophthalmic and orthoptic examination. Best-corrected visual acuity was measured with a Snellen chart at 6 m. Visual acuity readings were transformed to a logarithmic scale (logMAR) for statistical analysis. Fixation behavior was evaluated by having the patient fixate on an accommodative target held at 40 cm with the best correction in place. Only patients with central, steady, and maintained fixation were included in the study. Pattern VEP and fERG tests, and OCT examination were performed by the same examiner for all participants.

Unilateral amblyopia was defined as a difference of at least two lines on the acuity chart between the amblyopic and the nonamblyopic eyes. The visual acuity of the nonamblyopic eye of the study group was 0.00 logMAR. Unilateral amblyopia was defined as a difference of at least 0.1 logMAR between the two eyes. Anisometropia was diagnosed in those patients whose spherical equivalence showed 1.5 diopters (D) or greater. All the tests were performed in different sessions.

The results were analyzed using the Statistical Package for the Social Sciences (SPSS) statistical software (version 21.0 for Windows; SPSS, Inc. Chicago, IL, USA). In addition to standard descriptive statistical calculations (mean and standard deviation). Statistical analysis for the comparison of parameters among the amblyopic, nonamblyopic, and control eyes was performed using the analysis of variance (ANOVA) test. Unpaired t-test and Chi-square test were performed during the evaluation of qualitative data. Bonferonni correction was used to control for false positives. The correlation analyses were evaluated on the basis of the Pearson correlation coefficient. Pearson correlation coefficient value of $P \leq 0.05$ was considered statistically significant.

Optical coherence tomography angiography

Acquisition and analysis of images

All eyes were imaged with The AngioVue Imaging System (RTVue XR Avanti; Optovue, Inc. Fremont, CA) by the same experienced examiner. The AngioVue Imaging System is a spectral-domain optical coherence tomography device that enables simultaneous three-dimensional structural imaging of the retina and generation of en face maps of blood flow through a split-spectrum amplitude-decorrelation angiography algorithm.^[2] The AngioAnalytics software allows the measurement of the foveal avascular zone (FAZ) and retinal vessel density from selected regions of the retina. Qualitative analysis such as FAZ area and retinal vessel density in the

superficial capillary plexus (SCP) and deep capillary plexus were evaluated in OCTA images of the macula. OCTA scan size of 6×6 mm was chosen for our purposes. For all measurements, automatic segmentation was used to identify retinal layers. Hereby, the upper border of the superficial vascular layer was defined as the internal limiting membrane offset and the lower border as $9 \mu\text{m}$ below the inner plexiform layer. For the deep vascular layer, the borders were defined as $9 \mu\text{m}$ below the inner plexiform layer and $9 \mu\text{m}$ upper the outer plexiform layer. The FAZ area was measured using AngioVue software using a slab from the internal limiting membrane offset to the outer plexiform layer offset. The OCTA characterizes vascular information at each retinal layer as an en face angiogram, a vessel density map, and quantitatively as vessel density (%), calculated as the percentage area occupied by flowing blood vessels in the selected region. The vessel density was calculated in the whole 6×6 mm image, parafovea (outside of 1×1 mm circle centered on the fovea) and perifovea (outside of 3×3 mm circle centered on the fovea) in SCP and deep capillary plexus. Poor quality OCT angiograms due to blinking (appearing as straight, white stripes), or fixation loss, were excluded from the evaluation.

Visual evoked potential and electroretinogram

In accordance to the International Society for Clinical Electrophysiology of Vision (ISCEV) standards, the patients were tested by Metrovision brand monpack model visual electrophysiology device for pattern VEP and fERG tests. Pattern VEP is made simultaneously, using high-contrast (80%) checkerboard stimuli subtending the 120-min visual arc (min arc).^[11] Retinal and visual pathway functions were assessed by fERG test.^[12] Rod response (25db) b wave amplitude (μV) and cone response b wave amplitude were compared. Hawlina Konec (HK) loop electrodes were used for electroretinogram (ERG) tests.

Results

A total of 45 (24 female, 21 male) patients were included in the study (18 in the amblyopic and 27 in the control group). The mean age was 22.75 ± 10 years [range 18–57] and 22.90 ± 11.2 years [range 18–57] in amblyopic and control groups, respectively. No difference in age and sex was detected between the groups. The mean visual acuity of the amblyopic eyes was $0.25 (\pm 0.16)$. The mean spheric equivalent is 3.08 ± 1.10 [range 1.0–5.25] in amblyopic eyes.

There was no statistically significant difference between the groups in terms of central macular thickness and choroidal thickness ($P = 0.242$; $P = 0.699$). When we evaluated OCTA findings, in terms of FAZ, superficial and deep capillary plexus vessel density in perifoveal and whole image, there was no statistically significant difference among the eyes ($P > 0.05$). We found a statistically significant decrease in whole SCP vessel density in amblyopic eyes compared with the healthy controls ($P = 0.029$). Vessel density in parafoveal SCP was also significantly decreased in the amblyopic eyes, comparing with the control eyes ($P = 0.008$). Additionally, the vessel density in perifoveal SCP was found to be lower in the amblyopic eyes compared with the control eyes, but this difference was not statistically significant ($P = 0.126$) [Table 1].

In electrophysiologic studies, VEP latencies of the amblyopic eyes were significantly higher compared to nonamblyopic

and healthy eyes ($P < 0.001$) [Figs. 1 and 2]. But there was no difference in VEP latencies between nonamblyopic and healthy eyes. However, there were significant differences in terms of VEP amplitudes among the eyes ($P < 0.001$). In fERG; rod ($P = 0.027$) and cone ($P < 0.001$) amplitudes were also statistically significantly reduced in amblyopic eyes compared to nonamblyopic and healthy eyes [Figs. 3-6]. Also, VEP amplitudes of the nonamblyopic eyes showed a statistically significant decrease compared to the control group ($P < 0.001$) [Table 2].

When we assessed the correlation between the visual acuity and electrophysiological tests, we found strong negative correlation with VEP latencies ($r = -0.394$, $P = 0.002$) and strong positive correlation with VEP, rod and cone amplitudes ($r = 0.794$, $r = 0.439$, $r = 0.557$). VEP p120 latencies were in negative correlation with VEP and cone amplitudes ($P < 0.001$). VEP amplitudes were in positive correlation with rod and cone amplitudes and parafoveal vessel density in SCP and in negative correlation with VEP latencies ($r = 0.364$, $r = 0.447$, $r = 0.341$, $r = -0.306$) ($P = 0.004$, $P = 0.000$, $P = 0.007$, $P = 0.017$).

Evaluating the correlation between visual acuity and OCTA findings revealed a positive correlation with the parafoveal SCP vessel density ($r = 0.271$). Examining the correlations among the OCTA parameters, we found that central macular thickness

was negatively correlated with vessel density in whole SCP, parafoveal SCP, perifoveal SCP, and FAZ ($r = -0.324$, $r = -0.340$, $r = -0.316$, $r = -0.578$). Vessel density in parafoveal SCP has also been in positive correlation with perifoveal SCP, and FAZ [Figs. 7 and 8]. We have not found any significant correlation between choroidal thickness and other parameters ($P > 0.05$). When we assessed the correlation between OCTA findings and electrophysiological tests, we only found a strong positive correlation between parafoveal superficial capillary plexus vessel density and VEP amplitudes ($r = 0.341$) [Table 3].

Discussion

The evaluation of the macular vasculature in amblyopic subjects is a relatively new topic. In this study, we found no statistically significant difference between the amblyopic and fellow eyes in terms of FAZ area. While our result is consistent with the study of Yılmaz *et al.*^[13] and Lonngi *et al.*, Sobral *et al.* have found an increase in FAZ area of the deep capillary plexus in amblyopic eyes compared with the control eyes.^[1,14] However, we detected a significant decrease in vessel density of the whole and parafoveal SCP in amblyopic eyes compared to healthy eyes. The superficial vascular plexus is primarily in the ganglion cell layer and supplies inner retina comprising nerve fiber, ganglion cell, and inner plexiform layers. As reported

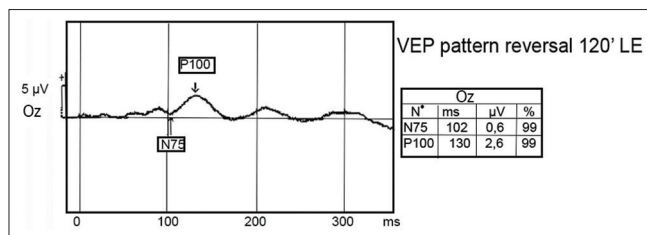


Figure 1: Visual evoked potential findings in an amblyopic eye

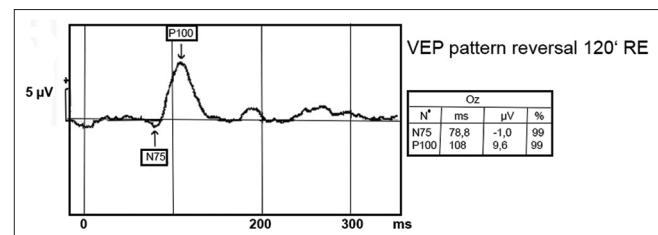


Figure 2: Visual evoked potential findings in a nonamblyopic eye

Table 1: Comparison of optical coherence tomography angiography parameters

Vessel density	Amblyopic eyes	Non-amblyopic eyes	Control	P		
				P1	P2	P3
Whole SCP	43.9±4.1	45.9±4.3	47.3±3.8	0.413	0.039	1.000
Parafoveal SCP	44.2±5.8	47.5±5.3	47.5±4.4	0.183	0.010	0.970
Perifoveal SCP	45±3.9	46.7±4.4	47.6±3.9	0.637	0.195	1.000
Whole DCP	47.7±5.2	46.2±5.5	47.4±5.1	1.000	1.000	1.000
Parafoveal DCP	55±4.4	53.2±5	52.7±4.9	0.734	0.386	1.000
Perifoveal DCP	48.3±6	47.1±6.5	47.1±5.6	1.000	1.000	1.000

DCP: Deep capillary plexus; P1: Amblyopia versus nonamblyopia; P2: Amblyopia versus control; P3: Nonamblyopia versus control; SCP: Superficial capillary plexus

Table 2: Comparison of electrophysiological tests among the eyes

Electrophysiological tests	Amblyopic eyes	Non-amblyopic eyes	Control	P		
				P1	P2	P3
VEP 120' min arc P 100 latency (ms)	106±6.4	100±6.4	103±6.4	<0.001	0.010	0.122
VEP 120' min arc P100 amplitude (μV)	3.85±1.3	7.02±1.2	10.59±2.1	0.122	0.001	<0.001
ERG rod response (25 db) b- wave amplitude (μV)	201±30.9	240±29.8	245±33.4	0.001	0.027	0.571
ERG cone response b-wave amplitude (μV)	72.82±4.9	88.57±9.1	90.52±8.5	0.002	<0.001	1.000

ERG: Electroretinogram; P1: Amblyopia versus nonamblyopia; P2: Amblyopia versus control; P3: Nonamblyopia versus control; VEP: Visual evoked potential

in the literature, decreased vessel density might be due to inadequate centrifugal inner retinal cell migration during visual development in amblyopic eyes.^[15,16] Additionally, in consistent with our study, Lonngi *et al.* have also found a significant decrease in vessel density in parafoveal rather than perifoveal

region between amblyopic and nonamblyopic eyes.^[11] As they mentioned, amblyopic changes may not be centrally located only in the fovea and this consequence is supported by the lack of difference in terms of FAZ area and central macular thickness

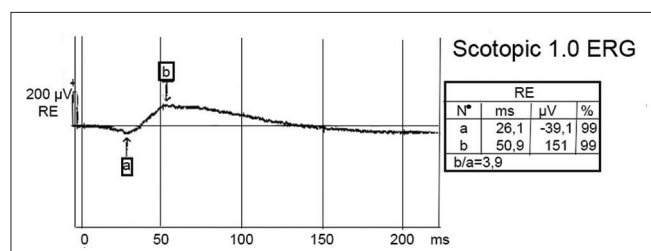


Figure 3: Electoretinogram rod response in an amblyopic eye

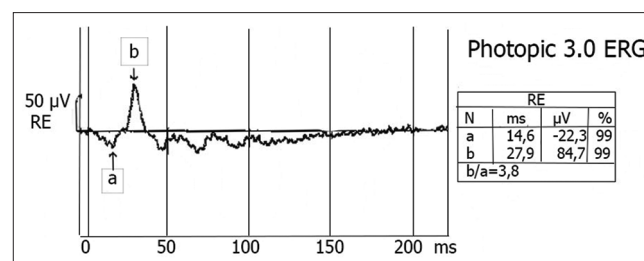


Figure 4: Electoretinogram cone response in an amblyopic eye

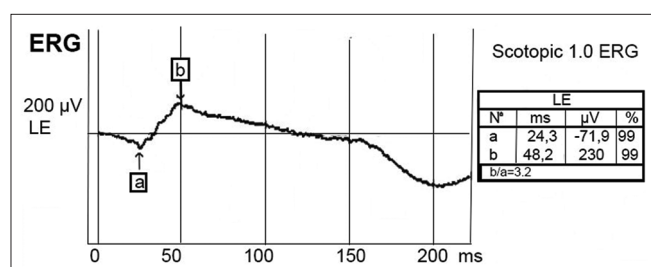


Figure 5: Electoretinogram rod response in a nonamblyopic eye

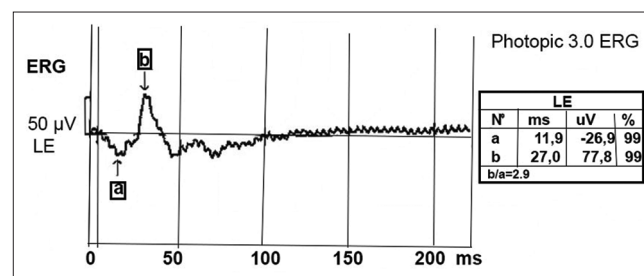


Figure 6: Electoretinogram cone response in a nonamblyopic eye

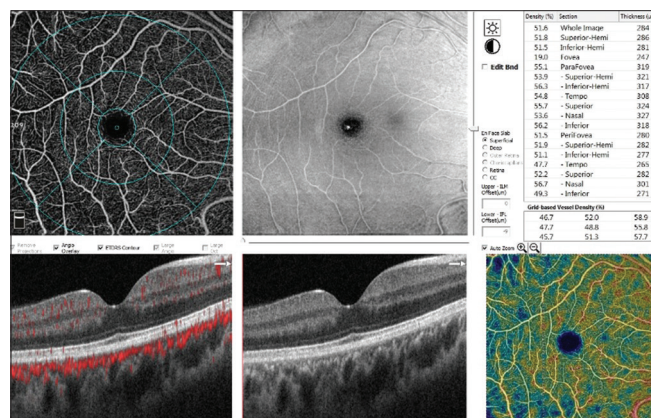


Figure 7: Normal vessel density in optical coherence tomography angiography (control group)

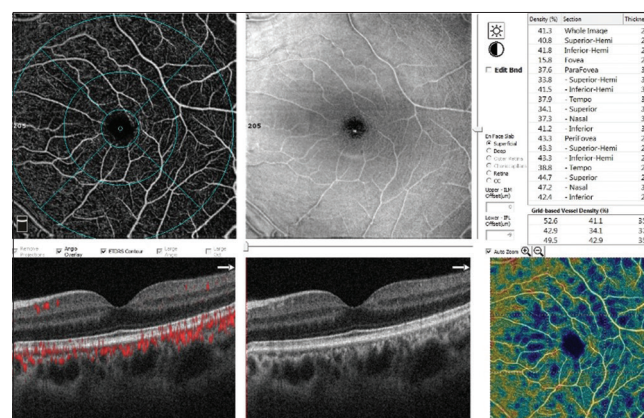


Figure 8: Optical coherence tomography angiography show decreased vessel density in an amblyopic eye

Table 3: Correlation coefficient values of electrophysiological tests and optical coherence tomography angiography parameters

Electrophysiological tests	Whole SCP	Parafoveal SCP	Perifoveal SCP	Whole DCP	Parafoveal DCP	Perifoveal DCP
VEP 120-min visual arc (min arc). P 100 latency	-0.173	-0.220	-0.219	0.079	0.070	0.046
P sig	0.183	0.088	0.099	0.545	0.591	0.732
VEP 120-min visual arc (min-arc) amplitude	0.311*	0.341**	0.234	0.052	-0.650	0.093
P sig	0.015	0.007	0.770	0.688	0.621	0.490
ERG rod response (25 db) b-wave amplitude	0.002	0.101	-0.025	-0.101	-0.191	-0.330
P sig	0.989	0.438	0.852	0.437	0.140	0.805
ERG cone response b-wave amplitude	0.161	0.176	0.141	0.016	-0.960	0.063
P sig	0.214	0.175	0.292	0.900	0.461	0.638

ERG: Electoretinogram; VEP: Visual evoked potential; SCP: Superficial capillary plexus; *Correlation is significant at the 0.05 level, DCP: Deep capillary plexus;

** Correlation is significant at the 0.01 level

between amblyopic and nonamblyopic eyes in their studies. However, comparing the nonamblyopic fellow eyes with the control eyes, we found no significant difference between the parameters. Contrarily, Sobral *et al.*^[14] found abnormal vascularization also in the fellow eyes of the amblyopic eyes, suggesting that development of both eyes is affected by the presence of bilateral amblyopia.

Ocular dominance columns in the striate cortex consist of 85% binocular and 15% monocular response cells. It has been demonstrated that monocular response cells and binocular response cells are decreased in number, laminar cells in the lateral geniculate nucleus are shrunk and visual response quality is decreased in the rest of the cells in subjects with amblyopia.^[17,18] The effect of these changes on visual response can be detected by electrophysiological tests. Consistent with our results, lower p100 amplitude and longer latency values have been also reported in all patterns of VEP in anisometropic amblyopia in literature.^[5,19,20]

There are conflicting results about fERG responses in amblyopia studies and these can be attributed to differences in study designs, electrophysiologic devices, and inclusion criteria of the patients.^[21,22] fERG is limited in the assessment of retinal ganglion cells and it is frequently used for the diagnosis of outer retinal diseases affecting photoreceptors and bipolar cells. Owing to the assessment of all retinal activity, it is not possible to detect functional loss affecting small retinal areas by using ERG. In clinical studies using full-field ERG, rod and cone responses have been demonstrated after birth.^[23] During the first 4 months, amplitudes of ERG increase rapidly and reach adult levels through to 1-year old.^[12] In our study, rod and cone amplitudes of fERG were found to be reduced in amblyopic eyes compared to fellow and healthy eyes. Based on these results, the low response of rods and cones might support the effect of amblyopia on retinal function and visual development.

The relationship between the structure and function of amblyopia is important because it can provide information on the extent of neural substrate and effect on visual function.^[9,24,25] In the literature, the relationship between visual field sensitivity and retinal thickness has been demonstrated.^[26] However, no significant relationship between the parameters of OCT and pattern ERG were found.^[9] Our study is so far the first to analyze the relationship between the vascular density and optic nerve and retinal functions using OCTA and electrophysiological studies, there is no correlation between the parameters of ERG and OCTA. We only found positive correlation between parafoveal SCP vessel density and VEP amplitudes. This might be due to abnormal retinal signaling originating from the fovea in amblyopia that affect the normal development of the visual pathway and cortical mapping.^[27]

Limitations of this study include the small sample size of the subjects, an excess of adult patients rather than pediatric patients, and comprising only anisometropic amblyopic patients. With future studies that are randomized, with larger numbers of subjects, and including other amblyopia types, more accurate results can be obtained.

Conclusion

In conclusion, this study evaluated the structural and functional differences between the anisometropic amblyopic and normal

subjects using OCTA and electrophysiological tests. We found only significant decrease in SCP vessel density of amblyopic eyes compared to healthy eyes. Also, a positive correlation between parafoveal SCP vessel density and VEP latencies might be suggestive for the abnormal visual development in amblyopia. Comprehensive studies would be useful to detect the underlying pathophysiology of amblyopia.

Financial support and sponsorship

Nil.

Conflicts of interest

There are no conflicts of interest.

References

1. Lonngi M, Velez FG, Tsui I, Davila JP, Rahimi M, Chan C, *et al.* Spectral domain optical coherence tomographic angiography in children with amblyopia. *JAMA Ophthalmol* 2017;35:1086-91.
2. Liu CH, Ong SJ, Huang CY, Wu WC, Kao LY, Yang ML. Macular thickness, foveal volume and choroidal thickness in amblyopic eyes and their relationships to the treatment outcome. *J Ophthalmol* 2018;6:1967621.
3. Hess RF. Amblyopia: Site unseen. *Clin Exp Optom* 2001;84:321-36.
4. Pineles SL, Demer JL. Bilateral abnormalities of optic nerve size and eye shape in unilateral amblyopia. *Am J Ophthalmol* 2009;148:551-7.
5. Hamurcu M, Çelik A, Sarıcaoğlu M, Bulut AK. Electrophysiologic evaluation of amblyopia. *Eye Care Vis* 2017;1:1-4.
6. Mendonça RHF, Abbruzzese S, Bagolini B, Nofroni I, Ferreira EL, Odom JV. Visual evoked potential importance in the complex mechanism of amblyopia. *Int Ophthalmol* 2013;33:515-9.
7. Sengpiel F. Plasticity of the visual cortex and treatment of amblyopia. *Curr Biol* 2014;24:936-40.
8. Ikeda H, Tremain KE. Amblyopia occurs in retinal ganglion cells in cats reared with convergent squint without alternating fixation. *Exp Brain Res* 1979;35:559-82.
9. Tugcu B, Araz-Ersan B, Kilic M, Erdogan ET, Yigit U, Karamursel S. The morphofunctional evaluation of retina in amblyopia. *Curr Eye Res* 2013;38:802-9.
10. Iafe NA, Phasukkijwatana N, Chen X, Sarraf D. Retinal capillary density and foveal avascular zone area are age-dependent: Quantitative analysis using optical coherence tomography angiography. *Invest Ophthalmol Vis Sci* 2016;57:5780-7.
11. Odom JV, Bach M, Brigell M, Holder GE, McCulloch DL, Mizota A, *et al.* ISCEV standard for clinical visual evoked potentials. *Doc Ophthalmol* 2016;133:1-9.
12. McCulloch DL, Marmor MF, Brigell MG, Hamilton R, Holder GE, Tzekov R, *et al.* ISCEV standard for full-field clinical electroretinography (2015 update). *Doc Ophthalmol* 2015;130:1-12.
13. Yilmaz I, Ocak OB, Yilmaz BS, Inal A, Gokyigit B, Taskapili M. Comparison of quantitative measurement of foveal avascular zone and macular vessel density in eyes of children with amblyopia and healthy controls: An optical coherence tomography angiography study. *JAAPOS* 2017;21:224-8.
14. Sobral I, Rodrigues TM, Soares M, Seara M, Monteiro M, Paiva C, *et al.* OCT angiography findings in children with amblyopia. *J Aapos* 2018;22:286-9.
15. Hendrickson AE, Yuodelis C. The morphological development of the human fovea. *Ophthalmology* 1984;91:603-12.
16. Maldonado RS, O'Connell RV, Sarin N, Freedman SF, Wallace DK, Cotten M, *et al.* Dynamics of human foveal development after premature birth. *Ophthalmology* 2011;118:2315-25.
17. Blakemore C, Van Sluyters RC. Innate and environmental

- factors in the development of the kitten's visual cortex. *J Physiol* 1975;248:663-716.
18. Hubel DH, Wiesel TN. Binocular interaction in striate cortex of kittens reared with artificial squint. *J Neurophysiol* 1965;28:1041-59.
 19. Heravian J, Ostadimoghadam H, Yekta AA, Hasanabadi H, Mahjoob M. Pattern VEP in response to monocular and binocular stimulation in normal and amblyope subjects. *Iran Red Crescent Med J* 2008;10:69-74.
 20. Sokol S. Pattern visual evoked potentials: Their use in pediatric ophthalmology. *Int Ophthalmol Clin* 1980;20:251-68.
 21. Wanger P, Persson HE. Oscillatory potentials, flash and pattern-reversal electroretinograms in Amblyopia. *Acta Ophthalmol* 1989;62:643-50.
 22. Slyshalova NN, Shamshinova AM. Retinal bioelectrical activity in amblyopia. *Vestn Oftalmol* 2008;124:32-6.
 23. Fishman GA, Birch DG, Holder GE, Brigell MG. Electrophysiologic Testing in Disorders of the Retina, Optic Nerve, and Visual Pathway, Second Edition (Ophthalmology Monographs). San Francisco: The Foundation of the American Academy of Ophthalmology; 2001;1-155.
 24. Tugcu B, Araz-Ersan B, Erdogan ET, Tarakcioglu H, Coskun C, Yigit U, *et al*. Structural and functional comparison of the persistent and resolved amblyopia. *Doc Ophthalmol* 2013;128:101-9.
 25. Bruse A, Pacey IE, Dharni P, Scally AJ, Barrett BT. Repeatability and reproducibility of macular thickness measurements using fourier domain optical coherence tomography. *Open Ophthalmol J* 2009;3:10-4.
 26. Kanamori A, Naka M, Nagai-Kusuhara A, Yamada Y, Nakamura M, Negi A. Regional relationship between retinal nerve fiber layer thickness and corresponding visual field sensitivity in glaucomatous eyes. *Arch Ophthalmol* 2008;126:1500-6.
 27. Baseler HA, Brewer AA, Sharpe LT, Morland AB, Jägle H, Wandell BA. Reorganization of human cortical maps caused by inherited photoreceptor abnormalities. *Nat Neurosci* 2002;5:364-70.