# Spreader Flap Correction of Dorsal Septal Deviations

Aesthetic Surgery Journal
2015, Vol 35(3) 345–348
© 2015 The American Society for Aesthetic Plastic Surgery, Inc.
Reprints and permission:
journals.permissions@oup.com
DOI: 10.1093/asj/sju048
www.aestheticsurgeryjournal.com
OXFORD UNIVERSITY PRESS

Caglayan Yagmur, MD; Osman Kelahmetoğlu, MD; and Hayati Akbaş, MD

A good rhinoplasty dissection is crucial to identify and release the vectoral forces on a deviated septum before correction.[1] Even after completing the dissection, dorsal hump reduction, septoplasty, and osteotomy, there may be persisting septal deviation. A number of techniques have been identified to correct various kinds of deviations that persist after release.

Cartilage grafts from the septum itself, or from other regions (concha or ribs), or alloplastic materials are used to correct the dorsum.[2] The spreader flap technique (so-called autospreader, turnover flap, or fold-in flap)[3] may also be used for this purpose. In this technique, the upper lateral cartilage is separated from the septum and folded medially and dorsally following meticulous dissection of the mucoperichondrial flaps. Longitudinal scoring of the dorsal side may be performed if needed. In this way, problems such as dysfunction of the internal nasal valve, asymmetry of the nasal sidewall, and inverted-V deformity can be solved in a more autologous fashion.[4] However, correction of dorsal deviations with caudal displacement, as an additional task, may also be achieved using spreader flaps.

## OPERATIVE DETAILS

In our practice, spreader flaps have been used to correct residual dorsal septal deviations with caudal displacements. This is possible by applying a "unilateral cephalocaudal spreader flap to septum suture." In this technique, a medially directed traction force is applied to the septum using the spreader flap on the opposite side (A video demonstrating the technique may be viewed at www.aestheticsurgeryjournal.com). Following dissection, a unilateral suture is introduced to the spreader flap cephalically and catches the septum caudally in an asymmetric horizontal mattress fashion (Figure 1). This maneuver draws the septum medially (Figure 2). We used 5-0 polyprolene (Prolene Ethicon) for suturing with a round or a cutting needle. After performing this unilateral procedure, both flaps were sutured together with the septum, first cephalically and then caudally.

## MY EXPERIENCE

Since July 2012, we have used this technique in 12 primary rhinoplasties (9 women, 3 men, age range: 21-38, mean age: 30.08) with external deviations, when a dorsal deviation with a caudal displacement persisted despite performing a complete dissection, dorsal hump reduction, septoplasty, and osteotomy. In all cases, we achieved immediate correction of the septum at the midline.

## OUTCOMES

We had good results with all 12 patients. Correction of external deviation while maintaining dorsal symmetry was achieved by this technique (Figure 3). The follow-up period was 10 months (range 3-12 months). None of the patients experienced internal nasal-valve dysfunction.

## COST

This procedure has no additional costs.

Dr Yagmur and Dr Akbas are plastic surgeons in private practice in Samsun, Turkey. Dr Kelahmetoğlu is a Plastic Surgeon in the Division of Plastic, Reconstructive, and Aesthetic Surgery, Tarsus State Hospital, Mersin, Turkey.

**Corresponding Author:**
Caglayan Yagmur, MD, FBM Aesthetic Plastic Surgery Clinic, Cumhuriyet mah, Ataturk Bulvari, No: 400, Atakum, Samsun, Turkey.
E-mail: caglayanyagmur@gmail.com

Downloaded from https://academic.oup.com/asj/article/35/3/345/200663 by Bezm-i Alem Universitesi user on 22 September 2025

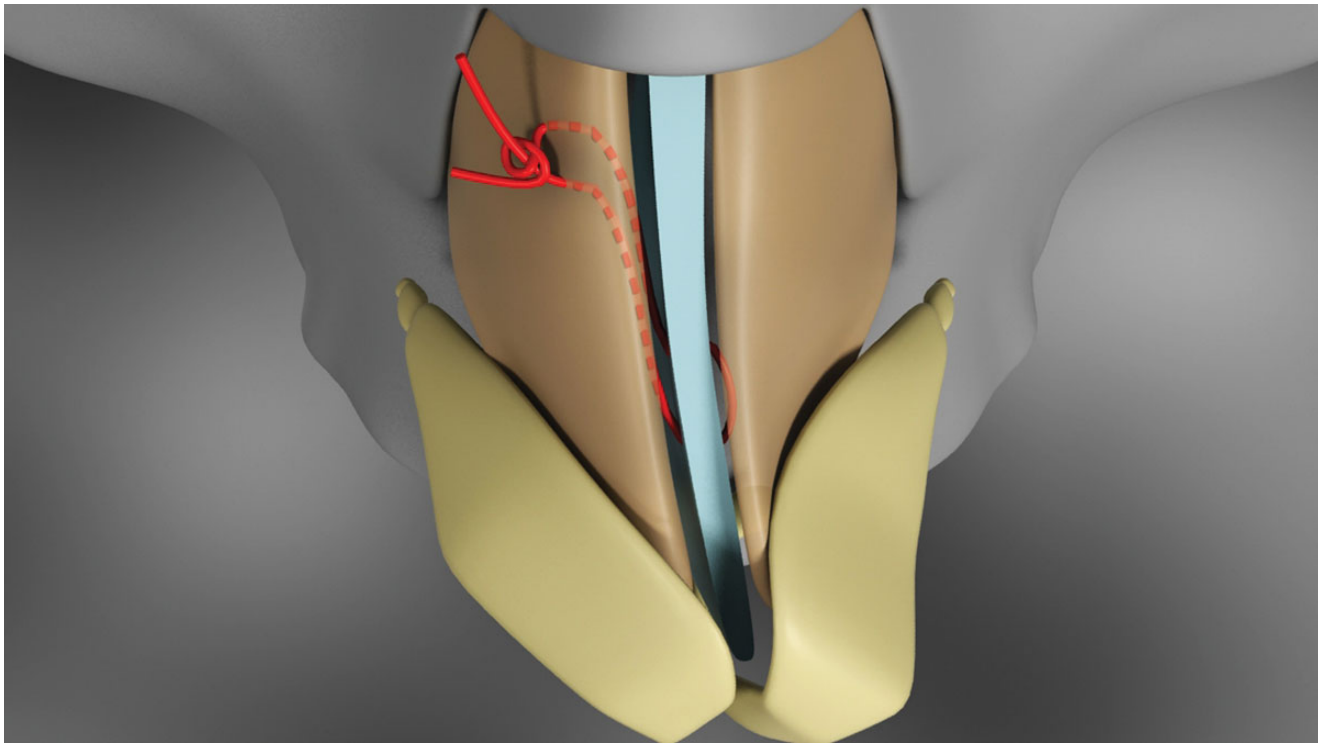

**Figure 1.** Spreader flap to septum suture in horizontal mattress fashion.

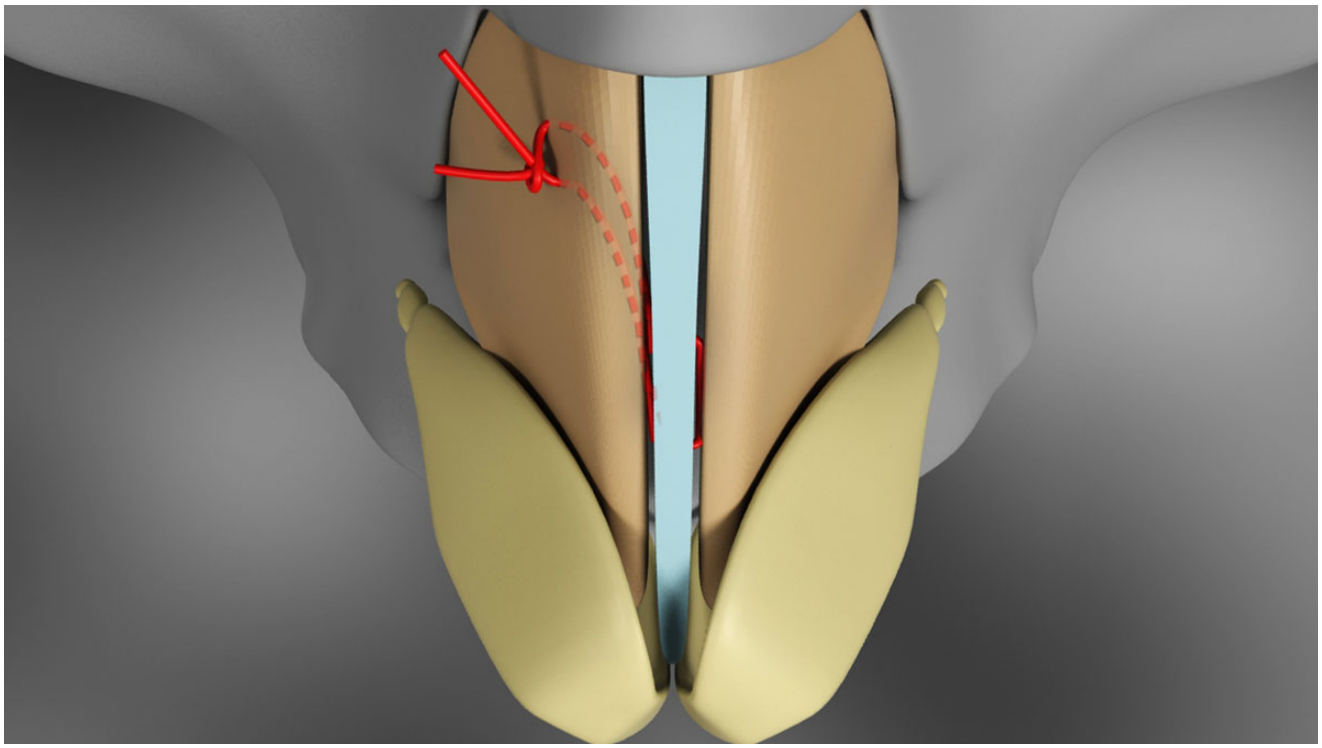

**Figure 2.** The suture is able to pull deviated caudal septum to midline.

Downloaded from https://academic.oup.com/asj/article/35/3/345/200663 by Bezm-i Alem Universitesi user on 22 September 2025

**Figure 3.** Preoperative (A, C) and 1-year postoperative (B, D) photographs of a 22-year-old woman. During the rhinoplasty operation a "unilateral cephalocaudal spreader flap to septum suture" was used to correct caudal deviation of septum.

Downloaded from https://academic.oup.com/asj/article/35/3/345/200663 by Bezm-i Alem Universitesi user on 22 September 2025

## CONCLUSIONS

The upper lateral cartilage linked to the nasal bones can transfer a correcting force to the deviated septum. As defined by Guyuron and Behmand, the "septal rotation suture" was first to use this principle. In that technique, the caudal septum, which remains deviated to one side after correction of the septal deviation and placement of septal extramucosal struts, is corrected by suturing upper lateral cartilages to septum.[5] However, besides being a confirmation of the original technique, practical use of "spreader flaps" for the same purpose provides a direct move that deals with more than one problem at the same time.

### Supplementary Material

This article contains supplementary material located online at www.aestheticsurgeryjournal.com.

### Acknowledgements

The authors thank Mr Özkan Ulusoy for his work on the figures and illustrations for this article.

### Disclosures

The authors declared no conflicts of interest with respect to the research, authorship, and publication of this article.

### Funding

The authors received no financial support for the research, authorship, and publication of this article.

## REFERENCES

1. Cerkes N. The Crooked Nose: Principles of Treatment. *Aesthet Surg J*. 2011;31:241-257.
2. Manavbaşi YI, Başaran I. The Role of Upper Lateral Cartilage in Dorsal Reconstruction After Hump Excision: Section 1. Spreader Flap Modification with Asymmetric Mattress Suture and Extension of the Spreading Effect by Cartilage Graft. *Aesth Plast Surg*. 2011;35:487-493.
3. Gruber RP, Park E, Newman J, Berkowitz L, Oneal R. The spreader flap in primary rhinoplasty. *Plast Reconstr Surg*. 2007;119:1903-1910.
4. Ozmen S, Ayhan S, Findikcioglu K, Kandal S, Atabay K. Upper lateral cartilage fold-in flap a combined spreader and/or splay graft effect without cartilage grafts. *Ann Plast Surg*. 2008;61:527-532.
5. Guyuron B, Behmand RA. Caudal Nasal Deviation. *Plast Reconstr Surg*. 2003;111:2249-2257.

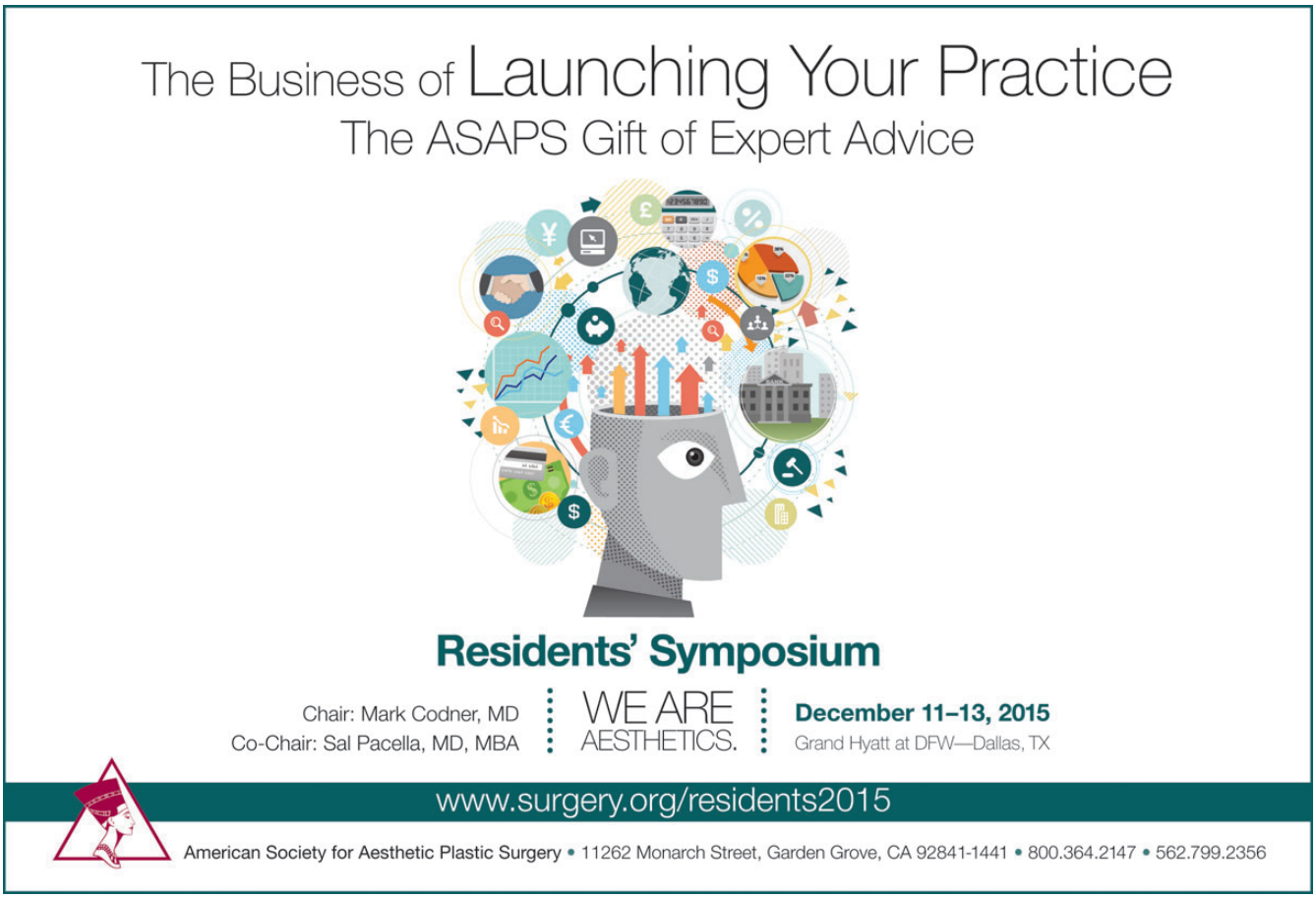


Downloaded from https://academic.oup.com/asj/article/35/3/345/200663 by Bezm-i Alem Universitesi user on 22 September 2025