



ELSEVIER

Contents lists available at ScienceDirect

## International Journal of Surgery Case Reports

journal homepage: [www.casereports.com](http://www.casereports.com)

# Chronic wrist pain in a goalkeeper; bilateral scaphoid stress fracture: A case report



Fevzi Saglam\*, Deniz Gulabi, Özgür Baysal, Halil İbrahim Bekler, Zeki Tasdemir,  
Nurzat Elmali

Dr. Lütfi Kırdar Kartal Training and Research Hospital, Kartal, Istanbul 34890, Turkey

## ARTICLE INFO

## Article history:

Received 22 October 2014

Received in revised form 1 December 2014

Accepted 18 December 2014

Available online 23 December 2014

## Keywords:

Chronic wrist pain

Scaphoid fracture

Scaphoid stress fracture

## ABSTRACT

**INTRODUCTION:** Bilateral scaphoid stress fractures are uncommon, and rarely presented with chronic wrist pain. Most fractures of the scaphoid heal with immobilization. Presentation of case The case presented here is of a bilateral stress fractures of the carpal scaphoid in a 19-year-old male. The patient had been playing as a goalkeeper and presented with a 4-year history of chronic pain in both wrists. We had a successful result in the treatment of these stress fractures with long-arm thumb plaster cast. Discussion Most fractures of the scaphoid in the immature skeleton heal with immobilization. Approximately 88–95% of acute scaphoid fractures are said to heal with conservative treatment using cast immobilisation. Non-surgical treatment is successful for scaphoid fractures in children and for those fractures which are non-displaced, stable, and where there is no damage to other bones or ligaments. In stable fractures, union is achieved within 8–12 weeks. Conclusion Bilateral stress fractures of the scaphoid can be considered for the wrist pain, especially for the patients that had repetitive minor wrist trauma, and in spite of developments in surgical techniques and materials used, treatment by plaster casting should still be considered initially for non-displaced, stable scaphoid stress fractures.

© 2014 The Authors. Published by Elsevier Ltd. on behalf of Surgical Associates Ltd. This is an open access article under the CC BY-NC-SA license (<http://creativecommons.org/licenses/by-nc-sa/4.0/>).

## 1. Introduction

There are various causes of wrist pain, such as osteoarthritis, De Quervain's disease, carpal tunnel syndrome, wrist ulnar nerve compression, trigger finger, Sudeck's atrophy, inflammatory arthritis, ganglion cysts. While there are many reasons causes of wrist pain, scaphoid stress fracture can also come to similar complaints rarely. The scaphoid is the most frequently fractured carpal bone, and approximately 1% of scaphoid fractures are bilateral [1,2].

Simultaneous occurrence of bilateral scaphoid fractures is even more rare. Most fractures of the scaphoid in the immature skeleton heal with immobilisation [3,4]. Approximately 88–95% of acute scaphoid fractures are said to heal with conservative treatment using cast immobilisation [5,6].

In the case presented here, it was aimed to present an unusual cause of chronic wrist pain due to the bilateral stress fractures of the scaphoid bone.

## 2. Case report

A 19-year-old boy presented with a 4-year history of mild pain and occasional swelling of both wrists especially after a physical activity. The patient had been working as an electrical technician, for the last 4 years and had been playing on a soccer team since the age of 15 years, usually practising for approximately 8 h per week. He played as a goalkeeper and he did not relate the onset of pain to any specific injury or blow. Initially, pain was only present during forced dorsiflexion. Thereafter, pain became almost continuous even without any movement.

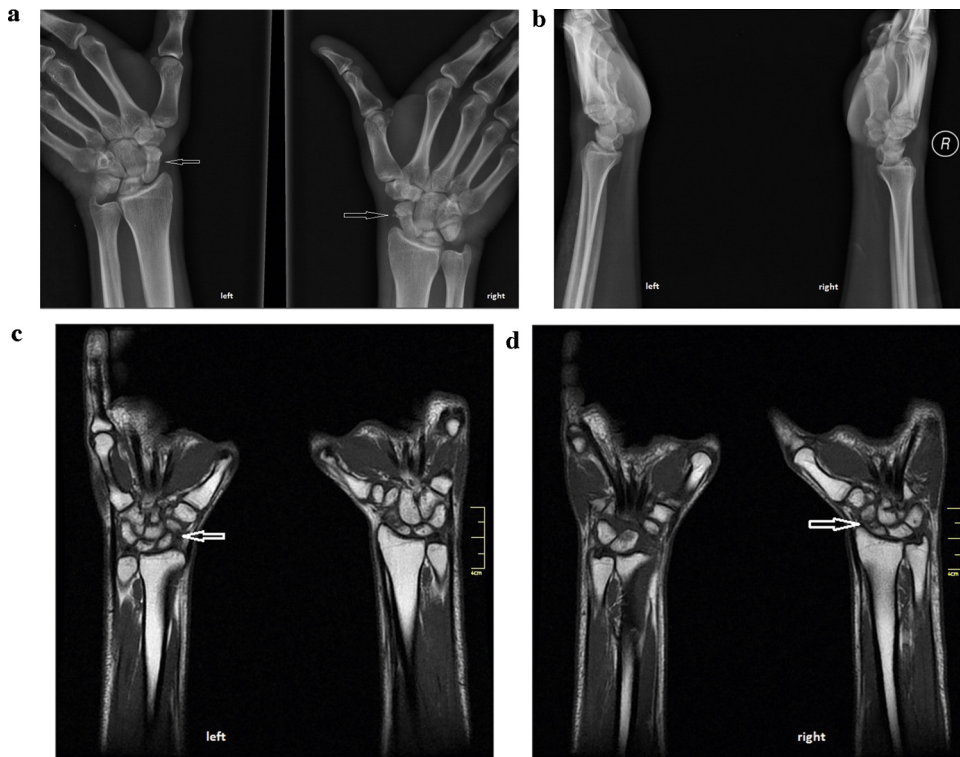
He presented at the orthopaedic polyclinic with complaints of pain in both wrists. The patient did not smoke. In the physical examination, the Watson test was positive in both wrists with sensitivity in both snuff boxes. Anteroposterior (AP), lateral and oblique radiographs were taken of both wrists. From the wrist radiographs, a diagnosis was made of Herbert B2 waist-type fracture in both scaphoids. The diagnosis was confirmed by computerised tomography and Magnetic resonance imaging (MRI) (Fig. 1a–d).

MRI was performed on both wrists so as to rule out other pathologies and to define the onset of fracture type (acute or chronic). There was no injury elsewhere in the body. For both scaphoid fractures, a short-arm thumb plaster cast was applied.

The patient was called for follow-up examinations at 2-week intervals at which radiographs were taken. Both scaphoid plaster

\* Corresponding author at: Semsi Denizer Cad. E5, Yanyol Cevizli Kavsagi, Kartal, Istanbul 34890, Turkey. Tel.: +90 216 4413900/1421/5455361461; fax: +90 216 3055110.

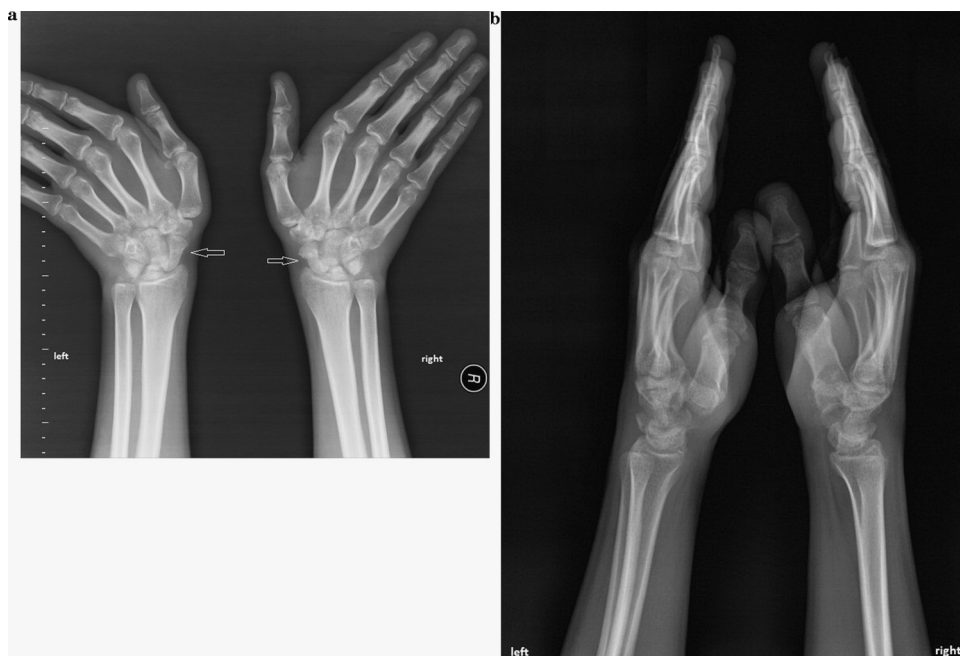E-mail address: [fvzisaglam@hotmail.com](mailto:fvzisaglam@hotmail.com) (F. Saglam).



**Fig. 1.** (a) Radiography of a bilateral stress fracture of the carpal scaphoid in a 19-year-old male; Anteroposterior radiography. (b) Radiography of a bilateral stress fracture of the carpal scaphoid in a 19-year-old male; Lateral radiography. (c) MRI of left carpal scaphoid stress fracture. (d) MRI of right carpal scaphoid stress fracture.

casts were removed in the 12th week and 3-way radiographs were evaluated for fracture union and whether or not there was transverse trabeculation (Fig. 2a and b). Full union was observed. In the definition of radiological union, the Dobyns and Linscheid measurements were used [7]. These measurements are that the distance between the fracture fragments is less than between the carpal bones, there is less sclerosis in the ends of the fracture than the

amount of subchondral sclerosis in the other carpal bones, there are no degenerative changes in the bone and the distance between the 2 fragments on the stress radiographs has not changed [8]. After removal of the plaster casts, wrist exercises were started. One month of physical rehabilitation, the patient had regained full range of motion and grip strength in the wrists and returned to full pre-injury activities. After 28 months of treatment with plaster cast,



**Fig. 2.** (a) Full union seen on radiographs after removal of the plaster casts in the 12th week; Anteroposterior radiography. (b) Full union seen on radiographs after removal of the plaster casts; Lateral radiography.

The Mayo clinic modified wrist evaluation scale was used for functional evaluation and the patient's final score was 85. He has been working as an electrical technician still.

### 3. Discussion

Stress fractures are caused by the repetitive application of a greater amount of force. This force causes an imbalance between the resorption and growth of bone, both of which go on all the time. Continued, repetitive force causes tiny cracks in fatigued bones. These cracks progress to become stress fractures. In this case, the patient presented with a stress fracture of both scaphoid bones secondary to repetitive dorsiflexed movements. Weber and Chao showed that the scaphoid was fractured under the pressure accumulated on the radial-palmar side while the wrist was in extension [9,10]. In the present case, the stress fracture of the scaphoid was due to the repetitive dorsiflexion forces of the wrist.

The treatment of scaphoid fractures is controversial [6]. Non-surgical treatment is successful for scaphoid fractures in children and for those fractures which are non-displaced, stable, and where there is no damage to other bones or ligaments. In stable fractures, union is achieved within 8–12 weeks [11]. However, long absence from work or sports with wrist stiffness, muscle weakness, that occurs with prolonged cast immobilisation, has led some authors to argue that even in undisplaced fractures, internal fixation is an efficient alternative especially in simultaneous bilateral cases. There are published studies which do not recommend conservative treatment for young and active patients [12]. In the case presented here, both treatment methods were explained to the patient and surgical treatment was recommended. However, the patient preferred to have conservative treatment. We had a successful result in the treatment of these stress fractures with long-arm thumb plaster cast.

In a study by Terkelsen and Jepsen, the incidence of non-union was not found to be greater in patients with a removable short-arm plaster cast than in patients treated with a long-arm thumb plaster cast [13]. In contrast, Gellman et al. reported that in patients to whom a long-arm thumb plaster cast was applied for 6 weeks from the beginning, union time was 3 months early [14]. Kaneshiro et al. showed a change of place of more than 3 mm of fracture fragments during pronation and supination in forearm short-arm thumb plaster casting in an experimental study where scaphoid fractures were created [15]. Long-arm thumb plaster casting was used for the case presented here. In a study by Singh et al., of 66 patients treated with below-the-elbow plaster cast for 8–12 weeks for scaphoid fracture, 22 cases of partial union and 14 cases of delayed union were reported from CT examination at 12–18 weeks [10]. In the case presented here, fracture union was observed on CT examination in the 12th week.

In conclusion it can be said that bilateral stress fractures of the scaphoid can be considered for the wrist pain, especially for the patients that had repetitive minor wrist trauma, and in spite of developments in surgical techniques and materials used, treatment by plaster casting should still be considered initially for non-displaced, stable scaphoid stress fractures.

### Conflicts of interest

None.

### Funding

None.

### Consent

Written informed consent was obtained from the patient for publication of this case report and accompanying images. A copy of the written consent is available for review by the Editor-in-Chief of this journal on request.

### Author contribution

The patient was under the care of Fevzi Saglam, Deniz Gulabi, and Zeki Tasdemir analyzed the data and infection markers. Fevzi Saglam and Özgür Baysal wrote the manuscript. Nurzat Elmali and Halil İbrahim Bekler made additions to the manuscript. All authors reviewed and approved the final manuscript.

### References

- [1] W.P. Cooney, J.H. Dobyns, R.L. Linscheid, Fractures of the scaphoid: a rational approach to management, *Clin. Orthop. Relat. Res.* 149 (1980) 90–97.
- [2] J.J. Dias, H.P. Singh, Displaced fracture of the waist of the scaphoid, *J. Bone Joint Surg. Br.* 93 (November (11)) (2011) 1433–1439.
- [3] H. Gellman, R.J. Caputo, V. Carter, A. Aboulafia, M. McKay, Comparison of short and long thumb-spica casts for non-displaced fractures of the carpal scaphoid, *J. Bone Joint Surg. Am.* 71 (1989) 354–357.
- [4] F.S. Haddad, N.J. Goddard, Acute percutaneous scaphoid fixation. A pilot study, *J. Bone Joint Surg.* 80-B (1998) 95–99.
- [5] R.J. Kulkarni, R. Wollstein, R. Taryar, N. Citron, Pattern of healing of scaphoid fractures: the importance of vascularity, *J. Bone Joint Surg.* 81-B (1999) 50–90.
- [6] S. Louis, D.J. Warwick, S. Nagayam, in: *Appley's System of Orthopaedics and Fractures*, 8th ed., Arnold, London, 2001, pp. 620–628.
- [7] M.M. McQueen, M.K. Gelbke, A. Wakefield, E.M. Will, C. Gaebler, Percutaneous screw fixation versus conservative treatment for fractures of the waist of the scaphoid: a prospective randomised study, *J. Bone Joint Surg. Br.* 90 (2008) 66–71.
- [8] H. Mussbichler, Injuries of the carpal scaphoid in children, *Acta Radiol.* 56 (1961) 361–368.
- [9] W.H. Seitz, R.F. Papandrea, Fractures and dislocations of the wrist, in: R.W. Bucholz, J.D. Heckman (Eds.), *Rockwood and Greens Fractures in Adults*, 5th ed., Lippincott Williams & Wilkins, Philadelphia, 2001, pp. 749–814.
- [10] J.F. Slade, J.N. Grauer, J.D. Mahoney, Arthroscopic reduction and percutaneous fixation of scaphoid fractures with a novel dorsal technique, *Orthop. Clin. North Am.* 32 (2001) 247–261.
- [11] C.J. Terkelsen, J.M. Jepsen, Treatment of scaphoid fractures with a removable cast, *Acta Orthop. Scand.* 59 (August (4)) (1988) 452–453.
- [12] V. Vahvnen, M. Westerlund, Fracture of the carpal scaphoid in children. A clinical and roentgenological study of 108 cases, *Acta Orthop. Scand.* 51 (1980) 909–913.
- [13] E.R. Weber, E.Y. Chao, An experimental approach to the mechanism of scaphoid waist fractures, *J. Hand Surg. Am.* 3 (1978) 142–148.
- [14] J. Wilson-MacDonald, Delayed union of the distal scaphoid in a child, *J. Hand Surg.* 12A (1987) 520–522.
- [15] W. Yinusa, O. Adetan, D.O. Odatuwa-Omagbemi, M.U. Eyo, Bilateral simultaneous fracture of the carpal scaphoid successfully treated with conservative cast immobilisation: a case report, *WJMJ* 29 (6) (2010) 425–428.

### Open Access

This article is published Open Access at [sciedirect.com](http://sciedirect.com). It is distributed under the [IJSCR Supplemental terms and conditions](#), which permits unrestricted non commercial use, distribution, and reproduction in any medium, provided the original authors and source are credited.