

Case Report

Rapid Tooth Movement and Orthodontic Treatment Using Dentoalveolar Distraction (DAD)

Long-term (5 years) Follow-up of a Class II Case

Gökmen Kurt^a; Haluk İşeri^b; Reha Kişnişci^c

ABSTRACT

The purpose of this report is to describe the dentoalveolar distraction (DAD) technique and to present its effects on the surrounding structures by presenting a Class II case. A 15-year-old skeletal and dental Class II female patient with an overjet of 9 mm was treated by DAD osteogenesis. A custom-made, rigid, tooth-borne intraoral distraction device was used for rapid canine retraction. Osteotomies surrounding the canines were made to achieve rapid movement of the canines within the dentoalveolar segment, in compliance with distraction osteogenesis principles. The amount of canine retraction was 7.5 mm in 12 days at a rate of 0.625 mm per day, with no posterior anchorage loss. The canine teeth showed 1.6 mm extrusion and 11 degrees inclination change (distal tipping) during the same period. Orthodontic treatment continued for 6 months with no clinical and radiographic evidence of complications such as root fracture, root resorption, ankylosis, and soft tissue dehiscence. The DAD technique is an innovative method, because it reduces overall orthodontic treatment time by about 50%, with no unfavorable effects on periodontal tissues and surrounding structures and with no need to use any intraoral or extraoral anchorage appliances. (*Angle Orthod.* 2010;80:597–606.)

KEY WORDS: Dentoalveolar distraction; Tooth movement; Rapid canine retraction

INTRODUCTION

Many orthodontic cases feature a shortage of space and some amount of crowding. During recent years, nonextraction procedures using extraoral or intraoral distalization techniques, including miniscrew and orthodontic implant supported distalization methods, have become popular. However, patients still require treatment based on tooth extraction.

The first phase of treatment in premolar extraction cases is distal movement of the canines. Biological

tooth movement with conventional techniques is limited.^{1,2} The retraction phase of the canine tooth into an extraction site usually lasts about 6 to 8 months, and under normal circumstances, conventional treatment with fixed appliances is likely to last about 20 to 24 months. In addition, retraction of the canines enhances the need for using extraoral or intraoral anchorage appliances when maximum or moderate anchorage is required. Duration of orthodontic treatment and use of extraoral anchorage mechanics are major complaints of orthodontic patients. Several methods that shorten orthodontic treatment time have been published in the orthodontic literature during past decades.^{3–10} In 1959, Köle⁷ presented a technique that combined orthodontics with “corticotomy” surgery to increase the rate of tooth movement. Davidovitch et al^{3,4} studied the effects of combined force and electrical currents on the rate of tooth movement and periodontal cyclic nucleotide levels. In 1998, Liou and Huang⁵ introduced the technique of distraction of the periodontal ligament for rapid tooth movement. In 2001, İşeri and Kişnişci^{11–14} introduced a new technique named dentoalveolar distraction (DAD), which achieves rapid tooth movement using the principles of distraction osteogenesis. This new technique offers

^a Assistant Professor and Department Chair, Department of Orthodontics, School of Dentistry, Erciyes University, Kayseri, Turkey.

^b Professor and Department Chair, Department of Orthodontics, School of Dentistry, Ankara University, Besevler, Ankara, Turkey.

^c Professor, Department of Maxillo-facial Surgery, School of Dentistry, Ankara University, Besevler, Ankara, Turkey.

Corresponding author: Dr Haluk İşeri, Professor and Department Chair, Department of Orthodontics, School of Dentistry, Ankara University, Besevler, Ankara, Turkey (e-mail: iseri@dentistry.ankara.edu.tr)

Accepted: October 2009. Submitted: April 2009.

© 2010 by The EH Angle Education and Research Foundation, Inc.

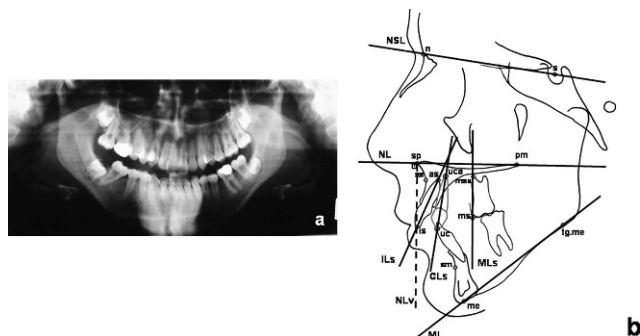


Figure 1. (a) Panoramic film before treatment. (b) Cephalometric reference points and lines.

patients shorter orthodontic treatment time and no use of any extraoral or intraoral anchorage appliance. In this case report, the DAD technique is introduced in a 5-year follow-up of a patient treated with DAD.

CASE REPORT

A 15-year-old Class II division 1 female patient with a 9-mm overjet and a 4-mm overbite was referred to the orthodontic department with the chief complaint of “protruded teeth.” The patient exhibited a mild amount of crowding of 2 mm in the maxilla and 1 mm in the mandible. She had a Class II canine and molar relationship on both sides. Her profile was convex and amalgam restorations were present on the upper right and lower left first molars (Figure 1a). She presented a unilateral posterior cross-bite on the right side. The cephalometric points and reference lines are given in Figure 1b. Cephalometric analysis showed that she was a hyperdivergent skeletal Class II patient (ANB = 7 degrees, NSL/ML = 44 degrees) (Table 1). According to the pretreatment hand and wrist film analysis, the patient was in the MP_{3u} period, indicating that she was nearly at the end of her skeletal maturation.

Treatment Plan

Extraction of both maxillary first premolars was considered to eliminate the increased overjet and crowding. Both conventional (including cervical head-gear for maximum anchorage) and rapid canine distalization (DAD) procedures were explained to the patient and her parents. The patient preferred rapid orthodontic treatment of 1-year duration with no use of extraoral or intraoral anchorage mechanics. Then, DAD surgery, DO protocol, and orthodontic procedures were described in detail, and an informed consent was signed by the patient and her parent.

The treatment plan therefore consisted of maxillary first premolar extraction and rapid canine retraction by DAD, followed by fixed appliance orthodontic treatment, with no use of extraoral or intraoral anchorage appliances.

Table 1. Cephalometric Measurements of the Patient Before DAD, After DAD, and After Orthodontic Treatment^a

	Before DAD	After DAD	End of Orthodontic Treatment
Maxillary measurements			
s n ss, degrees	80	80	80
NSL/NL, degrees	8	8	8
Mandibular measurements			
s n sm, degrees	73	73	72.5
NSL/ML, degrees	44	45	45
Maxillomandibular measurements			
ss n sm, degrees	7	7	6.5
NL/ML, degrees	35	36	37
Overbite, mm	4	3	2
Overjet, mm	9	9	2
Dentoalveolar measurements			
NL/ILs, degrees	113	113	98
NL/CLs, degrees	97	86	90
NL/MLs, degrees	89	89	89
NLv-is, mm	1	1	5.5
NLv-uc, mm	10.6	18.1	16.3
NLv-ms, mm	34	33.6	31.8
NL-is, mm	32.3	31.7	34.1
NL-uc, mm	28.3	27.9	30.9
NL-ms, mm	26	25.8	26.6
Soft tissue measurement			
Upper and lower lips (Steiner), mm	0.5/-1	1/-1	0/-0.5

^a Fourteen anatomic reference points were digitized (Figure 2), and the following dentoskeletal variables were measured: s n ss (degrees): the angle between sella, nasion, and subspinale (maxillary prognathism); NSL/NL (degrees): the nasal plane angle in relation to the anterior cranial base; s n sm (degrees): mandibular prognathism; NL/ML (degrees): mandibular inclination in relation to the nasal plane; ss n sm (degrees): sagittal intermaxillary relationship; overbite (mm): vertical distance between the incisal edges of the most prominent maxillary and mandibular central incisors; overjet (mm): sagittal distance between the incisal edges of the most prominent maxillary and mandibular central incisors; NL/ILs (degrees): maxillary incisor inclination angle between the long axes of the maxillary incisors in relation to the nasal plane (NL); NL/CLs (degrees): canine inclination angle between the long axes of the canines in relation to the NL; NL/MLs (degrees): upper maxillary molar inclination angle between the long axes of the maxillary first molars in relation to the NL; NLv-is (mm): sagittal position of the maxillary incisors in relation to the NLv; NLv-uc (mm): sagittal position of the maxillary canines in relation to the NLv; NLv-ms (mm): sagittal position of the maxillary first molars in relation to the NLv; NL-is (mm): vertical position of the maxillary incisors in relation to the NL; NL-uc (mm): vertical position of the maxillary canines in relation to the NL; NL-ms (mm): vertical position of the maxillary first molars in relation to the NL; upper and lower lips (Steiner) (mm): upper and lower lip position according to Steiner.

Surgical Procedure

Surgery was performed on an outpatient basis, with the patient under local anesthesia, sometimes supplemented with sedation. This procedure was described previously by Kişnişci et al.¹² A horizontal mucosal incision was made parallel to the gingival margin of the

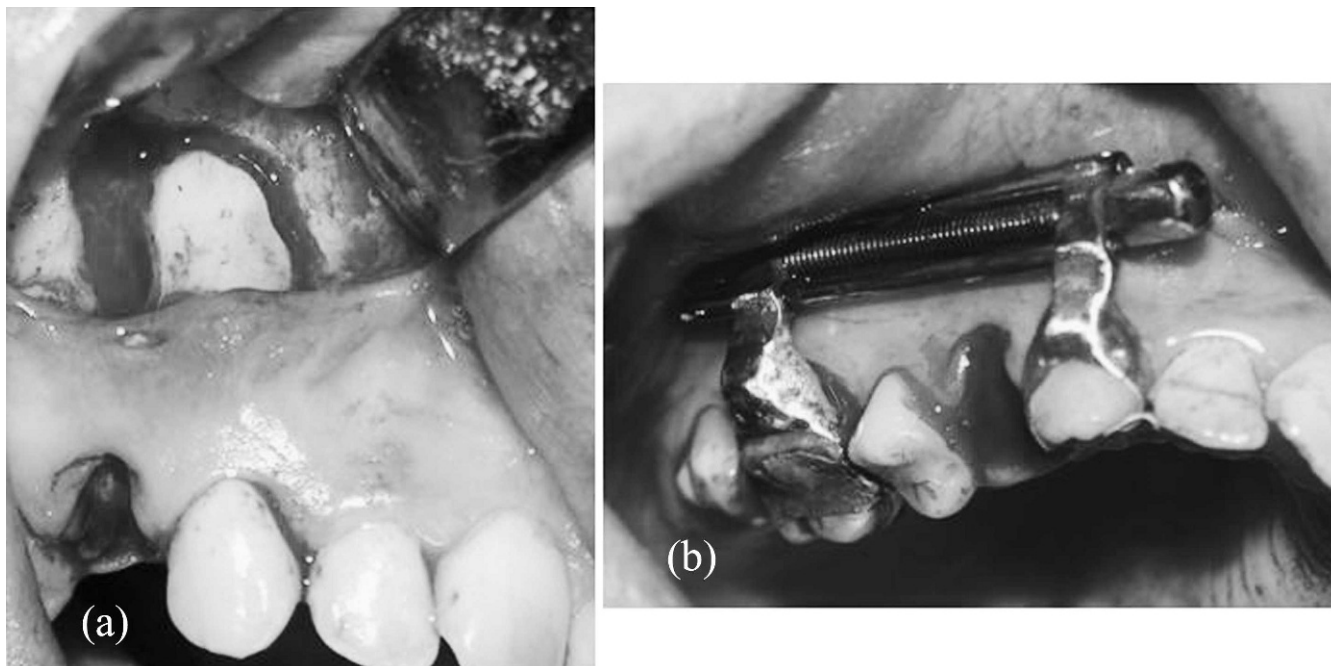


Figure 2. Intraoral view of the surgical site. (a) Corticomy. (b) Dentoalveolar distraction device in place. The canine and molar bands were fabricated, and distractors were soldered to the bands on the dental cast.

canine and premolar beyond the depth of the vestibule. Multiple cortical holes were made on the alveolar bone with a small, round, carbide bur on the medial aspect of the tooth to be distracted. The same procedure was applied on the distal aspect of the canine close to the extraction area, and the holes around the canine root were connected using a thin, tapered fissure bur.

The osteotomy curved apically at a distance of 3–5 mm from the apex. Then, the osteotomes were advanced in the coronal direction. At this stage, the first premolar was extracted and the buccal bone removed between the outlined bone cut at the distal canine region anteriorly and the second premolar posteriorly using a round bur (Figure 2a). The palatal shelf was preserved, but the apical bone near the sinus wall was removed, leaving the sinus membrane intact to avoid interference during the distraction process.

Osteotomes were used along the anterior aspect of the canine to split the surrounding bone around its root from the palatal or lingual cortex and neighboring teeth. The transport dentoalveolar segment that included the canine also included the buccal cortex and the underlying spongy bone that enveloped the canine root, leaving an intact lingual or palatal cortical plate and the bone around the apex of the canine. Finally, the DAD distractor was cemented onto the canine and the first molar (Figure 2b). To ensure that the transport segment was fully mobilized, the alveolar segment carrying the canine was mobilized intraoperatively by activating the device several millimeters and

setting it back to its original position. The incision was closed with absorbable sutures, and an antibiotic and a nonsteroidal anti-inflammatory drug were prescribed for 5 days. The surgical procedure usually lasted about 30 minutes for each tooth.^{12,13} The patient was instructed to discontinue tooth brushing for 3 days to avoid trauma around the surgical site. A 0.2% chlorhexidine gluconate rinse was prescribed twice a day during the distraction period.¹²

Appliance Design

A custom-made, rigid, tooth-borne intraoral distraction device was designed for canine DAD and rapid tooth movement (Figure 3). The canines and the first molars were banded with 0.06 × 1.80-inch band material, and an impression was made with the bands placed on the teeth. The distractor was then soldered to the canine and first molar bands on the dental cast with consideration of the biomechanical principles of tooth movement and the center of rotation of the canine (Figure 2b).

The device is made of stainless steel and has a distraction screw and two guidance bars. The patient or the parent turns the screw clockwise with a special apparatus which moves the canine distally. The device was fixed at the canine and first molar immediately after the surgical procedure, and no other appliance was placed on the other teeth during the distraction procedure (Figure 2b).



Figure 3. Dentoalveolar distraction device.

Dentoalveolar Distraction Protocol

Distraction was initiated within 3 days after surgery. The distractor was activated twice per day, in the morning and in the evening, for a total amount of about 0.8 mm per day. DAD is based on movement of the alveolar bone as an alveolar bony transport disc including the tooth. This type of distraction, termed bifocal distraction osteogenesis, consists of gradual movement of a vascularized bony segment or “transport disc” previously separated from the residual bone segment. New bone is formed during movement of the transport disc within the distraction site with simultaneous closing of the bony defect. The alveolar bone included the canine tooth.

DAD was discontinued when the canines came into contact with the second premolars, or the necessary amount of movement was achieved. The DAD device (distractor) was then removed and fixed orthodontic appliance treatment was immediately initiated by leveling both dental arches. The distraction phase was continued 12 days. Ligatures were placed under the archwire between the distracted canine and the first molar and were kept at least 3 months after completion of the DAD procedure, to avoid mesial movement of the canine. The patient was included in a meticulous oral hygiene program, which was initiated before and after the DAD procedure and was reinforced monthly, together with professional tooth cleaning, during fixed appliance orthodontic therapy.

Periapical radiographs of the canines and first molars and panoramic films were taken at the start and end of the distraction procedure to evaluate root structures. Root resorption was evaluated with a root resorption scale, modified from Sharpe et al¹⁵ as follows: S0 = no apical root resorption; S1 = widening of the periodontal ligament space at the root apex; S2

= moderate blunting of the root apex (up to one-third of the root length); and S3 = severe blunting of the root apex (beyond one-third of the root length). Pulp vitality was evaluated and recorded with an electronic digital pulp tester and a thermal pulp tester. All teeth subjected to the pulp vitality test (canines, incisors, second premolars, first molars) were cleaned and tested on the buccal surfaces.

Treatment Progress

The DAD was continued for 12 days, and then the leveling phase was immediately initiated by 0.014- or 0.016-inch nickel-titanium arch wires in the upper and lower dental arches. Next appointment, retraction of the maxillary anterior teeth was started with 0.016 × 0.016-inch stainless steel arch wire with reverse closing loops. In the third month of orthodontic treatment, retraction of the anterior teeth was almost completed and the overjet was reduced. Then, 0.016 × 0.022-in stainless steel arch wires were applied to maintain adequate torque in the anterior teeth. Overall orthodontic treatment time was 6 months. Extraoral photographs of the patient during treatment are shown in Figure 4, and intraoral occlusal, frontal, and right- and left-sided photographs of the patient are shown in Figures 5 through 8.

Treatment Outcome

A Class I canine and a Class II molar relationship were achieved at the end of 6 months of orthodontic treatment. The patient's cephalometric values before and after DAD and at the end of orthodontic treatment are given in Table 1. The amount of canine retraction was 7.5 mm in 12 days with a rate of 0.625 mm per day. The canine teeth showed 1.6 mm extrusion and 11 degrees inclination change (distal tipping) during the same period. Cephalometric analysis indicated that the upper first molars did not show any significant mesial or vertical displacement and/or angular changes during the DAD stage, indicating no posterior anchorage loss. No marked changes were observed in the other dentoskeletal measurements during DAD.

Overjet was reduced from 9 mm to 2 mm during the fixed appliance orthodontic treatment. Overbite was also decreased from 4 mm to 2 mm. Canine teeth that were distracted and 11 degrees inclined were uprighted 4 degrees compared with the post-DAD period with the use of fixed appliance mechanics. There was 1 degree of posterior rotation of the mandible, which might explain the opening of the bite during the fixed appliance orthodontic treatment. Mild or no changes were found in skeletal measurements at the end of orthodontic treatment, possibly because of the short duration of the orthodontic treatment.

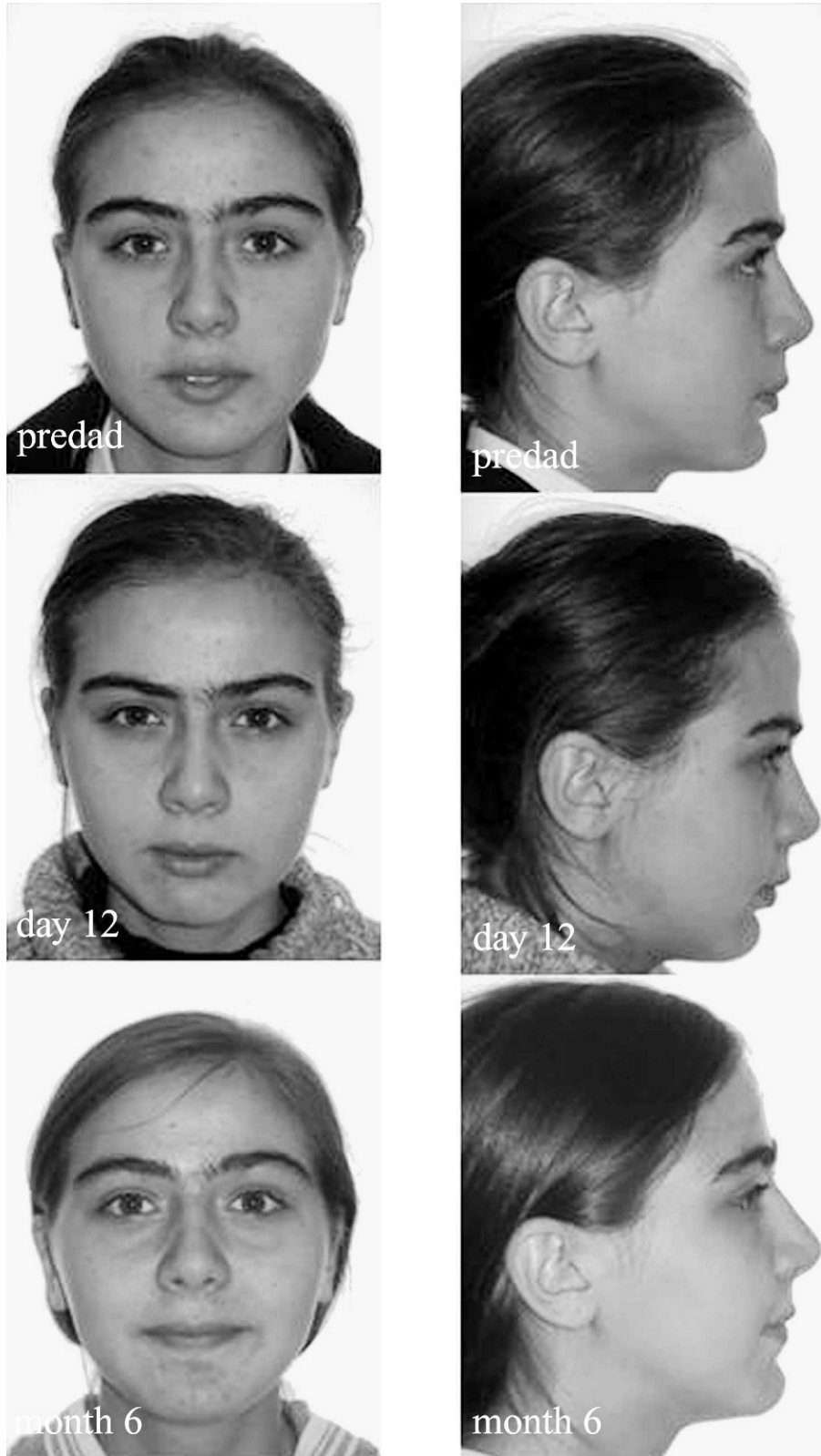


Figure 4. Extraoral photographs of the patient during treatment.

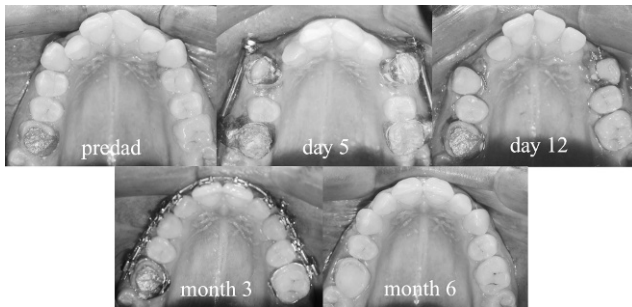


Figure 5. Intraoral occlusal photographs of the patient during treatment.

According to the root resorption scale modified from Sharpe et al,¹⁵ no apical root resorption (S0) was observed in the canine teeth or in the other maxillary and mandibular teeth (Figures 9 through 13). Pulp vitality was tested by an electronic and a thermal pulp tester after termination of fixed orthodontic treatment, and all teeth reacted positively, except the upper right first molar, which had a restoration.

Figures 14 and 15 illustrate intraoral and periapical radiographic views of the patient, 5 years after rapid canine retraction with DAD. Overbite was slightly increased during the follow-up period. No root resorption was observed in any of the maxillary teeth 5 years after DAD.

DISCUSSION

Different approaches were suggested to shorten the orthodontic treatment time.³⁻¹⁰ Distraction osteogenesis has been used in various skeletal bones, and use of this technique in craniofacial anomalies and with dentoalveolar discrepancies has become popular in recent years. İşeri and Kişnişçi¹¹⁻¹⁴ described and used a new technique of rapid canine retraction using the principles of distraction osteogenesis (DAD). With this new technique, osteotomies are made around the canine tooth for rapid tooth movement within the dentoalveolar segment using the principles of distrac-

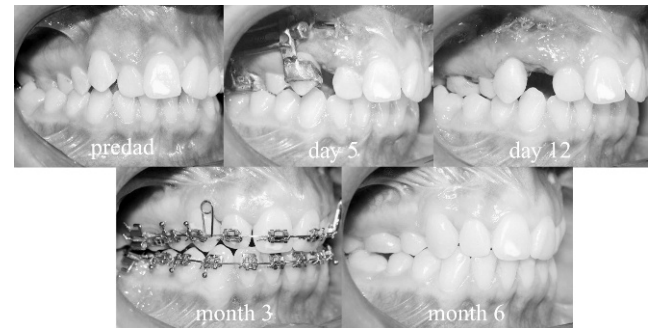


Figure 7. Intraoral photographs of the patient during treatment (right side).

tion osteogenesis. The findings of İşeri et al¹³ showed that full retraction time of the canines to the first premolar extraction site was 10.05 (± 2.01) days, which is similar to the retraction time of the present case (7.5 mm in 12 days, with a tooth movement rate of 0.625 mm per day).

Biological tooth movement with conventional procedures is limited.^{1,2} Vig et al¹⁶ examined five practices to determine whether a systematic relationship existed between the relative frequency of extraction treatments and the duration of active appliance therapy; their findings showed that extraction treatment was of longer duration than nonextraction therapy. The differences in duration were 3.0, 6.6, 2.4, 3.0, and 7.3 months in the five practices. In our case, canine retraction was achieved in 12 days and total orthodontic treatment time was only 6 months—almost the same amount of difference between extraction treatment and nonextraction therapy indicated by Vig et al.¹⁶

Many attempts have been made during past decades to shorten orthodontic treatment time. Corticotomy-assisted orthodontics has been suggested for reducing orthodontic treatment time.⁷⁻¹⁰ Gantes et al⁸ showed that mean orthodontic treatment duration was 14.8 months in the corticotomy-assisted group and 28.3 months in the control (without corticotomy) group.

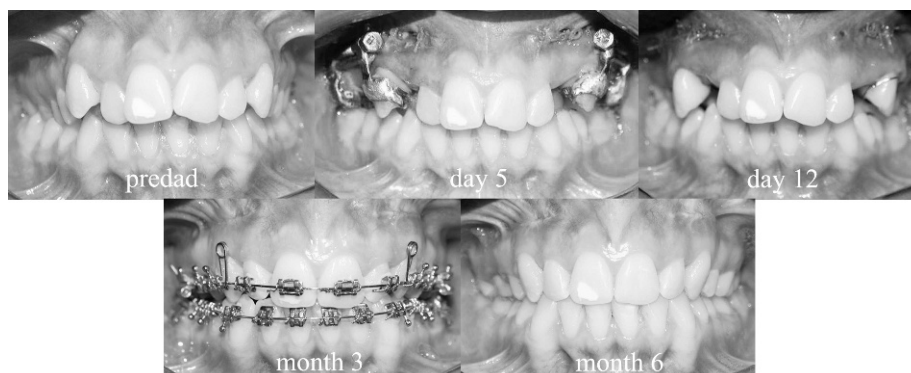


Figure 6. Intraoral frontal photographs of the patient during treatment.

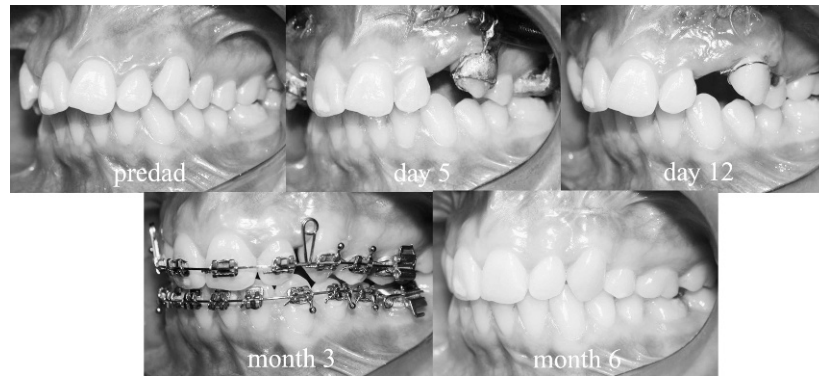

Figure 8. Intraoral photographs of the patient during treatment (left side).

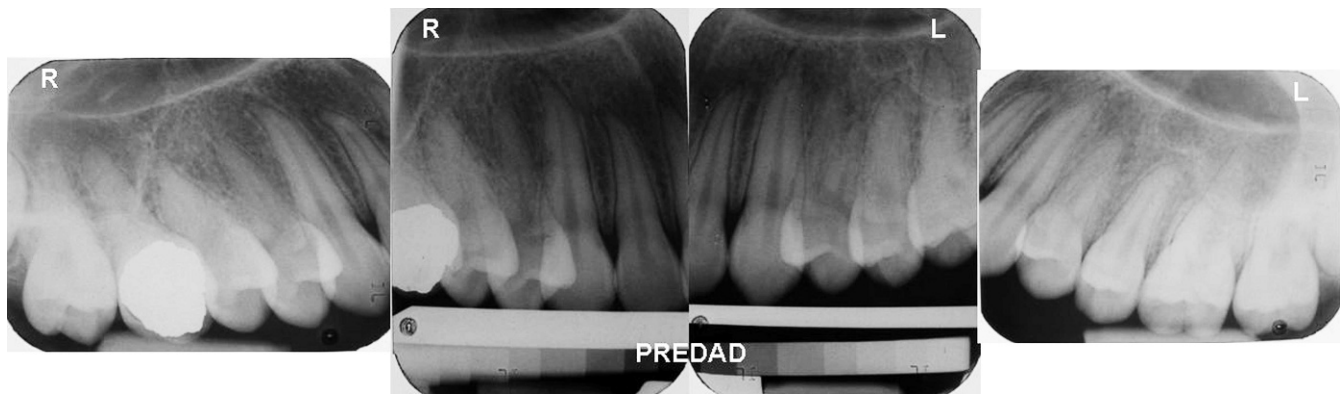

Figure 9. Periapical films of the patient before DAD.

Chung et al⁹ stated that the combined use of orthopedic traction and corticotomy procedures can be effective for anterior retraction and posterior intrusion, and these procedures can shorten the orthodontic treatment time. The surgical procedure of corticomy-assisted orthodontics includes palatal and vestibular mucosal incisions and corticotomies.^{8,9} In DAD, mucosal incisions and osteotomies are made only on the vestibular side of the alveolar bone, and the gingival margin, palatal mucosa, and palatal bone remain untouched, thus maintaining adequate blood

supply for the transport dentoalveolar segment that includes the canine teeth.

As was mentioned before, the canine teeth moved 7.5 mm distally and 1.6 mm vertically and tipped 11 degrees. Although the distractor was designed with a screw and two guidance bars and was placed as high as possible on the buccal side of the canine tooth, some amount of tipping was observed. This can be attributed to application of the force occlusal to the center of resistance of the canine tooth caused by anatomic limitations of the vestibular sulcus.

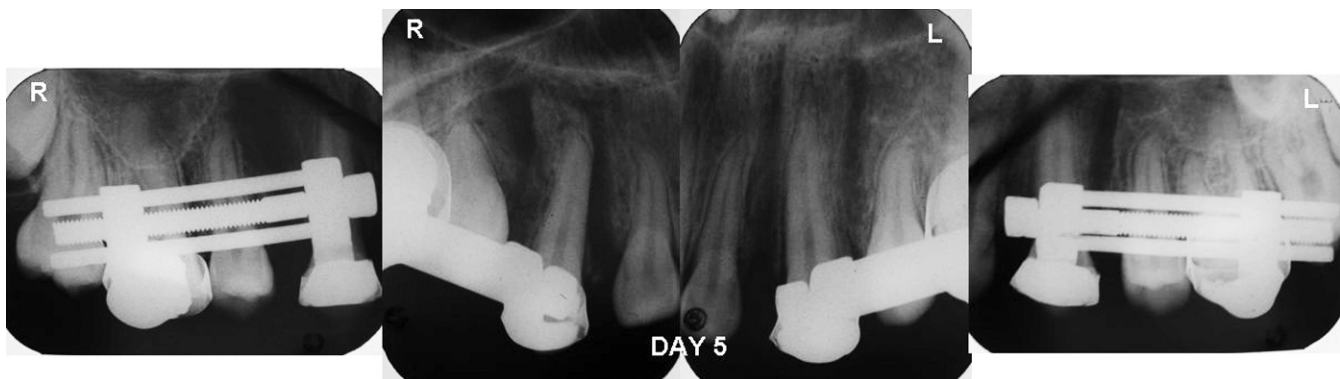

Figure 10. Periapical films of the patient on the fifth day of DAD.

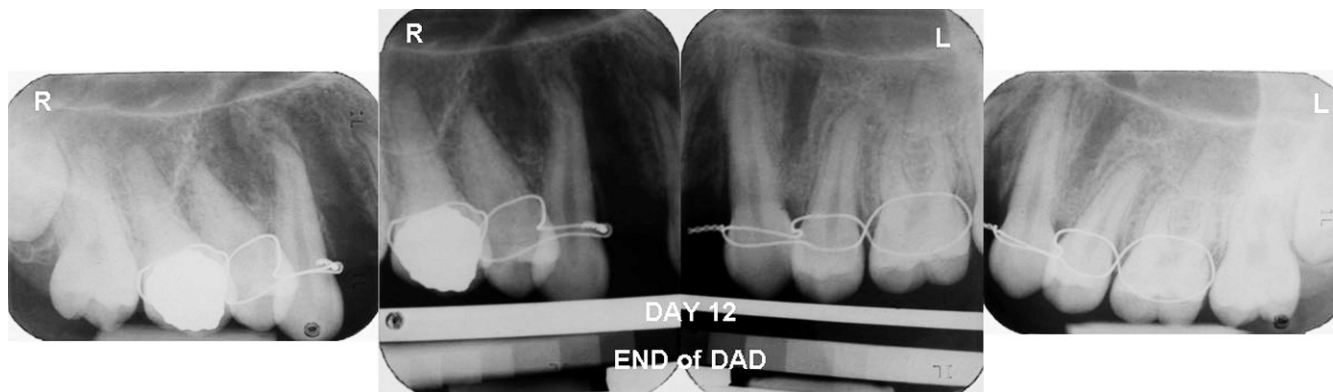

Figure 11. Periapical films of the patient on the 12th day of DAD.

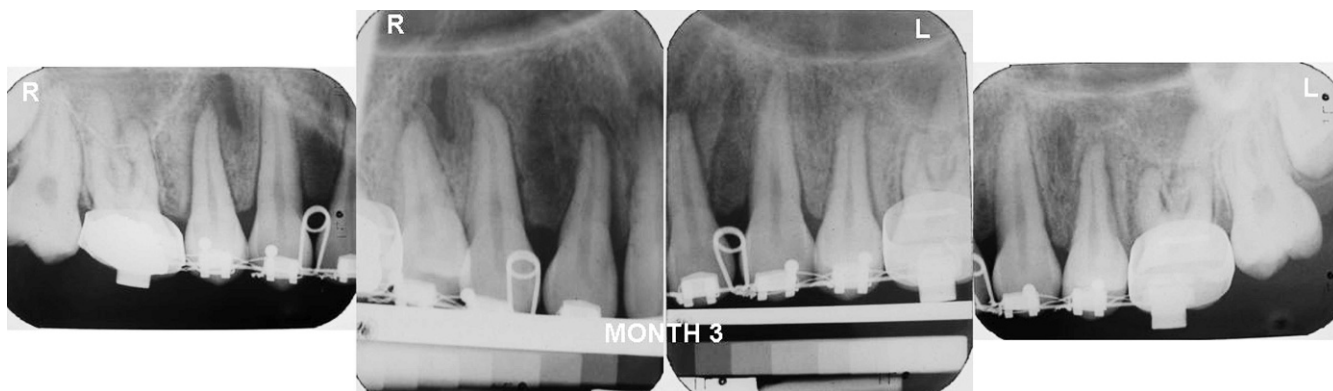


Figure 12. Periapical films of the patient 3 months after DAD.

Patients with first premolar extraction usually need effective posterior anchorage control, especially in maximum and moderate anchorage cases. Thus, extraoral or intraoral appliances are used to maintain adequate anchorage. The use of extraoral appliances (eg, headgear) sometimes causes cooperation problems, and filing use of these appliances results in anchorage loss. Use of miniscrews and implants has become popular in past years to maintain anchorage and to perform molar distalization and canine retrac-

tion. Although miniscrews and orthodontic implants are good alternatives to conventional types of extraoral or intraoral anchorage appliances, no system described in the literature can achieve rapid tooth movement.¹³ In the presented case, the canines retracted in 12 days with no use of extraoral or intraoral anchorage appliances.

Molar teeth did not show significant vertical, sagittal, and angular changes, indicating the absence of anchorage loss. During orthodontic tooth movement,

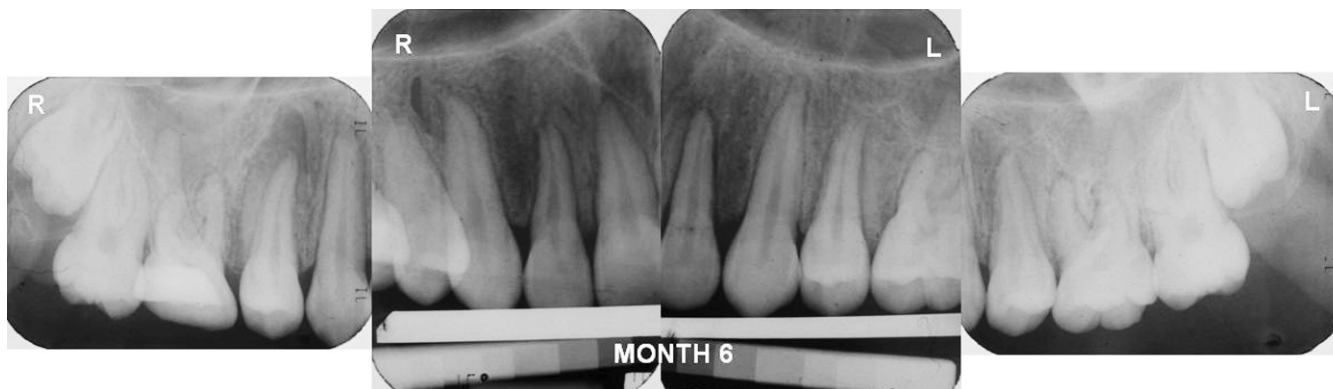

Figure 13. Periapical films of the patient 6 months after DAD.

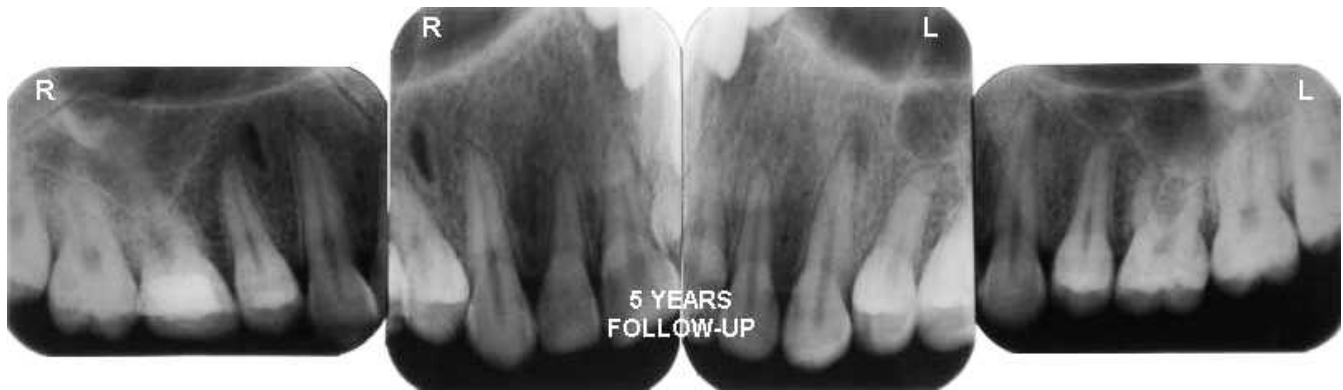

Figure 14. Periapical films of the patient 5 years after DAD.

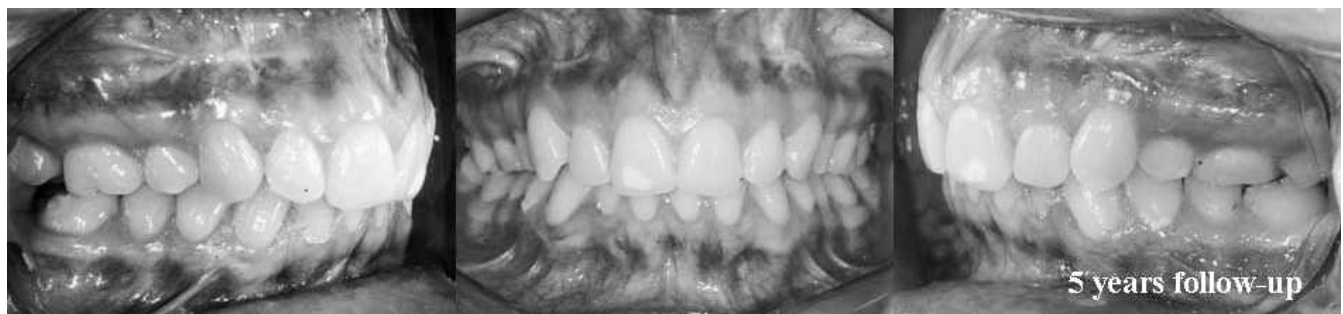

Figure 15. Intraoral photographs of the patient 5 years after DAD.

the hyalinized tissue on the compression side must be undermined with indirect resorption. This period usually lasts 2 or 3 weeks.¹ In our case, rapid canine retraction with DAD was achieved in 12 days, which is a minimal period for molars to move to the mesial.

Vertical corticotomies were performed around the root of the canine teeth, followed by splitting of the spongiosus bone surrounding it. The design of the surgical technique does not rely on periodontal stretching, and this prevents overloading and stress accumulation on the periodontal tissues. Because the tooth is moved within the alveolar segment, the risk of harmful side effects on the surrounding hard and soft tissues is eliminated.¹⁴ Therefore, no clinical and radiographic evidence of root fracture, root resorption, ankylosis, soft tissue dehiscence, or loss of vitality was observed in canine teeth at the end of DAD and orthodontic treatment, as well as at 5-year follow-up.

CONCLUSION

- Older adolescents and adult Class II patients with severe overjet are good candidates for DAD. DAD is an innovative method, in that it reduces orthodontic treatment time by about 50% with no need for extraoral or intraoral anchorage devices, and with no unfavorable long-term effects on periodontal tissues and surrounding structures.

REFERENCES

1. Reitan K. Clinical and histological observations on tooth movement during and after orthodontic treatment. *Am J Orthod Dentofac Orthop.* 1967;53:721–745.
2. Rygh P. Elimination of hyalinized periodontal tissues associated with orthodontic tooth movement. *Scand J Dent Res.* 1974;80:57–73.
3. Davidovitch Z, Finkelson MD, Steigman S, Shanfield JL, Montgomery PC, Korostoff E. Electric currents, bone remodeling and orthodontic tooth movement: I. The effect of electric currents on periodontal cyclic nucleotides. *Am J Orthod.* 1980;77:14–32.
4. Davidovitch Z, Finkelson MD, Steigman S, Shanfield FL, Montgomery PC, Korostoff E. Electric currents, bone remodeling and orthodontic tooth movement: II. Increase in rate of tooth movement and periodontal cyclic nucleotide levels by combined force and electric currents. *Am J Orthod.* 1980;77:33–47.
5. Liou EJW, Huang CS. Rapid canine retraction through distraction of the periodontal ligament. *Am J Orthod Dentofac Orthop.* 1998;114:372–382.
6. Liou EJW, Figueroa AA, Polley JW. Rapid orthodontic tooth movement into newly distracted bone after mandibular distraction osteogenesis in a canine model. *Am J Orthod Dentofac Orthop.* 2000;117:391–398.
7. Köle H. Surgical operations on the alveolar ridge to correct occlusal abnormalities. *Oral Surg Oral Med Oral Pathol Oral Radiol Endod.* 1959;12:515–529.
8. Gantes B, Rathbun E, Anholm M. Effects on the periodontium following corticotomy-facilitated orthodontics: case reports. *J Periodontol.* 1990;61:234–238.

9. Chung KR, Oh MY, Ko SJ. Corticomy-assisted orthodontics. *J Clin Orthod.* 2001;35:331–339.
10. Wilcko WM, Wilcko T, Bouquot JE, Ferguson DJ. Rapid orthodontics with alveolar reshaping: two case reports of decrowding. *Int J Periodontics Restorative Dent.* 2001;21:9–19.
11. İŞeri H, Bzeizi N, Kışnişci R. Rapid canine retraction using dentoalveolar distraction osteogenesis [abstract]. *Eur J Orthod.* 2001;23:453.
12. Kışnişci R, İŞeri H, Tüz H, Altuğ A. Dentoalveolar distraction osteogenesis for rapid orthodontic canine retraction. *J Oral Maxillofac Surg.* 2002;60:389–394.
13. İŞeri H, Kışnişci R, Bzeizi N, Tüz H. Rapid canine retraction and orthodontic treatment with dentoalveolar distraction osteogenesis. *Am J Orthod Dentofac Orthop.* 2005;127:533–541.
14. Gürkan CA, İŞeri H, Kışnişci R. Alterations in gingival dimensions following rapid canine retraction using dentoalveolar distraction osteogenesis. *Eur J Orthod.* 2005;27:324–332.
15. Sharpe W, Reed B, Subtelney JD, Polson A. Orthodontic relapse, apical root resorption, and crestal alveolar bone level. *Am J Orthod Dentofac Orthop.* 1987;91:252–258.
16. Vig PS, Weintraub JA, Brown C, Kowalski CJ. The duration of orthodontic treatment with and without extractions: a pilot study of five selected practices. *Am J Orthod Dentofac Orthop.* 1990;97:45–51.