

1-1-2016

## Chrysin prevents brain damage caused by global cerebral ischemia/reperfusion in a C57BL/J6 mouse model

MEHMET AKİF DURAK

MUSTAFA NAMIK ÖZTANIR

NEŞE BAŞAK TÜRKMEN

OSMAN ÇİFTÇİ

ASLI TAŞLIDERE

*See next page for additional authors*

Follow this and additional works at: <https://journals.tubitak.gov.tr/medical>



Part of the [Medical Sciences Commons](#)

---

### Recommended Citation

DURAK, MEHMET AKİF; ÖZTANIR, MUSTAFA NAMIK; TÜRKMEN, NEŞE BAŞAK; ÇİFTÇİ, OSMAN; TAŞLIDERE, ASLI; TECELLİOĞLU, MEHMET; and ÖNDER, ARİF (2016) "Chrysin prevents brain damage caused by global cerebral ischemia/reperfusion in a C57BL/J6 mouse model," *Turkish Journal of Medical Sciences*: Vol. 46: No. 6, Article 49. <https://doi.org/10.3906/sag-1508-119>  
Available at: <https://journals.tubitak.gov.tr/medical/vol46/iss6/49>

This Article is brought to you for free and open access by TÜBİTAK Academic Journals. It has been accepted for inclusion in Turkish Journal of Medical Sciences by an authorized editor of TÜBİTAK Academic Journals. For more information, please contact [academic.publications@tubitak.gov.tr](mailto:academic.publications@tubitak.gov.tr).

---

## Chrysin prevents brain damage caused by global cerebral ischemia/reperfusion in a C57BL/J6 mouse model

### Authors

MEHMET AKİF DURAK, MUSTAFA NAMİK ÖZTANIR, NEŞE BAŞAK TÜRKMEN, OSMAN ÇİFTÇİ, ASLI TAŞLIDERE, MEHMET TECELLİOĞLU, and ARİF ÖNDER

## Chrysin prevents brain damage caused by global cerebral ischemia/reperfusion in a C57BL/J6 mouse model

Mehmet Akif DURAK<sup>1\*</sup>, Mustafa Namık ÖZTANIR<sup>1</sup>, Neşe BAŞAK TÜRKMEN<sup>2</sup>,  
Osman ÇİFTÇİ<sup>3</sup>, Aslı TAŞLIDERE<sup>4</sup>, Mehmet TECELLİOĞLU<sup>5</sup>, Arif ÖNDER<sup>1</sup>

<sup>1</sup>Department of Neurosurgery, Faculty of Medicine, İnönü University, Malatya, Turkey

<sup>2</sup>Department of Pharmacy, Faculty of Pharmacy, İnönü University, Malatya, Turkey

<sup>3</sup>Department of Pharmacy, Faculty of Medicine, İnönü University, Malatya, Turkey

<sup>4</sup>Department of Histology and Embryology, Faculty of Medicine, İnönü University, Malatya, Turkey

<sup>5</sup>Department of Neurology, Faculty of Medicine, İnönü University, Malatya, Turkey

Received: 24.08.2015 • Accepted/Published Online: 06.03.2016 • Final Version: 20.12.2016

**Background/aim:** The present study investigated the neuroprotective effects of chrysin (CRS) following global cerebral ischemia and reperfusion (I/R) in a C57BL/J6 mouse model.

**Materials and methods:** A total of 40 mice were equally divided into four groups: (1) sham-operated (SH = control), (2) global cerebral I/R (I/R), (3) CRS, and (4) CRS + I/R. In the I/R group, the bilateral carotid arteries were clipped for 15 min and the mice were treated with vehicle (corn oil) for 10 days. In the CRS group, CRS (50 mg/kg) was given for 10 days without carotid occlusion. In the CRS + I/R group bilateral carotid arteries were clipped for 15 min and the mice were also treated with CRS (50 mg/kg) for 10 days. All of the rats were sacrificed under anesthesia on day 10, and neurodegenerative histological changes in the brain and tissue levels of oxidants and antioxidants were evaluated.

**Results:** CRS treatment significantly reversed the oxidative effects of I/R and inhibited the development of neurodegenerative histopathologies. In the CRS + I/R group, the decrease in TBARS levels and increase in GSH levels were similar to those in the SH group.

**Conclusion:** Treatment with CRS can positively affect the neural system of mice and it can be used for the treatment of global cerebral I/R.

**Key words:** Chrysin, neuroprotection, global ischemia/reperfusion, C57 BL /J6 mice

### 1. Introduction

Cerebral stroke is the second most common cause of death and disability in the world (1). Nearly half of all surviving stroke patients experience insufficient recovery, and half of these patients require assistance during activities of daily life (2). Approximately 70% of strokes are ischemic. Cerebral ischemic stroke typically originates from an initial interruption of blood flow, but even during the subsequent restoration of blood supply there may be insufficient delivery of oxygen and glucose to support cellular homeostasis (3,4). The interruption of blood flow leads to neuronal damage via the oxidation of intracellular molecules such as lipids, proteins, and DNA (5). It is well known that oxidative stress caused by the activation of reactive oxygen species (ROS) is a critical pathological component of cerebral ischemic injury. Thus, antioxidant agents that possess the ability to scavenge ROS have the

potential to mitigate the neurological damage caused by ischemia/reperfusion (I/R) (6,7). In the study by Yen et al., I/R injury has been shown with the occurrence of free oxygen radicals in the brain and causes the onset of programmed cell death (8). According to this pathological process, antioxidant agents could diminish the neurological damage caused by I/R.

Natural flavonoids and derivatives have been shown with several biological activities and a lot of beneficial properties, such as antioxidant, anti-inflammatory, antitumor, anti-allergic, neuroprotective, cardioprotective, and antimicrobial (9). The antioxidant properties of flavonoids allow them to display potential application as preventive and attenuating agents in oxidative stress (9). CRS (5,7 dihydroxyflavone) is a natural flavonoid that is present in honey, bee propolis, and many plant extracts (6,7). CRS has a broad range of pharmacological capabilities

\* Correspondence: makifdurak@yahoo.com

including anticancer, antioxidant, and antiinflammatory activities (10–12). It was shown that propolis and its most abundant component CRS have especially antioxidant effects and significantly decrease lipid peroxidation in the plasma, liver, lungs, and brain of mice (13).

We supposed that CRS, with its antiinflammatory and antioxidant properties, might exert a beneficial effect on ischemic brain tissue. The primary aim of the present study was to assess the possible neuroprotective effects of CRS in a mouse model of global I/R.

## 2. Materials and methods

### 2.1. Animals and experimental protocol

The present study was approved by the Ethics Committee on Animal Research of İnönü University and carried out in accordance with the Guidelines for Animal Research from the National Institutes of Health (NIH). C57BL/6J male mice (clean grade) weighing 18–22 g were supplied by the İnönü University Laboratory Animals Research Center (Malatya, Turkey), housed in sterilized polypropylene cages, and given an ad libitum diet of standard commercial food pellets and water. All mice were kept under a 12:12 h light:dark cycle at  $21 \pm 2$  °C ambient temperature and  $60 \pm 5\%$  humidity. A total of 40 animals (8 weeks old) were randomly divided into four groups ( $n = 10$ ): (1) sham-operated (SH), (2) global cerebral I/R, (3) CRS, and (4) CRS + global cerebral I/R (CRS + I/R). CRS (50 mg/kg) was dissolved in corn oil and administered by gavage (p.o.) for 10 consecutive days; the dose of CRS was based on preliminary dose-finding experiments from our lab, and the treatment was initiated concomitantly with the induction of global cerebral I/R. Mice in the SH and I/R groups were treated with only corn oil as a vehicle. In the CRS and CRS + I/R groups, the mice were treated with CRS (50 mg/kg/day) for 10 days following the I/R procedure. At the end of the experimental period, all animals were sacrificed under anesthesia, and tissue samples were obtained for laboratory analyses.

### 2.2. Surgical procedure

To induce global cerebral ischemia, the mice were first anesthetized with xylazine (5 mg/kg, i.p.) and ketamine (100 mg/kg, i.p.), and the ischemic procedure was performed according to the methods of Yonekura et al. Briefly, after a midline cervical incision, the bilateral common carotid arteries of the mice in the I/R and CRS + I/R groups were isolated and simultaneously occluded for 15 min using two vascular mini clips (14). The same surgical procedure was applied to the SH and CRS groups except that the carotid arteries were not clipped. Following surgery, all mice were placed in a thermal room until they recovered from anesthesia.

### 2.3. Biochemical analyses

The tissue homogenization process has been briefly described in a previous study from our lab. Additionally, this study describes the spectrophotometric methods used to determine the levels of TBARS and total GSH and the activities of catalase (CAT) and superoxide dismutase (SOD) and glutathione peroxidase (GPx) (15,16).

### 2.4. Histological evaluation

To prepare for evaluation with a light microscope, the brain tissue samples were fixed in 10% formalin and embedded in paraffin. The paraffin-embedded specimens were cut into 5- $\mu$ m-thick sections, mounted on slides, and stained with hematoxylin–eosin (H-E). All tissue samples were examined using a Leica DFC280 light microscope and a Leica Q Win Image Analysis system (Leica Micros Imaging Solutions, Ltd., Cambridge, UK). For the evaluations, cerebral and cerebellum damage was semiquantitatively graded as 0 normal, 1 mild, 2 moderate, 3 severe, for each criterion. Additionally the thickness of total cerebral cortex and cerebellum cortex layers (molecular, Purkinje cell, and granular layers) from ten different areas of each specimen was measured.

For the immunohistochemical analyses, 5- $\mu$ m-thick tissue sections were mounted on polylysine-coated slides. Following rehydration, the sections were transferred to a citrate buffer (pH 7.6), heated in a microwave oven for 20 min, and then cooled for 20 min at room temperature. The sections were then washed with phosphate-buffered saline (PBS), placed in 0.3% H<sub>2</sub>O<sub>2</sub> for 7 min, and washed again with PBS. Next, the sections were incubated with primary rabbit-polyclonal caspase-3 antibody (Abcam, Ab4051) for 2 h, rinsed in PBS, incubated with biotinylated goat antipolyvalent for 10 min, and then incubated in streptavidin peroxidase for 10 min at room temperature. The staining procedure was completed with a chromogen + substrate procedure for 15 min, and then the slides were counterstained with Mayer's hematoxylin for 1 min, rinsed in tap water, and dehydrated. The caspase-3 kit was used according to the manufacturer's instructions. The presence of cells undergoing apoptosis was determined by the immunohistochemical detection of caspase-3. The caspase-3-labeled cells (pyramidal neurons in the cerebral cortex and Purkinje cells) were counted. Ten randomly selected areas for each specimen were examined under a 40 $\times$  objective.

### 2.5. Statistical analyses

SPSS 13.0 software (SPSS, Inc., Chicago, IL, USA) was used for all statistical analyses. The biochemical values were analyzed with one-way analysis of variance (ANOVA) and a post hoc Tukey's honestly significant differences test. P-values  $\leq 0.05$  were considered to indicate statistical significance.

### 3. Results

#### 3.1. Biochemical results

The values of the biochemical parameters (TBARS, GSH, CAT, GPx, and SOD) in the brain tissues of the mice are provided in the Table. In the global cerebral I/R group, there was a significant increase in TBARS levels ( $P = 0.004$ ) and a significant decrease in GSH, CAT, GPx, and SOD levels compared with the other groups ( $P = 0.005$ ). However, the CRS + I/R group showed a decrease in TBARS levels and increase in GSH levels and an enhancement of the diminished GSH levels to values similar to those of the SH group. The CRS + I/R group also showed an increase in CAT and SOD activities compared with the I/R group ( $P = 0.014$ ). Only GPx activity was not significantly affected by CRS treatment relative to the I/R group, and these levels did not return to normal values. However, the activities of CAT and SOD were partially restored to normal values, and there was a significant difference between the SH and CRS + I/R groups ( $P = 0.005$ ).

#### 3.2. Histopathological results

In the SH (control) and CRS groups, the neurons in the cortical brain tissue samples were observed as regular and neurons were also intact with a normal histological appearance and, in the I/R group, there were severe degenerative changes in the neurons. CRS treatment significantly ameliorated these harmful effects in the I/R + CRS group (Figures 1A–1D and 2A–2D). However, the I/R group exhibited histological alterations including shrinkage of the cytoplasm and extensively dark pyknotic nuclei in the neurons of the cerebral cortex, cell infiltration, vascular congestion as another remarkable finding in the pia mater, hemorrhage, and vascular congestion (Figure 3). In the SH (control) and CRS groups, the Purkinje cell layer and granular layer were marked in the cerebellar cortex, exhibiting a normal histological appearance with no histological changes (Figures 4A and 4B). In the I/R group, there were deeply stained, shrunken, and variously shaped Purkinje cells with pyknotic nuclei; the Purkinje cell layer was separated from the granular layer in this group, but

treatment with CRS in the I/R + CRS group decreased the number of degenerative Purkinje cells (Figures 4C and 4D). In the I/R group, the cerebral and cerebellum cortex were thinner than in the SH and CRS groups ( $P = 0.001$ ). No significant difference was found between the CRS and I/R + CRS groups in terms of neuronal appearance ( $P > 0.05$ ).

Immunohistochemically caspase-3-stained cells were not observed except for a few cells in the cerebral cortex in the SH or CRS group, but there was a high percentage of caspase-3-positive cells in the I/R group (Figures 5A–5C). However, evaluations of caspase-3 immunohistochemistry revealed a large number of apoptotic neurons after I/R exposure in the cerebrum and cerebellum. The density of immunohistochemically caspase-3-stained cells was minimal in the I/R + CRS group (Figure 5D).

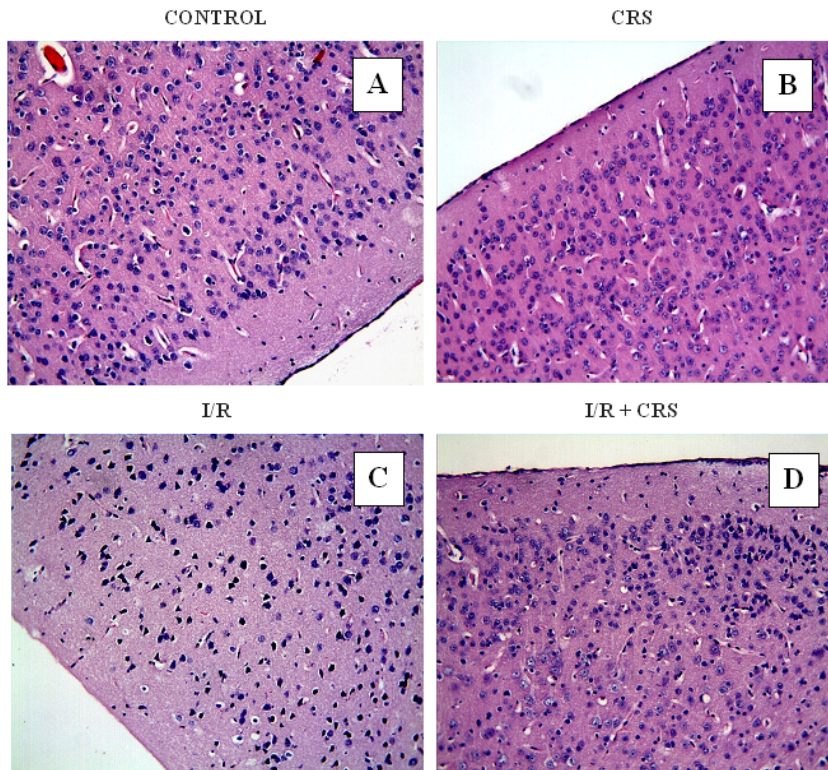
### 4. Discussion

The main finding of this study was that CRS attenuates the neuronal damage caused by global cerebral I/R. The quick recanalization of occluded cerebral arteries is a radical treatment for strokes caused by ischemia and may be applied as a primary treatment procedure (17). However, after cerebral ischemia and cerebral edema, reperfusion via vessel recanalization can result in brain damage that will lead to complications such as cerebral hemorrhage and/or the death of neurons, even if done correctly; this phenomenon is known as cerebral I/R injury (18). ROS and oxidative stress play key roles in the pathogenesis of I/R injury because they are released during reperfusion following cerebral ischemia and can initiate a chain reaction that leads to the activation of cell death signaling pathways in mitochondria. Therefore, this increase in free radicals may be accompanied by fatal brain damage following ischemia. There has been a recent increase in the occurrences of free radicals and lipid peroxidation after ischemic attacks, which suggests that it is of increasing importance to develop compounds with radical scavenging capabilities to treat I/R injuries (19–21). In recent years, the importance of a radical scavenging

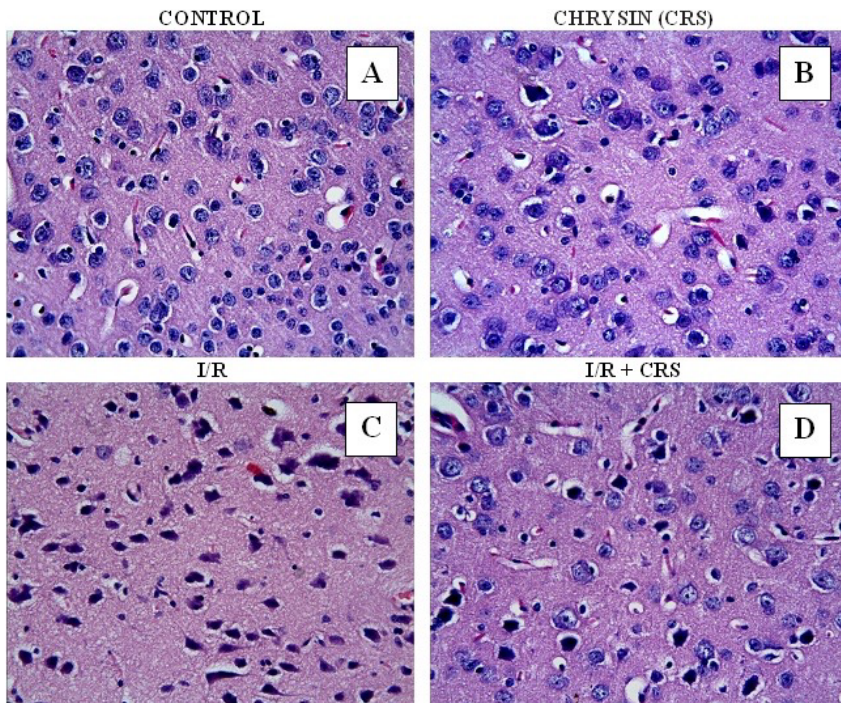
**Table.** Levels of SOD, CAT, GPx, GSH, and TBARS in the brain tissue of C57 BL/J6 mice.

(Mean ± SD)	TBARS nmol/g tissue	Reduced GSH nmol/mL	CAT k/mg protein	SOD U/mg protein	GPx U/mg protein
Sham	8.51 ± 1.09 <sup>a</sup>	190.1 ± 4.7 <sup>a</sup>	0.031 ± 0.0010 <sup>a</sup>	29.12 ± 1.98 <sup>a</sup>	205.8 ± 16.3 <sup>a</sup>
I/R	14.3 ± 1.21 <sup>b</sup>	135.8 ± 5.1 <sup>b</sup>	0.021 ± 0.0009 <sup>b</sup>	16.61 ± 1.19 <sup>b</sup>	158.5 ± 14.9 <sup>b</sup>
CRS	8.83 ± 1.17 <sup>a</sup>	201.4 ± 4.9 <sup>a</sup>	0.032 ± 0.0012 <sup>a</sup>	28.52 ± 1.96 <sup>a</sup>	216.2 ± 17.1 <sup>a</sup>
I/R + CRS	9.3 ± 0.96 <sup>a</sup>	165.8 ± 7.1 <sup>c</sup>	0.026 ± 0.0007 <sup>c</sup>	23.49 ± 2.18 <sup>c</sup>	169.1 ± 12.4 <sup>b</sup>

Means bearing different superscripts within the same column are significantly different ( $P < 0.01$ ).

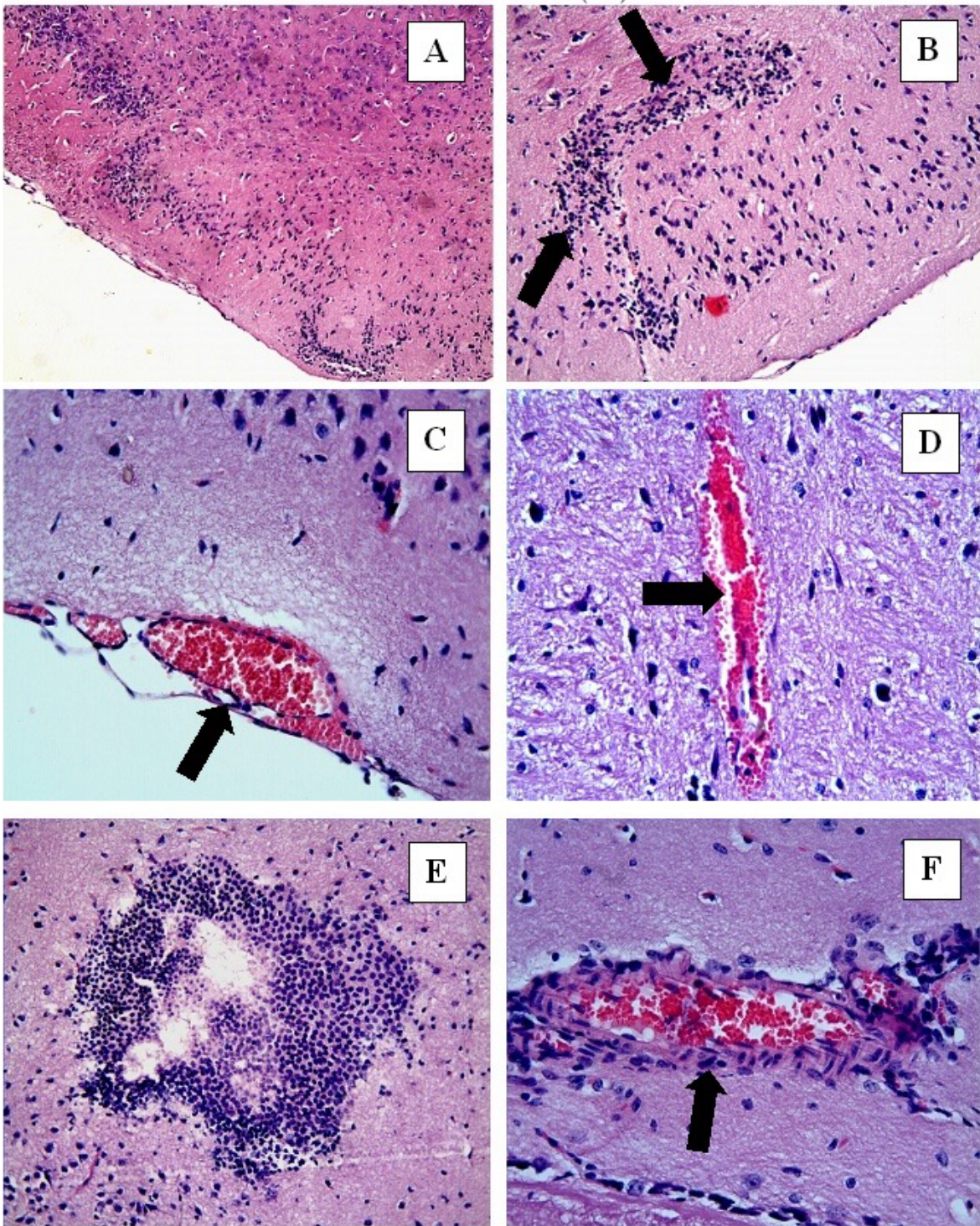


**Figure 1.** In the SH (control) (A) and CRS (B, D) groups, the neurons in the cortical brain tissue samples were observed as regular and neurons were also intact with a normal histological appearance. In the I/R group (C), there were severe degenerative changes in the neurons. Sections of cerebral cortical tissue from all groups. H-E, 20 $\times$ .

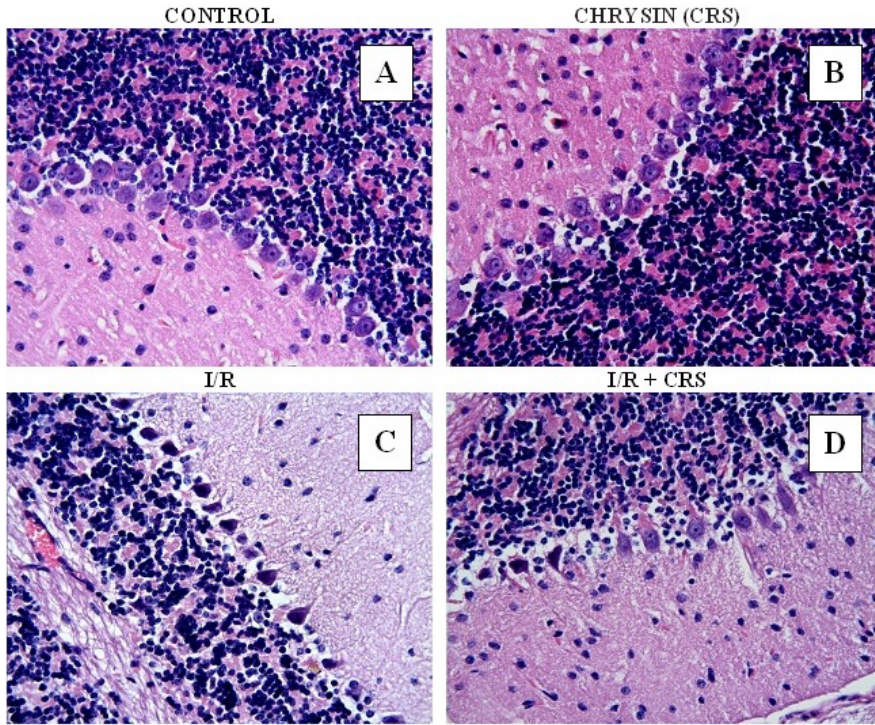


**Figure 2.** In the control (A) and CRS (B) groups, the cerebral cortical neurons exhibited a normal histological appearance. In the I/R group (C), there were severe degenerative changes in the neurons, but there was a decrease in the number of degenerative neurons in the I/R + CRS group (D) compared with the I/R group. H-E, 40 $\times$ .

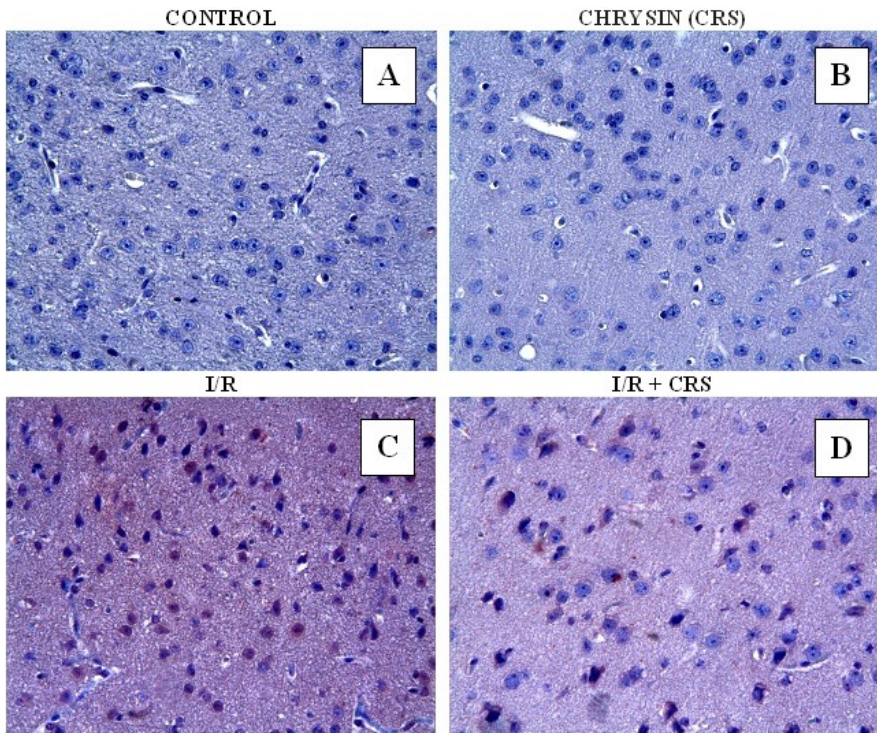
ISCHEMIA- REPERFUSION (I/R) GROUP



**Figure 3.** In the I/R group, cell infiltration (A, B, E, F), vascular congestion (C, F), and hemorrhaging (D) were observed in the brain tissue. A: H-E, 10 $\times$ ; B: H-E, 20 $\times$ ; C, D, F: H-E, 40 $\times$ .



**Figure 4.** In the control (A) and CRS (B) groups, the Purkinje cells exhibited a normal histological appearance, but in the I/R group (C), the degenerative Purkinje cells were prominent. The number of degenerative Purkinje cells significantly decreased in the I/R + CRS group (D). H-E, 40 $\times$ .



**Figure 5.** Immunohistochemical caspase-3 staining in all experimental groups. There were no positively stained cells in the control (A) or CRS (B) groups. There was a decrease in the percentage of positively stained cells in the I/R + CRS group (D) compared with the IR group (C).

compound experimental I/R treatment was found by chance (11,18,22).

Flavonoids and flavones that naturally occur in honey, vegetables, and fruits are also present in some plant-based polyphenolic beverage compounds, and the antioxidant properties of these compounds may be effective for the treatment of many diseases (23,24). CRS is a natural flavone obtained from many types of plant, honey, and propolis (25,26). In fact, a number of recent studies have shown that CRS is an antiinflammatory and a vasodilator and has strong antioxidant effects (10,13,27).

In the present study, the efficacy of CRS for the amelioration of the neuronal damage caused by global cerebral I/R was examined in a C57/BL6 mouse model. Treatment with CRS (50 mg/kg) protected the central nervous system against I/R induced damage via significant reductions in lipid peroxidation and significant enhancements of enzymatic and nonenzymatic antioxidant defense systems. Following global cerebral I/R in the brains of mice, oxidative stress is a primary pathological consequence that causes irreversible injury to neurons due to enhanced lipid peroxidation via the action of ROS (28). In the present study, this is evidenced by the elevation in TBARS levels following the ischemic procedure. Furthermore, ROS are produced in excess following the reperfusion process and can cause downregulation in specific elements of the antioxidant defense systems, including SOD, CAT, GPx, and GSH (28). The oxidative stress that results from an imbalance between TBARS levels and antioxidant defense systems can be induced by the I/R process and may play an important role in ischemic stroke injury (15,16). In the present study, the I/R induced lipid peroxidation that resulted from the significant increase in TBARS levels led to irreversible neuronal damage. Additionally, the enzymatic (SOD, CAT) and nonenzymatic (GSH) antioxidant defense systems were suppressed in ischemic mice, and significant decreases in SOD and CAT activities and the level of GSH, a specific ROS scavenger, were observed. The signaling pathways underlying I/R remain largely unknown, but oxidative stress plays an important role in global cerebral I/R. It is thought that oxidative stress causes significant cell death and neuronal damage because the brain has a

large amount of oxidizable unsaturated fatty acids and low antioxidant enzyme activity (28). The activities of CAT and SOD were partially restored to normal values, and there was a significant difference in these values between the SH and CRS + I/R groups. In the CRS + I/R group, a decrease in TBARS levels and an increase in GSH levels similar to those in the SH group were identified. Thus, the present findings demonstrate that CRS treatment effectively prevents oxidative and histological damage in the brain following global I/R.

The histopathological and immunohistopathological findings of the present study revealed that I/R caused major structural changes in brain tissue compared with the SH animals. The primary damage included diffuse and focal ischemic areas in the cerebral cortex as well as secondary issues such as cell infiltration, vascular congestion, shrinkage of the cytoplasm, and extensively dark pyknotic nuclei in the neurons of cerebral cortical tissue. However, in the present study, CRS treatment partially ameliorated the histological changes caused by I/R and resulted in significantly higher numbers of caspase-3-stained cells, which are indicative of the apoptotic rate in neurons, in the I/R group compared with the CRS + I/R group. Thus, it is proposed here that CRS may protect against ischemic damage via the attenuation of enhanced oxidative stress activity and the prevention of histological damage in brain tissue.

The present study demonstrated that 15 min of cerebral I/R in C57BL/J6 mice resulted in neurodegenerative effects that were associated with increases in oxidative stress and histopathological changes in brain tissue. Additionally, treatment with CRS (50 mg/kg per day) for 10 consecutive days following cerebral I/R generally reversed the potentially negative effects of I/R on brain tissue, likely due to its strong antioxidant and radical scavenging properties. Therefore, based on the present results, it is proposed that CRS attenuates the neuronal damage caused by global cerebral I/R.

#### Acknowledgment

We acknowledge the support of IUBAP (Scientific Research Fund of İnönü University) under Grant 2013/204.

#### References

1. Zhou XQ, Zeng XN, Kong H, Sun XL. Neuroprotective effects of berberine on stroke models in vitro and in vivo. *Neuroscience Letters* 2008; 447: 31-36.
2. Bonita R, Solomon N, Broad JB. Prevalence of stroke and stroke-related disability. Estimates from the Auckland stroke studies. *Stroke* 1997; 28: 1898-1902.
3. Silvestrelli G, Corea F, Paciaroni M, Milia P, Palmerini F, Parnetti L, Gallai V. The Perugia hospital-based stroke registry: report of the 2nd year. *Clinical and Experimental Hypertension* 2002; 24: 485-491.
4. Zhang S, Qi Y, Xu Y, Han X, Peng J, Liu K, Sun CK. Protective effect of flavonoid-rich extract from *Rosa laevigata* Michx on cerebral ischemia-reperfusion injury through suppression of apoptosis and inflammation. *Neurochem Int* 2013; 63: 522-532.

5. Oztanir MN, Ciftci O, Cetin A, Durak MA, Basak N, Akyuva Y. The beneficial effects of 18b-glycyrrhetic acid following oxidative and neuronal damage in brain tissue caused by global cerebral ischemia/reperfusion in a C57BL/J6 mouse model. *Neurol Sci* 2014; 35: 1221-1228.
6. Heo JH, Han SW, Lee SK. Free radicals as triggers of brain edema formation after stroke. *Free Radic Biol Med* 2005; 39: 51-70.
7. Margail I, Plotkine M, Lerouet D. Antioxidant strategies in the treatment of stroke. *Free Radic Biol Med* 2005; 39: 429-443.
8. Yen TL, Hsu CK, Lu WJ, Hsieh CY, Hsiao G, Chou DS, Wu GJ, Sheu JR. Neuroprotective effects of xanthohumol, a crenelated flavonoid from hops (*Humulus lupulus*), in ischemic stroke of rats. *J Agric Food Chem* 2012; 60: 1937-1944.
9. Catarino MD, Alves-Silva JM, Pereira OR, Cardoso SM. Antioxidant capacities of flavones and benefits in oxidative-stress related diseases. *Curr Top Med Chem* 2015; 15: 105-119.
10. Lapidot T, Walker MD, Kanner J. Antioxidant and prooxidant effects of phenolics on pancreatic beta-cells in vitro. *J Agric Food Chem* 2002; 50: 7220-7225.
11. Cho H, Yun CW, Park WK, Kong JY, Kim KS, Park Y, Lee S, Kim BK. Modulation of the activity of pro-inflammatory enzymes, COX-2 and iNOS, by chrysin derivatives. *Pharmacol Res* 2004; 49: 37-43.
12. Fu B, Xue J, Li Z, Shi X, Jiang BH, Fang J. Chrysin inhibits expression of hypoxia-inducible factor-1 alpha through reducing hypoxia-inducible factor-1 alpha stability and inhibiting its protein synthesis. *Mol Cancer Ther* 2007; 6: 220-226.
13. Sobocanec S, Sverko V, Balog T, Sarić A, Rusak G, Likić S, Kusić B, Katalinić V, Radić S, Marotti T. Oxidant/antioxidant properties of Croatian native propolis. *J Agric Food Chem* 2006; 54: 8018-8026.
14. Yonekura I, Kawahara N, Nakatomi H, Furuya K, Kirino T. A model of global cerebral ischemia in C57 BL/6 mice. *J Cereb Blood Flow Metab* 2004; 24: 151-158.
15. Ciftci O, Ozdemir I, Vardi N, Beytur A, Oguz F. Ameliorating effects of quercetin and chrysin on 2,3,7,8-tetrachlorodibenzo-p-dioxin-induced nephrotoxicity in rats. *Toxicol Ind Health* 2012; 28: 947-954.
16. Oguzturk H, Ciftci O, Aydin M, Timurkaan N, Beytur A, Yilmaz F. Ameliorative effects of curcumin against acute cadmium toxicity on male reproductive system in rats. *Andrologia* 2012; 44: 243-249.
17. Hacke W, Donnan G, Fieschi, Kaste M, von Kummer R, Broderick JP, Brott T, Frankel M, Grotta JC, Haley EC Jr, et al. Association of outcome with early stroke treatment: pooled analysis of ATLANTIS, ECASS, and NINDS rt-PA stroke trials. *Lancet* 2004; 363: 768-774.
18. Guo C, Tong L, Xi M, Yang H, Dong H, Wen A. Neuroprotective effect of calycosin on cerebral ischemia and reperfusion injury in rats. *J Ethnopharmacol* 2012; 144: 768-774.
19. Janardhan V, Qureshi AI. Mechanisms of ischemic brain injury. *Curr Cardiol Rep* 2004; 6: 117-23.
20. Piantadosi CA, Zhang J. Mitochondrial generation of reactive oxygen species after brain ischemia in the rat. *Stroke* 1996; 27: 327-331.
21. Christophe M, Nicolas S. Mitochondria: a target for neuroprotective interventions in cerebral ischemia-reperfusion. *Curr Pharm Des* 2006; 12: 739-757.
22. Xiao LH, Yue HW, Ming GB, Guan HD. Chrysin improves cognitive deficits and brain damage induced by chronic cerebral hypoperfusion in rats. *Eur J Pharmacol* 2012; 680: 41-48.
23. Hollman PC, Feskens EJ, Katan MB. Tea flavonols in cardiovascular disease and cancer epidemiology. *Proc Soc Exp Biol Med* 1999; 220: 198-202.
24. Sakagami H, Jiang Y, Kusama K, Atsumi T, Ueha T, Toguchi M, Iwakura I, Satoh K, Fukai T, Nomura T. Induction of apoptosis by flavones, flavonols (3-hydroxyflavones) and isoprenoid-substituted flavonoids in human oral tumor cell lines. *Anticancer Res* 2000; 20: 271-277.
25. Rapta P, Misik V, Stasko A, Vrabel I. Redox intermediates of flavonoids and caffeic acid esters from propolis: an EPR spectroscopy and cyclic voltammetry study. *Free Radic Biol Med* 1995; 18: 901-908.
26. Williams CA, Harborne JB, Newman M, Greenham J, Eagles J. Chrysin and other leaf exudate flavonoids in the genus *Pelargonium*. *Phytochemistry* 1997; 46: 1349-1353.
27. Duarte J, Jiménez R, Villar IC, Pérez-Vizcaíno F, Jiménez J, Tamargo J. Vasorelaxant effects of the bioflavonoid chrysin in isolated rat aorta. *Planta Med* 2001; 67: 567-569.
28. Wang JJ, Cui P. Neohesperidin attenuates cerebral ischemia-reperfusion injury via inhibiting the apoptotic pathway and activating the Akt/Nrf2/HO-1 pathway. *J Asian Nat Prod Res* 2013; 15: 1023-1037.