

Isolated renal relapse of a case with non-Hodgkin's lymphoma

H. Mehmet Turk · Ahmet Ozet · Mustafa Öztürk · Şeref Komurcu · Okan Kuzhan · Fikret Arpacı · Bekir Ozturk · Mukerrem Safali

Received: 16 March 2009 / Accepted: 28 April 2009 / Published online: 13 May 2009
© Humana Press Inc. 2009

Abstract A 29-year-old woman with left pleural effusion and a mass in anterior mediastinum was admitted. Trans-thoracic needle aspiration from the mass revealed findings consistent with nodular sclerosis variety of Hodgkin's disease. The patient was in remission after six cycles of ABVD followed by mediastinal radiotherapy. Ten months later CT scan showed three hypodense masses in the right kidney. Ultrasound guided renal biopsy revealed diffuse large B cell lymphoma. Retrospective re-evaluation of the archival specimens of the mediastinal mass was also consistent with diffuse large B cell lymphoma. After induction chemotherapy (four cycles of DHAP) she underwent high dose chemotherapy (BEAM) and autologous peripheral blood stem cell transplantation. She is still in remission for 7 years after transplantation. In conclusion, renal involvement during advanced lymphoma is quite common but isolated renal relapse in NHL is a rare situation. Although renal infiltration generally shows a poor prognosis, long-term survival may be achieved with high dose chemotherapy and autologous peripheral blood stem cell transplantation.

Keywords Non-Hodgkin's lymphoma · NHL · Renal relapse · CA-125 · High dose chemotherapy · Autologous peripheral blood stem cell transplantation

Introduction

Non-Hodgkin's lymphoma (NHL) usually originates in lymphoid tissue, but extranodal involvement such as stomach, intestines, lung, breast, and kidney has been also described. Primary renal lymphoma (PRL) as the only site is a rare entity [1]. Usually, renal infiltration is reported during the course of advanced disease. Kidneys are mostly infiltrated by diffuse large B cell lymphoma. Renal involvement commonly presents by acute renal failure, hematuria, weight loss, and renal mass with flank pain. Its clinical and imaging characteristics resemble renal carcinoma and usually clinically silent. Definitive diagnosis should be made with renal biopsy [2, 3]. NHL cases with renal involvement have poor prognosis [4, 5]. But cases with long survival have been reported [5, 6]. We report here an NHL case with high serum CA-125 level at diagnosis and isolated renal masses at relapse.

Case

In March 2001, a 29-year-old woman was presented with dyspnoea and cough. Physical examination showed no organomegaly and no lymphadenopathy. Lung sounds were diminished at left middle and lower zones. Laboratory tests were as follows: hemoglobin 12.8 g/dl, hematocrit 40.5%, white blood cell $6.8 \times 10^9/l$, platelets $248 \times 10^9/l$, AST 24 U/l, ALT 32 U/l, ALP 132 U/l, LDH 632 U/l, CA-125 1,100 U/ml. The peripheral blood smear revealed no

H. M. Turk (✉)
Department of Clinical Oncology, Faculty of Medicine,
Gaziantep University, Gaziantep TR-27310, Turkey
e-mail: turk@gantep.edu.tr

A. Ozet · M. Öztürk · Ş. Komurcu · O. Kuzhan · F. Arpacı ·
B. Ozturk
Department of Clinical Oncology, GATA Faculty of Medicine,
Ankara, Turkey

M. Safali
Department of Pathology, GATA Faculty of Medicine, Ankara,
Turkey

evidence of unusual lymphoid cell. Thoracal computerized tomography (CT) scan showed left pleural effusion and a mass in anterior mediastinum that measured $4 \times 8 \times 12$ cm in diameters and composed of necrotic and hyperdense contrasting areas (Fig. 1). Abdominal CT scan revealed no pathology regarding liver, spleen, and kidneys. There was no retroperitoneal lymph node. Transthoracic needle aspiration of the mass in anterior mediastinum was performed. Pathological examination revealed atypical tumoral lymphoid infiltration with evident sclerosis. The some lymphoid cells had large and eosinophilic nucleoli (Fig. 2). The immunohistochemical profile showed diffuse CD 20 positivity, a few CD 30 positivity in lymphoid cells. CD 15 was negative. These findings were considered nodular sclerosis variety of Hodgkin's disease. But mediastinal sclerosing B cell lymphoma was not fully excluded because of the small sample size. On bone marrow aspiration and biopsy no lymphoma infiltration was found. The patient received six cycles of ABVD (Doxorubicine 25 mg/m², Bleomycine 10 mg/m², Vinblastine 6 mg/m², Dacarbazine 375 mg/m² day 1 and 15) and mediastinal radiotherapy. After completing the chemotherapy, thoracal CT scan showed no mediastinal mass or lymph node, and no pleural effusion. No abnormalities were found as far as lymph nodes, liver, spleen, and kidneys were concerned.

After 10 months, at her follow-up visit she had no complaints, physical examination revealed no pathology. CT scan showed three hypodense masses in the right kidney: One in middle anterior pole measuring 2×16 mm, in the middle lateral pole measuring 35×28 mm, and 20×22 mm (Fig. 3). No lymph nodes were detected in the mediastinum and in the abdomen. Whole blood analysis

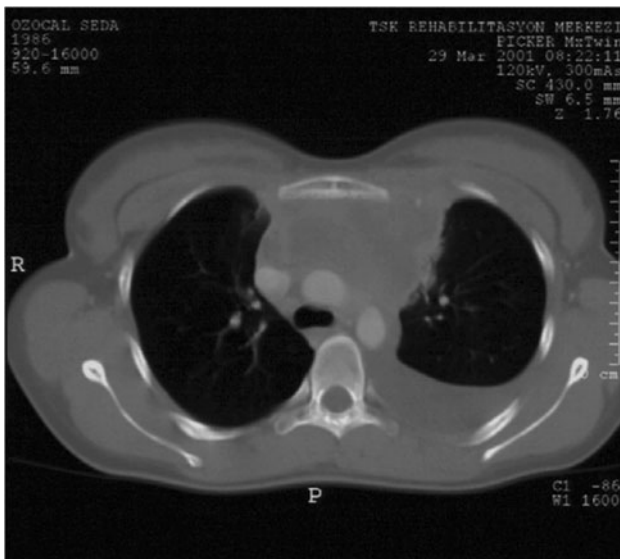

Fig. 1 Thorax CT scan showing a $4 \times 8 \times 12$ cm sized heterogeneous mass in anterior mediastinum and left pleural effusion

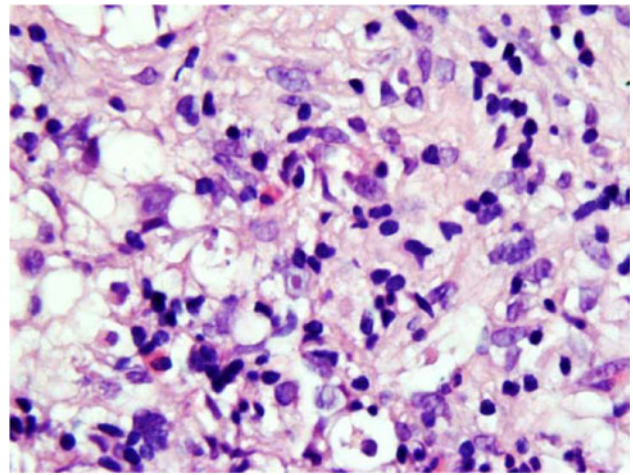


Fig. 2 Biopsy of the mediastinal mass showing tumoral large lymphoid infiltration with evident sclerosis

and routine blood chemistry were normal. There were no hematuria and proteinuria in urine analysis. Ultrasound (USG) guided renal biopsy showed a diffuse infiltration by large tumoral lymphoid cells. The immunohistochemical profile revealed diffuse CD 20 positivity in lymphoid cells. The CD 30 and CD 15 were negative. The diagnosis was diffuse large B cell lymphoma (Fig. 4). Retrospective reevaluation of the archival specimens of the mediastinal mass was also consistent with renal biopsy. Renal masses were assumed to be extranodal relapse of NHL. After four cycles of DHAP (Dexamethasone 40 mg/day on days 1–4, Cytarabine 2,000 mg/m² every 12 h on day 2, Cisplatin 100 mg/m² on day 1) induction chemotherapy she underwent high dose chemotherapy BEAM (BCNU 300 mg/m² on day 1, Etoposide 200 mg/m²/day on days 2–5, ARA-C 100 mg/m²/12 h days 2–5, Melphalan 140 mg/m² on day 6) and autologous peripheral blood stem cell transplantation. After high dose chemotherapy there was no lesion in right kidney of abdomen CT. For 7 years, she is still in remission (Fig. 5).

Discussion

Renal involvement in NHL may be either renal infiltration during the course of advanced disease or primary renal lymphoma. The other form of renal involvement may be seen at relapse of NHL. In the literature reviewed we have found only one case report that a 67-year-old woman with renal mass relapsed 7 years after treatment of NHL [7]. We consider that our patient will be second reported renal relapse of NHL. The frequency of PRL is reported less than 1% of all extranodal lymphomas and association with other extranodal involvement is common [8, 9]. Renal involvement may be diagnosed during routine staging evaluation

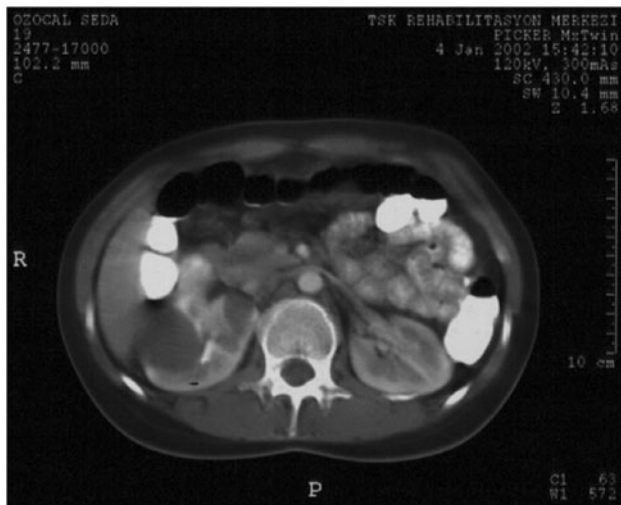


Fig. 3 A CT scans of abdomen showing hypodense masses in the middle anterior and middle lateral pole of right kidney

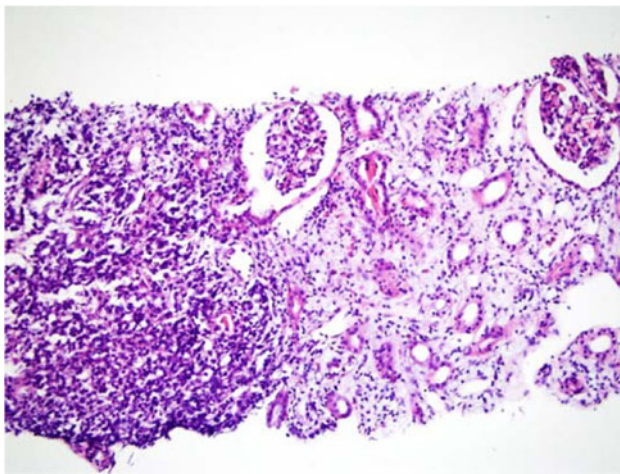


Fig. 4 Biopsy of the renal mass demonstrating the lymphoid infiltration with CD 20 expression

in 3–8% of cases with NHL whereas postmortem examination may reveal renal infiltration in 30–60% of cases [4, 10]. The low incidence of renal involvement in lymphoma may be due to insufficient staging evaluation. At the hand of the recent developments in imaging technology, the incidence of extranodal lymphoma has increased. USG and CT may reveal renal sizes, solitary and multiple renal masses, and hydronephrosis in a safe and non-invasive way. Diagnosing the extent of disease is important not only for staging and planning therapy, but also for managing problems related to the involved organs and for determining the prognosis of the lymphoma. Tumor metabolites are excreted mainly through kidneys. Therefore, renal dysfunction may complicate treatment. Chemotherapeutic agents with minimal renal toxicity must be preferred in these patients.

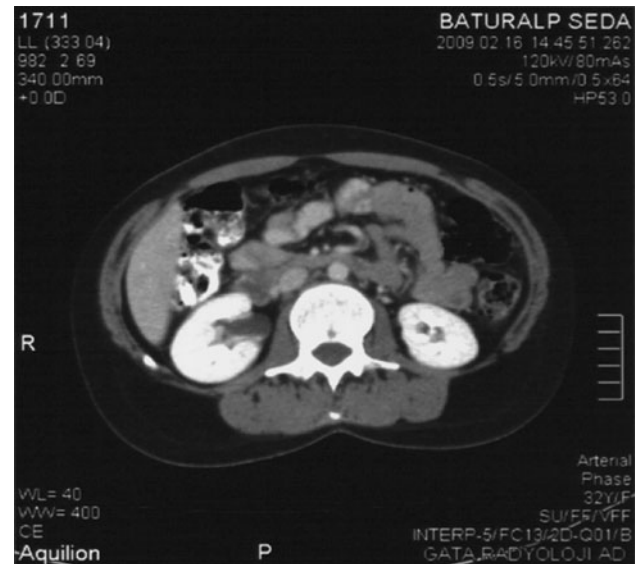


Fig. 5 After 7 years, there was no lesion in right kidney of abdomen CT

The pathogenesis of PRL is not clearly understood. One explanation is that an infection in the kidney recruits lymphoid cells into the renal parenchyma. Another view is that lymphomas arise in the renal capsule that is rich in lymphatics [11]. Another explanation is that possible origin of lymphomas in kidney is a lymphomatous process in the perirenal adipose tissue [12]. Kidneys are unilaterally or bilaterally enlarged in the diffuse type of lymphoma involvement, whereas the nodular type presents as a single lesion or as multiple and mostly cortical lesions (Table 1). In the literature, most adult cases had unilateral renal involvement, while there is more bilateral kidney disease in children [5, 13]. The nodular pattern of renal infiltration is more common than the diffuse one [14].

Acute renal failure due to renal involvement in NHL is rare. In a series of 48 patients with renal involvement, acute renal failure as the presenting feature was observed in only three patients [15]. Impaired renal function has been reported to be a poor prognostic factor for NHL in childhood. A strong negative correlation was found between the degree of renal insufficiency and survival [16]. However, renal involvement presented by acute renal failure had been successfully treated with chemotherapy. Because of patient with renal involvement have mostly in high risk group according to the international prognostic index these patients may be relapsed or progressed after treatment [17]. Early detection and systemic treatment may improve prognosis. Well prognosis may be attributable to more modern therapy for NHL rather than the type of disease involvement. Because of the low incidence of isolated renal involvement, no randomized study could be designed to compare the efficacy of various therapeutic modalities.

Table 1 Clinical characteristics in cases of renal involvement with non-Hodgkin's lymphoma

Authors	Age	Sex	Side	Pattern	Histopathology
Barreto [7]	67	Female	Right	Nodular	Follicular lymphoma
Puerto [17]	58	Male	Bilateral	Diffuse	Large B cell NHL
	46	Male	Bilateral	Diffuse	Immunoblastic large B cell NHL
Harzallah [23]	50	Female	Bilateral	Diffuse	B cell lenfoblastic lymphoma
Olusanya [24]	79	Male	Left	Nodular	Marginal zone B cell lymphoma
Rajappa [25]	58	Male	Right	Nodular	Diffuse large B cell lymphoma

Secondary malignant neoplasms are increasingly being diagnosed in patients with lymphoma such as renal cell carcinoma, non-lymphocytic leukemia, melanoma, bladder carcinoma, and lung carcinoma [18]. At a retrospective analysis of 14,567 cases with NHL, coincidence of renal tumors was 0.43% [19]. Therefore renal masses arising during the course of NHL necessitates renal biopsy to exclude other malignancies. Although the standard management of a renal mass is nephrectomy, NHL should be considered in the differential diagnosis.

Our case presented with a high serum CA-125 level of 1,100 U/ml. Initially, elevated serum concentrations of CA-125 were thought to be specific for ovarian carcinoma while it is now considered that high serum CA-125 levels are found to be associated with benign and malignant disease. CA-125 is produced by cells derived from coelomic epithelium (i.e., pleura, peritoneum, and pericardium) but it is clear that CA-125 is not produced by lymphoma cells. However, approximately 40% of patients with NHL had found elevated serum CA-125 levels at diagnosis [20]. In most series CA-125 levels correlate with some features of NHL, such as stage of disease, bulky tumor, effusions, and response to therapy [20, 21]. The other malignant and nonmalignant serosal fluids such as peritoneal, pleural, and pericardial effusions have been found to be associated with high serum levels of CA-125 [22]. In our case, after six cycles of chemotherapy pleural effusion regressed and serum CA-125 level returned to normal.

In conclusion, renal involvement during advanced lymphoma is quite common but isolated renal relapse in NHL is a rare situation. Renal masses arising in known lymphoma patients should be evaluated histopathologically to exclude other renal tumors. Renal involvement of NHL has a poor prognosis. However, long-term survival may be achieved with high dose chemotherapy and autologous peripheral blood stem cell transplantation.

References

1. Yasunaga Y, Hoshida Y, Hashimoto M, Miki T, Okuyama A, Aozasa K. Malignant lymphoma of the kidney. *J Surg Oncol.* 1997;64(3):207–11. doi:10.1002/(SICI)1096-9098(199703)64:3<207::AID-JSO6>3.0.CO;2-E.
2. Da'as N, Polliack A, Cohen Y, Amir G, Darmon D, Kleinman Y, et al. Kidney involvement and renal manifestations in non-Hodgkin's lymphoma and lymphocytic leukemia: a retrospective study in 700 patients. *Eur J Haematol.* 2001;67(3):158–64. doi:10.1034/j.1600-0609.2001.5790493.x.
3. Ahmad AH, MacLennan GT, Listinsky C. Primary renal lymphoma: a rare neoplasm that may present as a primary renal mass. *J Urol.* 2005;173(1):239.
4. Kandel LB, McCullough DL, Harrison LH, Woodruff RD, Ahl ET, Munitz HA. Primary renal lymphoma. Does it exist? *Cancer.* 1987;60(3):386–91.
5. Arranz Arijia JA, Carrion JR, Garcia FR, Tejedor A, Pérez-Manga G, Tardio J, et al. Primary renal lymphoma: report of 3 cases and review of the literature. *Am J Nephrol.* 1994;14(2):148–53. doi:10.1159/000168705.
6. Ferry JA, Harris NL, Papanicolaou N, Young RH. Lymphoma of the kidney. A report of 11 cases. *Am J Surg Pathol.* 1995;19(2):134–44. doi:10.1097/00000478-199502000-00002.
7. Barreto F, Dall'Oglio MF, Srougi M. Renal lymphoma. Atypical presentation of a renal tumor. *Int Braz J Urol.* 2006;32(2):190–2. doi:10.1590/S1677-55382006000200010.
8. Aozasa K, Tsujimoto M, Sakurai M, Honda M, Yamashita K, Hanada M, et al. Non-Hodgkin's lymphomas in Osaka, Japan. *Eur J Cancer Clin Oncol.* 1985;21(4):487–92. doi:10.1016/0277-5379(85)90042-2.
9. Richards MA, Mootoosamy I, Reznick RH, Webb JA, Lister TA. Renal involvement in patients with non-Hodgkin's lymphoma: clinical and pathological features in 23 cases. *Hematol Oncol.* 1990;8(2):105–10. doi:10.1002/hon.2900080206.
10. Xiao JC, Walz-Mattmuller R, Ruck P, Horny HP, Kaiserling E. Renal involvement in myeloproliferative and lymphoproliferative disorders. A study of autopsy cases. *Gen Diagn Pathol.* 1997;142(3–4):147–53.
11. Salem Y, Pagliaro LC, Manyak MJ. Primary small noncleaved cell lymphoma of kidney. *Urology.* 1993;42(3):331–5. doi:10.1016/0090-4295(93)90627-M.
12. Betta PG, Bottero G, Cosimi MF, Musante F. Primary renal lymphoma. *Eur Urol.* 1986;12(5):352–4.
13. Kutluk MT, Büyükpamukçu M, Göğüş S, Sarialioğlu F, Akhan O, Beşbaş N. Renal lymphoma. An unusual presentation in a child. *Turk J Pediatr.* 1989;31(1):71–7.
14. Brouland JP, Meeus F, Rossert J, Hernigou A, Gentric D, Jacquot C, et al. Primary bilateral B-cell renal lymphoma: a case report and review of the literature. *Am J Kidney Dis.* 1994;24(4):586–9.
15. Morel P, Dupriez B, Herbrecht R, Bastion Y, Tilly H, Delannoy A, et al. Aggressive lymphomas with renal involvement: a study of 48 patients treated with the LNH-84 and LNH-87. *Regimens Groupe d'Etude des Lymphomes de l'Adulte.* *Br J Cancer.* 1994;70(1):154–9.
16. Buyukpamukcu M, Varan A, Aydin B, Kale G, Akata D, Yalcin B, et al. Renal involvement of non-Hodgkin's lymphoma and its

- prognostic effect in childhood. *Nephron Clin Pract.* 2005;100(3):c86–91. doi:[10.1159/000085053](https://doi.org/10.1159/000085053).
17. Puerto IM, Garcia MB, Hernandez EA, Martinez IB. Primary renal non-Hodgkin's lymphoma presenting with acute renal failure: report of two cases. *Heama.* 2004;7(3):378–81.
 18. Tihan T, Filippa DA. Coexistence of renal cell carcinoma and malignant lymphoma. A causal relationship or coincidental occurrence. *Cancer.* 1996;77(11):2325–31.
 19. Ohsawa M, Hashimoto M, Yasunaga Y, Shingu N, Aozasa K. Characteristics of non-Hodgkin's lymphoma complicated by renal cell malignancies. *Oncology.* 1998;55(5):482–6. doi:[10.1159/000011899](https://doi.org/10.1159/000011899).
 20. Wiernik PH. Serum CA 125 and PSA concentrations in patients with lymphoma. *Clin Adv Hematol Oncol.* 2008;6(7):527–31.
 21. Bairey O, Blickstein D, Stark P, Prokocimer M, Nativ HM, Kirgner I, et al. Serum Ca 125 as a prognostic factor in non-Hodgkin's lymphoma. *Leuk Lymphoma.* 2003;44(10):1733–8. doi:[10.1080/1042819031000104079](https://doi.org/10.1080/1042819031000104079).
 22. Turk HM, Pekdemir H, Buyukberber S, Sevinc A, Camci C, Kocabaş R, et al. Serum CA 125 levels in patients with chronic heart failure and accompanying pleural fluid. *Tumour Biol.* 2003;24(4):172–5. doi:[10.1159/000074425](https://doi.org/10.1159/000074425).
 23. Harzallah K, Laadidi J, Chatti K, Hlel I, Bougrine F, Bouziani A. Acute renal failure due to lymphomatous infiltration: an unusual presentation. *Saudi J Kidney Dis Transpl.* 2006;17(3):395–8.
 24. Olusanya AA, Huff G, Adeleye O, Faulkner M, Burnette R, Thompson H, et al. Primary renal non-Hodgkin's lymphoma presenting with acute renal failure. *J Natl Med Assoc.* 2003; 95(3):220–4.
 25. Rajappa S, Digumarti R, Immaneni SR, Parage M. Primary renal lymphoma presenting with paraneoplastic limbic encephalitis. *J Clin Oncol.* 2007;25(24):3783–5.