

Technical note

A new anatomical landmark to simplify temporomandibular joint arthrocentesis

Alper Alkan, Osman A. Etöz*

Erciyes University Faculty of Dentistry, Department of Oral and Maxillofacial Surgery, Kayseri, Turkey

Accepted 29 June 2009

Available online 28 July 2009

Keywords: Temporomandibular joint; Arthrocentesis

Arthrocentesis of the temporomandibular joint (TMJ) was first described by Nitzan et al.¹ and is an accepted treatment for various disorders of the TMJ. Their technique includes insertion of two needles along the canthal-tragal line, the first of which is placed into the upper joint compartment of the TMJ, and the second anterior to the first to allow effective lavage of the joint (Fig. 1). However, in some cases it is difficult to insert the second needle, which means that lavage fails, the operation takes longer, the patient is uncomfortable, and there may be increased postoperative morbidity and possible damage to the facial nerve.² For this reason single needle arthrocentesis has been proposed, in which inflow and outflow go through the same cannula.² The joint is lavaged with a single needle used for injection and ejection resulting 40 ml of irrigation. However, with a single needle the amount of fluid may be inadequate and the pressure too low.

Previously, we have used a single cannula with two ports and two lumens that allow irrigation and lavage of the joint with the same device and permit sufficient irrigation under the desired pressure.³ Rehman and Hall⁴ used a similar device called a Shepard cannula that holds two needles together. Nevertheless the device that keeps two needles together seems to be relatively thick, which has the potential to damage the nerve. Repetitive use of the device may cause the tips of the needles to blunt, and increase the risk of infection.

We propose a new technique, by which the patients are asked to open and close the mouth several times so that the

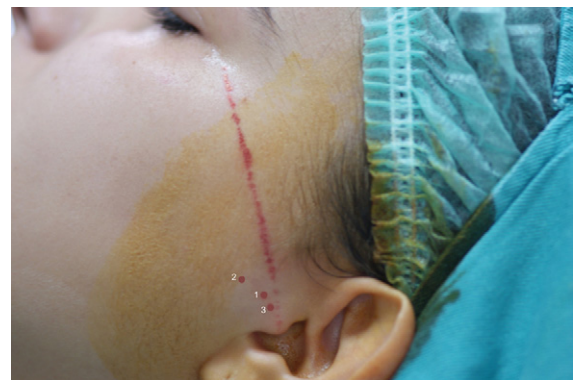

Fig. 1. Placement of the first (1) and second needles (2) in the conventional approach for arthrocentesis of the temporomandibular joint. In the technique that we have described, the second needle (3) is 3 mm posterior to the first needle (1), which was inserted 10 mm anterior and 2 mm inferior along the canthal-tragal line.

condylar head of the mandible can be palpated. They are then instructed to keep the mouth open and a 21 gauge needle with a 10 ml syringe is inserted 10 mm anterior and 2 mm inferior along the canthal-tragal line and oriented 30° posterior and inferior to the sagittal plane until bony contact has been made at the medial wall of the glenoid fossa. The second needle is inserted 7 mm anterior and 2 mm inferior along the canthal-tragal line and should be adjusted parallel and almost 3 mm posterior to the first needle until bony contact is made (Figs. 1 and 2).

We used this landmark when we were faced with failed outflow through an anteriorly placed second needle, and have thoroughly irrigated numerous joints with complete success when the second needle is inserted posterior to the first one

* Corresponding author. Address: Erciyes Universitesi Dis Hekimligi Fakultesi Cerrahi Bolumu, 38039 Melikgazi, Kayseri, Turkey.
Fax: +90 352 438 06 57.

E-mail address: osmanetoz@yahoo.com (O.A. Etöz).

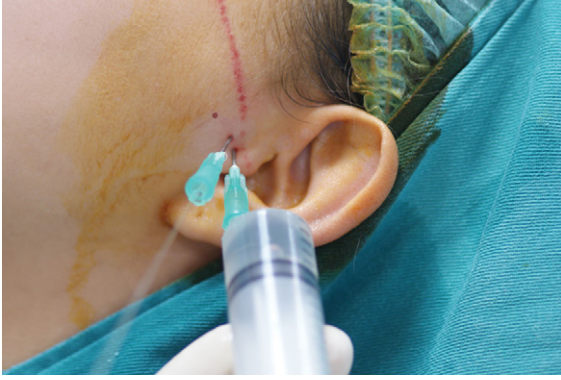

Fig. 2. Effective washout of the joint with the described technique.

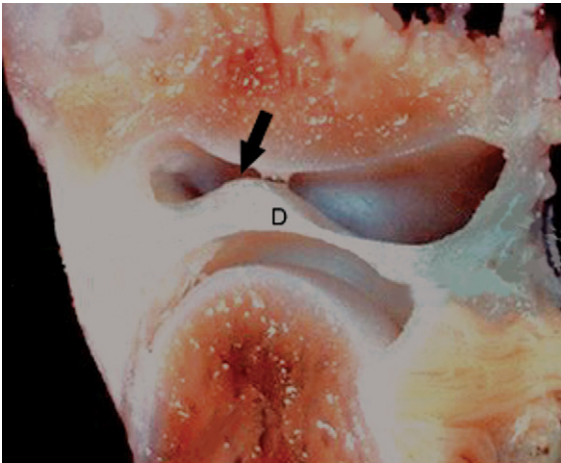


Fig. 3. The second needle anterior to the first one would be in the narrower part of the posterior upper joint compartment (black arrow) and closer to the articular disk (D). (Reprinted from: Nanci A. Ten Cate's oral histology: development, structure and function. Chicago: Mosby, 2003; reproduced by permission of the publisher.)

(Fig. 2). Laskin mentioned that insertion of the second needle anterior to the first one is usually difficult, and he has inserted the anterior needle in the posterior recess of the upper joint compartment by placing it 3–4 mm anterior to the first one.⁵ However, if the second needle is anterior to the first one it is inserted into a narrower region of the upper joint compartment (Fig. 3), and this may cause damage to the disc and unexpected failure of outflow. Outflow is easier to achieve when the second needle is inserted posterior to the first one in the wider part of the upper joint compartment.

The use of this landmark as the default technique may be reasonable, as repeated insertions of a needle are uncomfortable both for physicians and patients and adversely affect the success of the treatment.

References

1. Nitzan DW, Dolwick MF, Martinez GA. Temporomandibular joint arthrocentesis: a simplified treatment for severe, limited mouth opening. *J Oral Maxillofac Surg* 1991;**49**:1163–70.
2. Guarda-Nardini L, Manfredini D, Ferronato G. Arthrocentesis of the temporomandibular joint: a proposal for a single-needle technique. *Oral Surg Oral Med Oral Pathol Oral Radiol Endod* 2008;**106**:483–6.
3. Alkan A, Bas B. The use of double-needle canula method for temporomandibular joint arthrocentesis: clinical report. *Eur J Dent* 2007;**1**:179–82.
4. Rehman KU, Hall T. Single needle arthrocentesis. *Br J Oral Maxillofac Surg* 2009;**47**:403–4.
5. Laskin DM. Needle placement for arthrocentesis. *J Oral Maxillofac Surg* 1998;**56**:907.